

## Letter to the Editor

## Primary Angioplasty with Manual Thrombectomy Alone as a Therapeutic Strategy in a Patient with Acute Myocardial Infarction and Severe Anemia

GIUSEPPE TALANAS, GIUSEPPINA FIORE, PIERFRANCO TERROSU

*Division of Cardiology-Catheterization Laboratory, SS. Annunziata Hospital of Sassari, Sassari, Italy*

**Key words: Primary percutaneous coronary intervention, manual thrombus aspiration, STEMI, anemia.**

*Manuscript received:*  
July 12, 2014;  
*Accepted:*  
March 4, 2015.

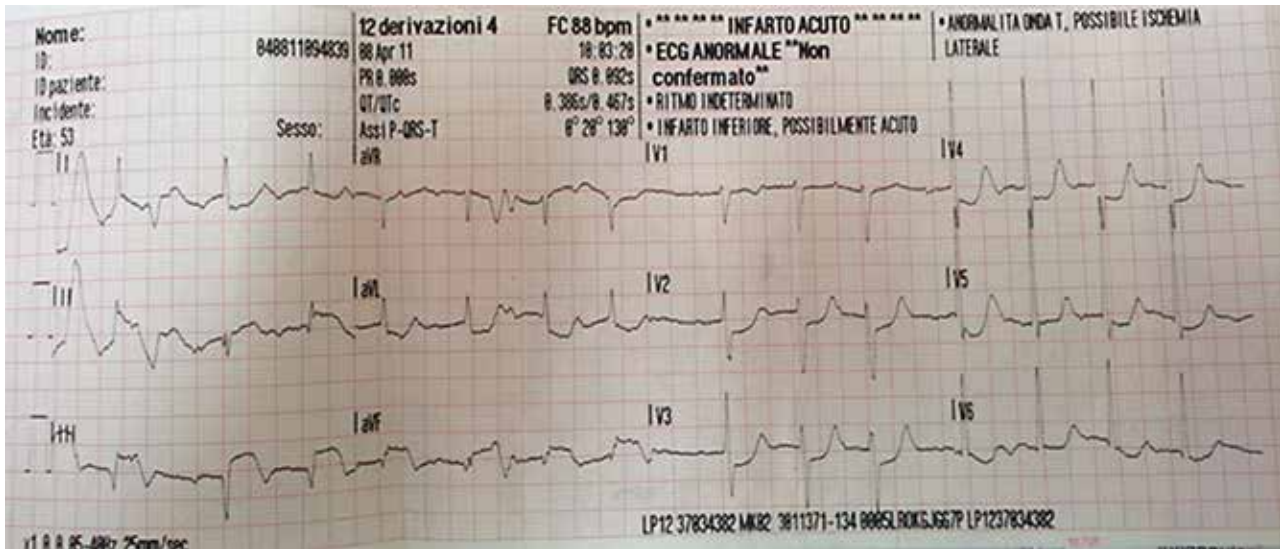
*Address:*  
Giuseppe Talanas

*Division of Cardiology-  
Catheterization  
Laboratory  
Santissima Annunziata  
Hospital of Sassari  
Via De Nicola 14  
07100 Sassari, Italy  
[giustal@yahoo.it](mailto:giustal@yahoo.it)*

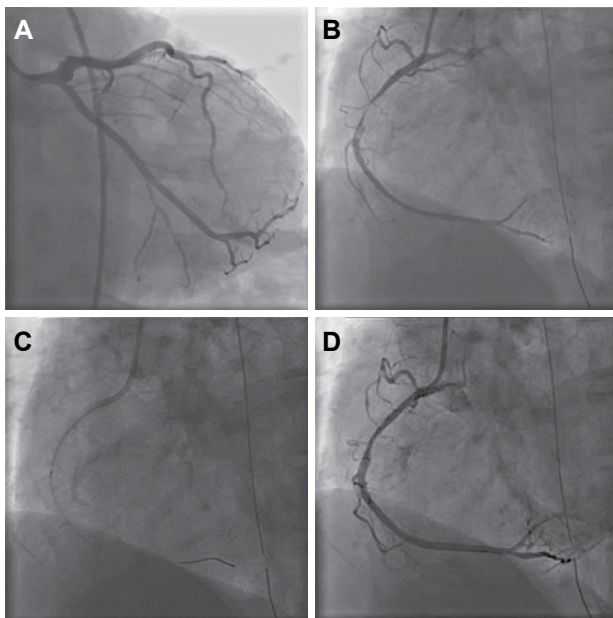
A 53-year-old man was urgently admitted to our catheterization laboratory because of an ST-elevation myocardial infarction (STEMI) complicated by out-of-hospital cardiac arrest due to ventricular fibrillation. The ECG, recorded after defibrillation, showed a sinus rhythm of 88 beats per minute and a definite Q wave, with ST-segment elevation in the inferior leads (Figure 1). In the Emergency Department an arterial blood gas analysis showed severe anemia (hemoglobin 5.4 g/dL). Coronary angiography revealed no significant lesions in the left coronary artery, while the right coronary artery (RCA) showed an acute thrombotic occlusion in the mid tract (Figure 2A and 2B). After advancement of a workhorse guidewire, manual thrombectomy (MT) (Pronto LP, Vascular Solutions Inc., USA) was performed (Figure 2C). After MT, TIMI 3 flow was restored, but a residual stenosis in the mid tract, of at least moderate degree, was observed in the next angiographic examination (Figure 2D). A huge fresh-soft thrombotic mass was retrieved (Figure 3A). In the meantime, the patient became asymptomatic and dramatic ST-segment resolution was obtained after MT. Since

anemia of unknown origin was present, the patient was asymptomatic and the ECG showed clear signs of reperfusion (Figure 3B), we decided to avoid stent implantation until the anemia could be characterized. The cause of anemia was a chronic loss of hemoglobin from an erythematous gastritis. Three weeks later, a new angiographic check showed only a mild plaque in the mid RCA, clearly improved in comparison with the previous angiography (Figure 4). The patient was left on medical therapy and he is doing well at 2-year follow up.

MT is widely accepted as a first-step strategy in the setting of primary PCI.<sup>1</sup> The standard PCI procedure in ST-elevation myocardial infarction (STEMI) includes MT followed, if possible, by direct coronary stenting. This practice permits the restoration of both epicardial and microcirculatory flow and an increase in luminal area by stenting at the culprit location, which seals the ulcerated plaque. In fact, in the pivotal TAPAS trial, where thrombus aspiration was better than conventional angioplasty in terms of clinical outcome, MT was followed by stent implantation in more than 90% of patients.<sup>2</sup> Moreover, the no-reflow phenomenon in the setting of primary PCI is associat-



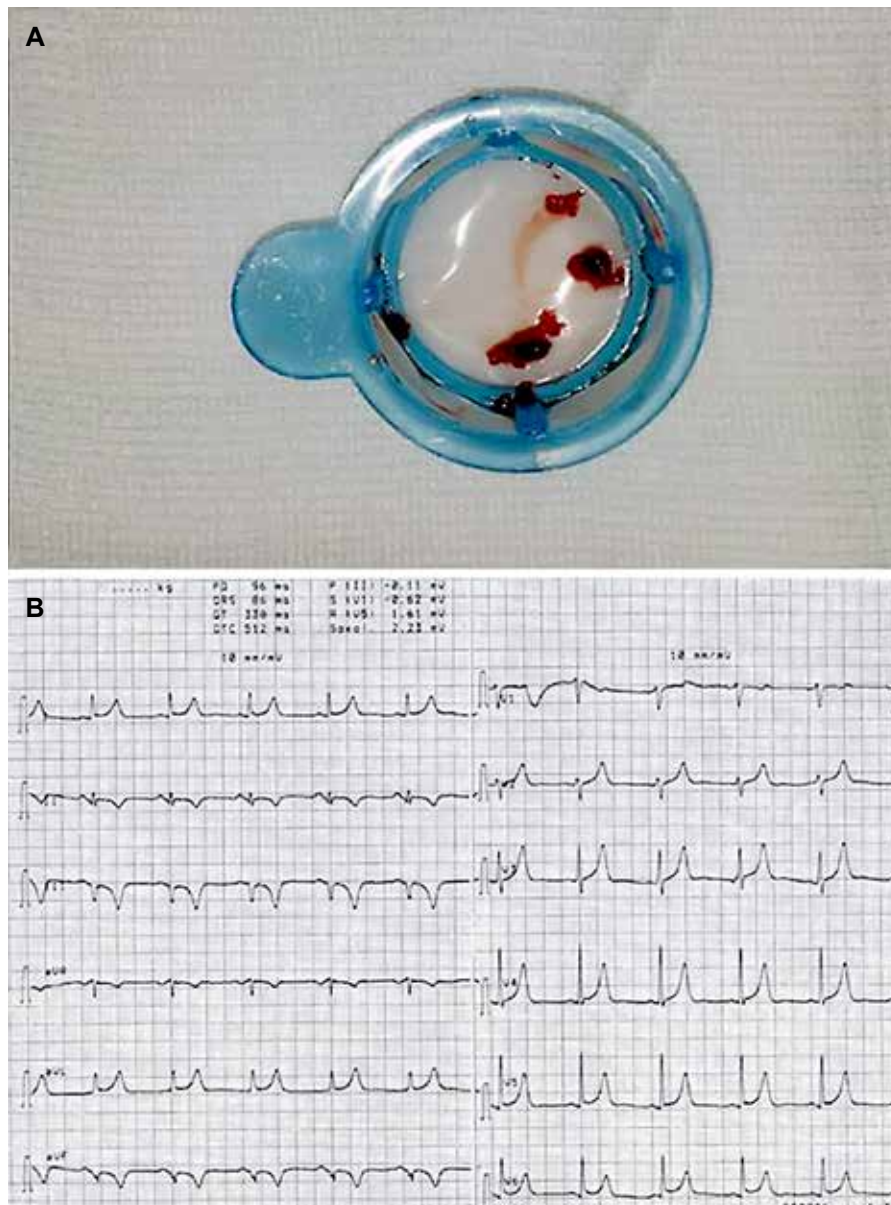
**Figure 1.** The ECG recorded after defibrillation by the Emergency Medical System, although technically imperfect in terms of quality, shows ST-segment elevation in the inferior leads and reciprocal ST depression in DI, aVL, and V2-V4.



**Figure 2.** A. The antero-posterior caudal view of the left coronary artery shows the absence of angiographically significant coronary lesions. B. The left anterior oblique view of the right coronary artery shows a subtotal occlusion in the mid tract, with a huge superimposed coronary thrombus. C. After advancement of a guidewire through the occlusion, manual thrombus aspiration was performed. D. The left anterior oblique view of the right coronary artery shows a residual stenosis in the mid tract.

ed with a 3-year increase in hospital admissions for heart failure.<sup>3</sup> However, the TAPAS trial procedur-

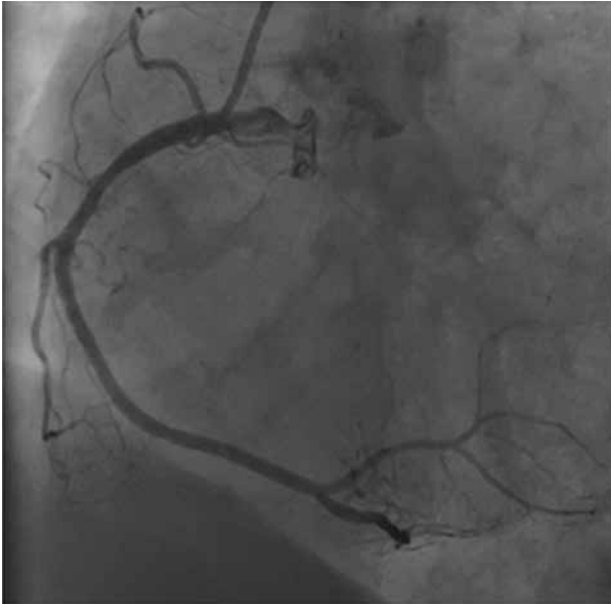al approach has been questioned in the TASTE trial, where MT before PCI did not reduce 30-day mortality compared to PCI alone.<sup>4</sup> Nevertheless, the standard PCI technique – thrombus aspiration-(balloon dilatation)-stent implantation – may be questionable when MT has already achieved optimal reperfusion, while further balloon dilatation or stenting may be associated with additional risks (e.g. distal embolization and no-reflow). Stent implantation after successful MT may even be detrimental when associated clinical conditions absolutely contraindicate antiplatelet therapy (e.g. severe anemia of unknown origin, bleedings), or when non-atherosclerotic causes of myocardial infarction are present. However, there is a shortage of data concerning primary PCI by means of MT alone.<sup>5-8</sup> Kramer reported on a group of 16 patients with STEMI demonstrating that MT alone is feasible and safe in the short term.<sup>5</sup> Escaned described 28 patients with STEMI treated with lone thrombus aspiration, underlining that lone thrombus aspiration is safe in either the short or the long term.<sup>7</sup> Jamil showed that, in a young population with STEMI, lone aspiration thrombectomy is associated with favorable short- and long-term clinical outcomes.<sup>8</sup> In the present case, the patient had a STEMI complicated by cardiac arrest due to ventricular fibrillation and a concomitant severe anemia. The balance between thrombotic and hemorrhagic risk in



**Figure 3.** A. A huge amount of fresh-soft thrombotic material was retrieved after manual thrombectomy. B. The ECG recorded after the procedure shows sinus rhythm at 65 beats per minute, Q waves in DIII and aVF, and negative T-wave inversion in the same leads.

this urgent setting is challenging. After the finding of an acute thrombotic occlusion in the mid RCA, MT was performed and reperfusion of the infarct-related artery was achieved. Since the patient was stabilized and severe anemia of unknown origin contraindicated any antiplatelet therapy, we avoided stent implantation despite the presence of a residual stenosis, of at least moderate degree, in the mid RCA. In contrast Li and colleagues reported that MT alone is not suitable for treating coronary occlusions caused by intimal stripping due to blunt trauma.<sup>9</sup> In our patient, we did not opt for balloon angioplasty alone to

increase the luminal area, because the lone MT restored adequate coronary flow and myocardial perfusion. Furthermore, balloon angioplasty alone is not free of risk, as historical data report an abrupt closure in roughly 5% of patients and an elevated incidence of post-angioplasty dissections.<sup>10,11</sup> Moreover, if, hypothetically, balloon angioplasty had led to extensive vessel dissection in this patient with severe anemia, the subsequent bail-out stenting might have been extremely dangerous, since the unknown-cause anemia portended a very high probability of premature discontinuation of double antiplatelet therapy



**Figure 4.** At the angiographic check 3 weeks after the index event, the left anterior oblique view of the right coronary artery shows a mild plaque in its mid tract, which is significantly better in comparison with the angiogram performed immediately after manual thrombus aspiration.

and, consequently, of stent thrombosis. In primary PCI, this approach with MT alone may be sufficient in selected cases. In this setting the use of optical coherence tomography (OCT) is attractive, because it allows a highly detailed visualization of the coronary lumen. After MT, OCT might be used to decide whether to implant a stent or not, or to choose the stent size, reducing the risk of late-acquired stent malapposition due to thrombus resolution. Cervinka and colleagues showed that, on the basis of OCT information, 20% of STEMI patients were treated only with thrombus aspiration, even in the presence of angiographically detected high-grade stenosis; in patients treated with MT alone, the angiogram and OCT repeated 1 week and 9 months after STEMI showed a normal vessel without significant residual stenosis, suggesting that residual stenosis may be overestimated in the acute phase of STEMI.<sup>12</sup> In fact, in our patient, a subsequent angiographic check of the infarct-related artery revealed only a mild plaque in the mid RCA, a significant improvement in comparison with the result obtained immediately after MT.

In summary, our report shows that primary PCI

with lone MT may be performed safely, avoiding stent implantation, especially when an absolute contraindication for antiplatelet therapy exists. This case highlights the concept that, especially in young patients, intracoronary thrombus may more frequently play a major role in acute vessel closure, compared with the atherosclerotic burden.

### Acknowledgements

We would like to thank all the staff of the Cath Lab for their daily and invaluable work.

### References

1. Steg PG, James SK, Atar D, et al; Task Force on the management of ST-segment elevation acute myocardial infarction of the European Society of Cardiology. ESC Guidelines for the management of acute myocardial infarction in patients presenting with ST-segment elevation. *Eur Heart J.* 2012; 33: 2569-2619.
2. Svilaas T, Vlaar PJ, van der Horst IC, et al. Thrombus aspiration during primary percutaneous coronary intervention. *N Engl J Med.* 2008; 358: 557-567.
3. Zencirci AE, Zencirci E, Değirmencioglu A, et al. Predictive value of the no-reflow phenomenon and epicardial adipose tissue for clinical outcomes after primary percutaneous coronary intervention. *Hellenic J Cardiol.* 2015; 56: 311-319.
4. Fröbert O, Lagerqvist B, Olivecrona GK, et al. Thrombus aspiration during ST-segment elevation myocardial infarction. *N Engl J Med.* 2013; 369: 1587-1597.
5. Talarico GP, Burzotta F, Trani C, et al. Thrombus aspiration without additional ballooning or stenting to treat selected patients with ST-elevation myocardial infarction. *J Invasiv Cardiol.* 2010; 22: 489-492.
6. Kramer MC, Verouden NC, Li X, et al. Thrombus aspiration alone during primary percutaneous coronary intervention as definitive treatment in acute ST-elevation myocardial infarction. *Catheter Cardiovasc Interv.* 2012; 79: 860-867.
7. Escaned J, Echavarría-Pinto M, Gorgadze T, et al. Safety of lone thrombus aspiration without concomitant coronary stenting in selected patients with acute myocardial infarction. *EuroIntervention.* 2013; 8: 1149-1156.
8. Jamil G, Jamil M, Abbas A, Sainudheen S, Mokahal S, Qureshi A. "Lone aspiration thrombectomy" without stenting in young patients with ST elevation myocardial infarction. *Am J Cardiovasc Dis.* 2013; 3: 71-78.
9. Li X, Lei Y, Zheng Q. Myocardial infarction caused by coronary artery dissection due to blunt injury: is thromboaspiration an appropriate treatment? *Hellenic J Cardiol.* 2014; 55: 61-64.
10. Black AJ, Namay DL, Niederman AL, et al. Tear or dissec-

- tion after coronary angioplasty. Morphologic correlates of an ischemic complication. *Circulation*. 1989; 79: 1035-1042.
11. Ferguson JJ, Barasch E, Wilson JM, et al. The relation of clinical outcome to dissection and thrombus formation during coronary angioplasty. Heparin Registry Investigators. *J Invasive Cardiol*. 1995; 7: 2-10.
  12. Cervinka P, Spaček R, Bystroň M, et al. Optical coherence tomography-guided primary percutaneous coronary intervention in ST-segment elevation myocardial infarction patients: a pilot study. *Can J Cardiol*. 2014; 30: 420-427.