

Letter to the Editor

Ruptured Sinus of Valsalva: Not Always an Aneurysm

ANDREW CHATZIS¹, MELETIOS KANAKIS¹, ALEXANDER TSOUTSINOS², FOTIOS MITROPOULOS¹

¹Department of Paediatric and Congenital Cardiac Surgery, ²Department of Paediatric Cardiology, Onassis Cardiac Surgery Centre, Athens, Greece

Key words:
Congenital heart disease, septal defects, aortic, sinus of Valsalva, surgery, complications.

Manuscript received:
May 2, 2013;
Accepted:
February 24, 2014.

Address:
Andrew Chatzis

Department of Paediatric
and Congenital Cardiac
Surgery
Onassis Cardiac Surgery
Centre
356 Sygrou Ave.
17674 Kallithea
Athens, Greece
achatzis@ath.forthnet.gr

A 22-year-old asymptomatic man, with a history of ventricular septal defect repair at the age of two, was diagnosed with a continuous left parasternal cardiac murmur during a routine physical examination. Subsequent echocardiography revealed a ruptured right sinus of Valsalva into the right ventricle through a residual ventricular septal defect (Figure 1). In addition, good right ventricular function was recorded, with right ventricular internal dimension in diastole (RVIDd) measuring 27 mm.

At operation, polypropylene suture material was found on the rim of the aortic rupture, which in the absence of a true “wind-sock” type aneurysm, suggests inadvertent trauma to the aortic valve during the original defect closure. Both lesions, the residual septal defect and the rupture, were successfully repaired via aortotomy (Figure 2).

Aortoventricular fistulae are rare and are mostly due to ruptured aneurysms of a sinus of Valsalva, commonly congenital in origin, with an ominous natural history. Operative results and long-term survival after surgical treatment, however, are excellent (Figure 3).^{1,2} To our knowledge, this is the first report of aortoventricular communication complicating ventricular septal defect repair.

References

1. Bonfils-Roberts EA, DuShane JW, McGoon DC, Danielson GK. Aortic sinus fistula-surgical considerations and results of operation. *Ann Thorac Surg.* 1971; 12: 492-502.
2. van Son JA, Danielson GK, Schaff HV, Orszulak TA, Edwards WD, Seward JB. Long-term outcome of surgical repair of ruptured sinus of Valsalva aneurysm. *Circulation.* 1994; 90(5 Pt 2): II20-9.

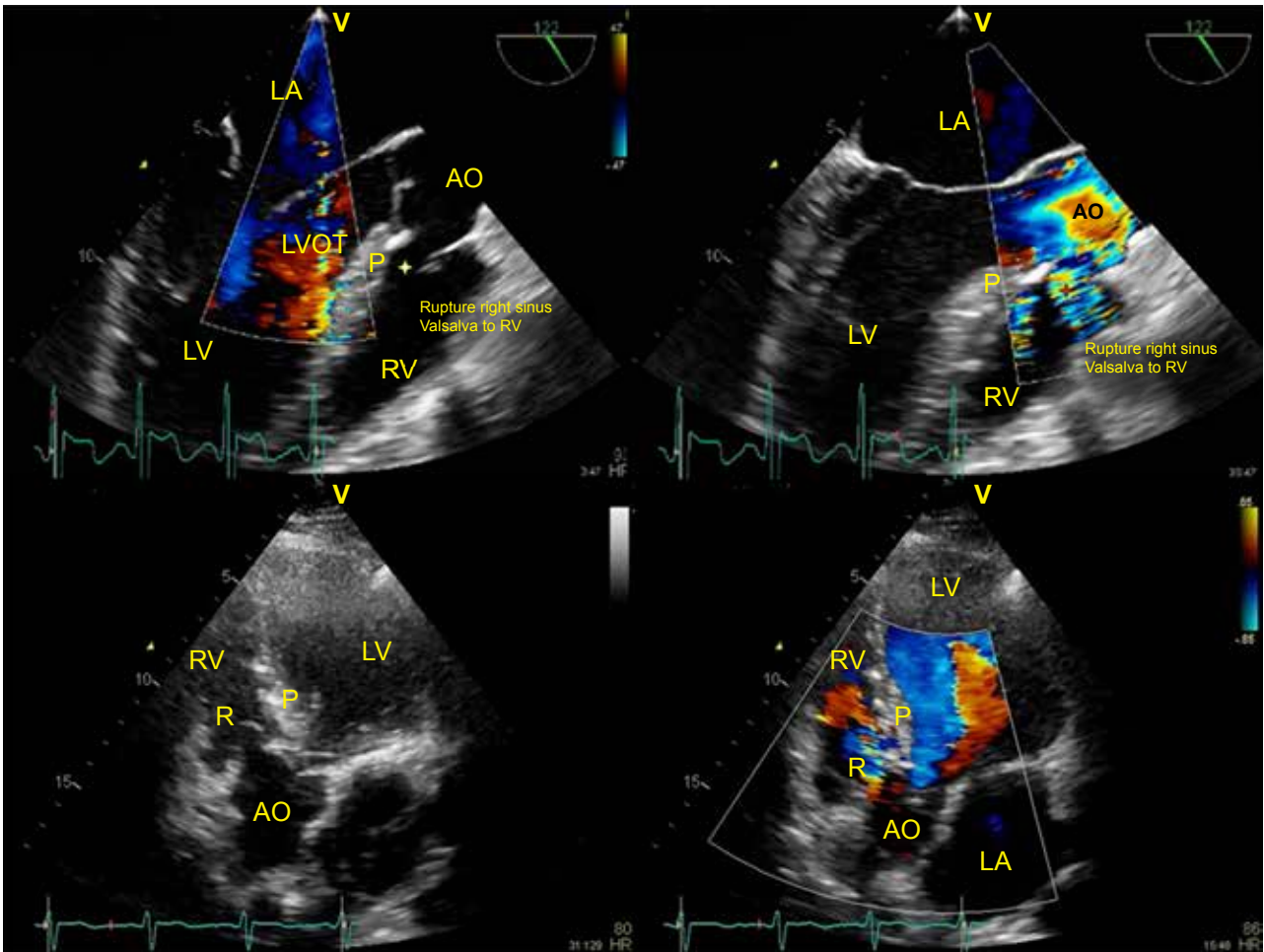


Figure 1. Echocardiographic images depicting a right coronary sinus to right ventricle communication through a residual ventricular septal defect. Ao – aorta; LA – left atrium; LV – left ventricle; LVOT – left ventricular outflow tract; RV – right ventricle; P – ventricular septal defect patch; R – rupture.

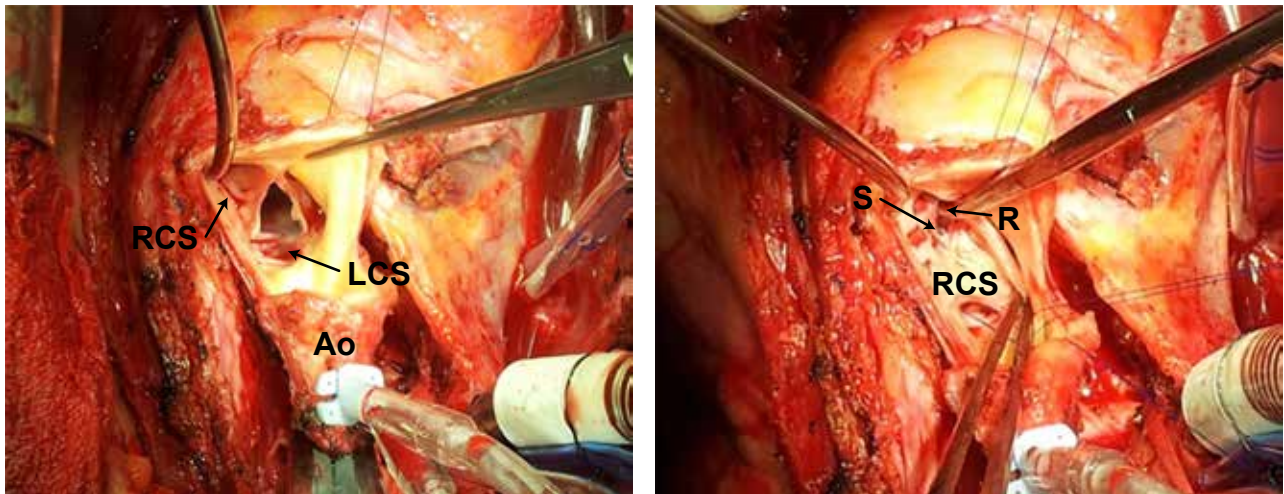


Figure 2. Operative view: A. Absence of true right coronary sinus aneurysm. B. Polypropylene stitch at the base of the right coronary sinus cusp. Ao – aorta; LCS – left coronary sinus; RCS – right coronary sinus; S – suture; R – rupture.

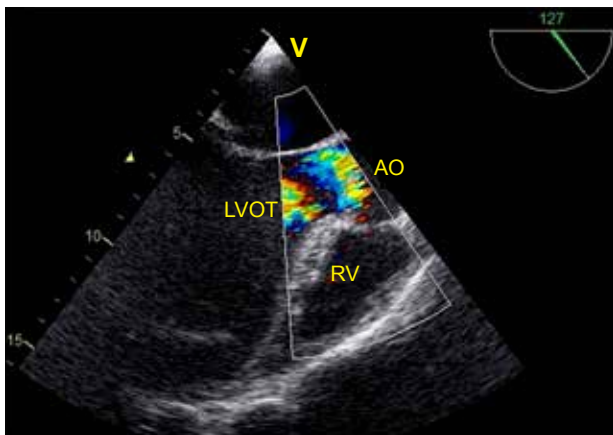


Figure 3. Postoperative echocardiography image. Ao – aorta; LVOT – left ventricular outflow tract; RV – right ventricle.