

## Case Report

# Myocardial Infarction Caused by Coronary Artery Dissection due to Blunt Injury: Is Thromboaspiration an Appropriate Treatment?

XUE LI<sup>1</sup>, YONGHONG LEI<sup>2</sup>, QIANGSUN ZHENG<sup>1</sup>

<sup>1</sup>Tangdu Hospital Cardiology Department, Xi'an, Shaanxi, <sup>2</sup>304 Hospital Cardiology Department, Beijing, China

**Key words:**

**Myocardial infarction, thromboaspiration, no-flow, coronary artery spasm.**

The present study reports a case of myocardial infarction (MI) resulting from blunt trauma-induced coronary artery injury. After falling from a 5-meter-tall building, a man suffered multiple fractures of the arms and legs. Percutaneous coronary intervention (PCI) was performed 48 hours after successful repair of the limb fractures. Coronary angiography revealed an occlusion of the left anterior descending artery, without significant lesions of other arteries. Intravascular ultrasound showed obvious signs of coronary artery dissection at the calcium point of the intimal layer, intramural hematoma, and intimal stripping. The intimal lesion itself may have been responsible for the MI, by causing mechanical obstruction. Use of a thrombectomy device to remove the thrombus caused coronary artery spasm and no blood flow. Sodium nitroprusside and tirofiban were injected into the coronary artery three times, and the coronary blood flow was restored. The patient was again returned to the care unit. One week later, balloon angioplasty without thromboaspiration was performed, and a rapamycin-eluting stent was placed at the point of the intimal lesion. The patient was discharged uneventfully 7 days after stent placement. The patient was asymptomatic and doing well at the outpatient follow-up visit 1 year after PCI.

*Manuscript received:*

May 16, 2013;

*Accepted:*

August 2, 2013.

*Address:*

Qiangsun Zheng

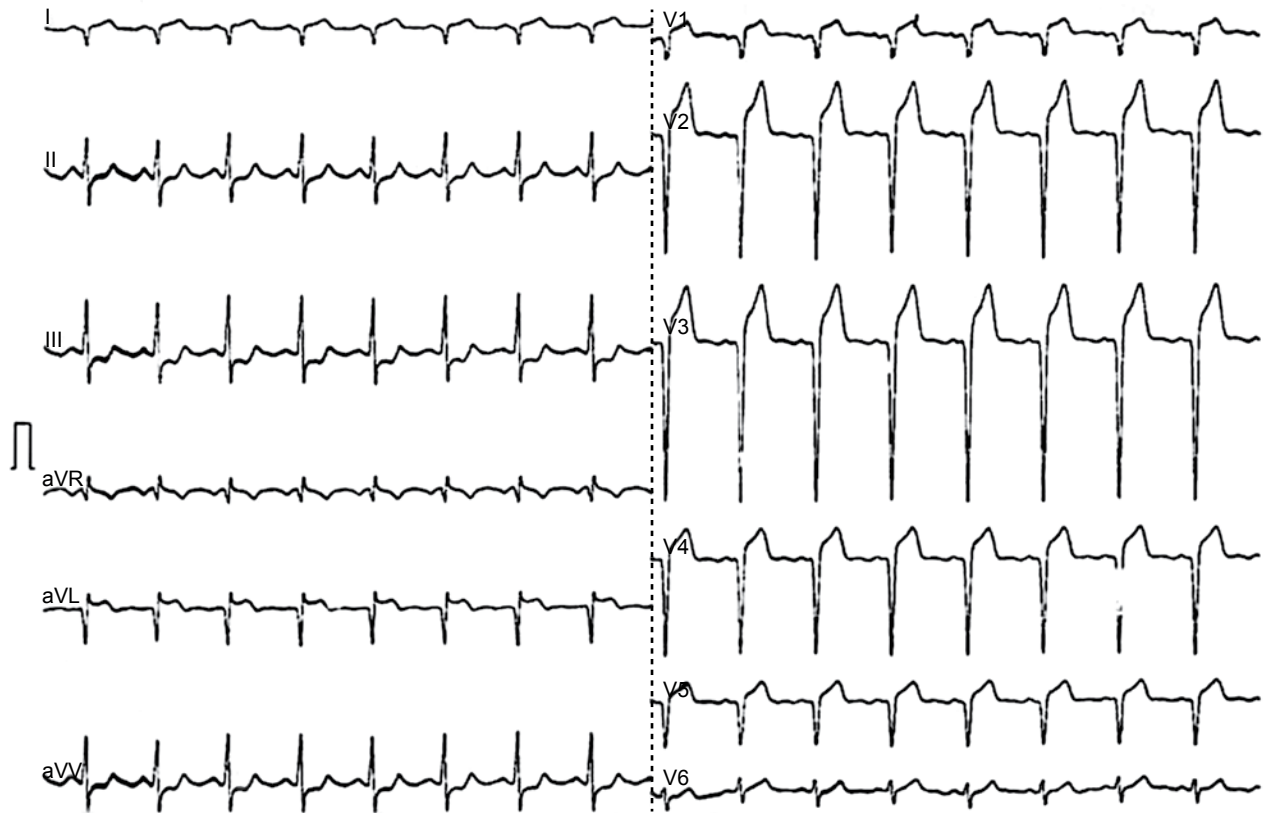
1# Xin Shi Road  
Medicine Building Room  
415 Xi'an, Shaanxi  
710032, China  
e-mail: [lxhlms@126.com](mailto:lxhlms@126.com)

**T**rauma is a rare but important cause of cardiac rupture, ventricular septal defect, and valvular or myocardial damage.<sup>1</sup> Myocardial infarction (MI) may occur as a consequence of damage to the coronary artery, leading to lesions ranging in severity from coronary artery rupture and fistula formation to atheromatous plaque fissure and intimal tears.<sup>2</sup> These injuries are much less common, accounting for 10 out of 548 patients in one series of chest trauma patients.<sup>3</sup> In this paper, we report a case of anterior MI occurring after damage to the intimal layer of the left anterior descending coronary artery after blunt injury.

## Case presentation

A 24-year-old man without a medical his-

tory was admitted to our hospital with multiple fractures of the arms and legs caused by falling from a 5-meter-high building. Before being admitted to hospital, the patient was reportedly a healthy man, although his family history was not clear. When the patient was transferred to the intensive care unit, he developed severe chest pain. Physical examination of the chest did not reveal any abnormalities. His blood pressure was 110/70 mmHg and pulse rate was 80 beats per minute. Electrocardiography (ECG) revealed Q waves in leads V<sub>1</sub>-V<sub>6</sub> (Figure 1). The troponin I level was 10.5 ng/mL, aspartate aminotransferase was 320 u/L, alanine aminotransferase was 875 u/L, creatine kinase (CK) was 10,260 u/L, and CK-MB was 836 u/L. Echocardiography showed hypokinesia with preserved global systolic left ven-



**Figure 1.** Electrocardiogram upon admission, showing ST elevation in leads V<sub>1</sub>-V<sub>5</sub>.

tricular function, an ejection fraction of 36%, and no pericardial effusion. The primary diagnosis of the patient was acute anterior MI with multiple fractures of the legs and arms. The multiple fractures of the arms and legs were immediately repaired successfully. The patient still reported aggressive dyspnea and vomiting, and the ECG showed that the ST segment remained elevated. Therefore, coronary angiography was performed 48 hours after the limb fractures were treated.

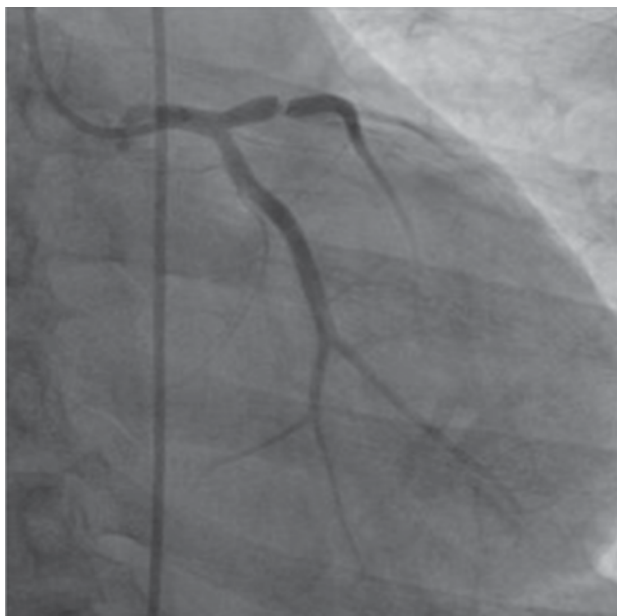
Coronary angiography revealed an occlusion of the left anterior descending artery and a TIMI flow grade of 2+, without significant lesions of other arteries (Figure 2). An intravascular ultrasound examination revealed obvious signs of coronary artery dissection at the calcium point of the intimal layer, intimal hematoma, and stripping of the intimal layer (Figure 3). Intracoronary thrombectomy was performed with an export aspiration catheter (6F, Medtronic Diver Kit Version Clot Extraction Catheter). However, the left anterior descending artery remained occluded, and no flow was obtained (Figure 4). Sodium nitro-

prusside and tirofiban were injected into the coronary artery 3 times, and the blood flow was TIMI 2+.

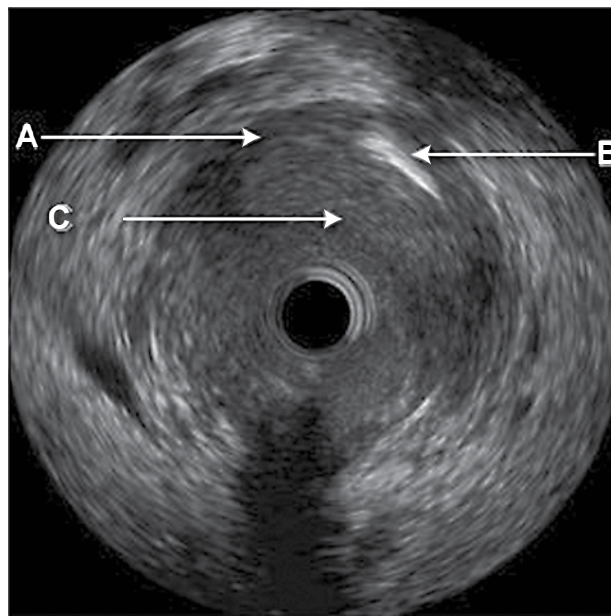
The patient was again returned to the care unit. The PCI procedure was repeated 2 days later. During this procedure, the export aspiration catheter was not used to remove the thrombosis. Stenosis of the left anterior descending artery was treated directly by balloon angioplasty. After this procedure, TIMI 2 blood flow was obtained. A rapamycin-eluting stent (3.0 mm × 23 mm) was placed in the left anterior descending artery (Figure 5). The patient was administered a  $\beta$ -blocker, nitrates, atorvastatin, aspirin, clopidogrel, and low-molecular-weight heparin. The clinical evolution was favorable. The patient was observed uneventfully in the hospital for 15 days before being discharged to home. On the outpatient follow-up visit 1 year after his procedure, the patient was asymptomatic and doing well.

## Discussion

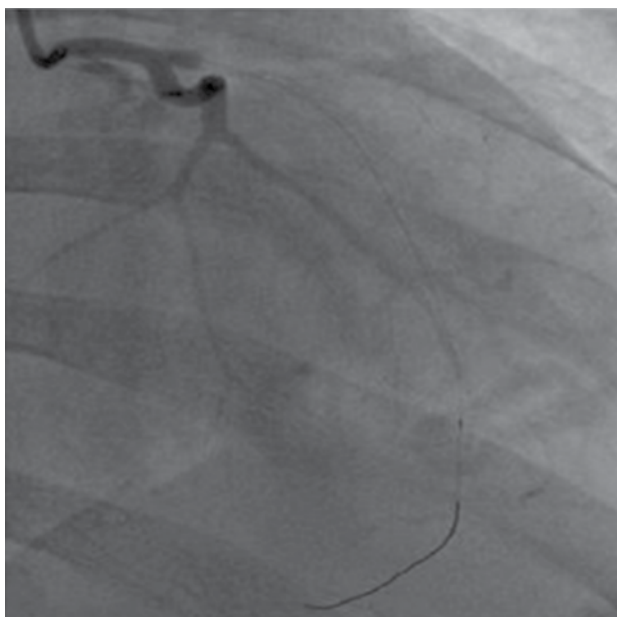
Although trauma-related MI is rare, evidence from numerous case studies suggests that trauma is among



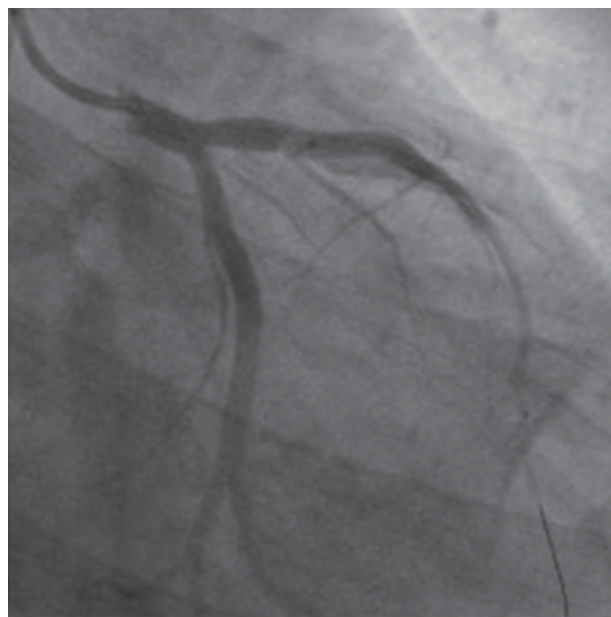**Figure 2.** Selective arteriography of the left coronary artery, showing occlusion of the left anterior descending coronary artery.



**Figure 3.** Intravascular ultrasound image showing an extensive intramural hematoma compressing the lumen of the left anterior descending artery. A – intramural hematoma. B – calcification point of intimal layer. C – stripping of the intimal layer.



**Figure 4.** Thromboaspiration caused no flow in the left anterior descending artery.



**Figure 5.** Final angiogram of the left anterior descending artery, showing TIMI 2 flow with no residual stenosis.

the non-atherosclerotic factors associated with acute MI, particularly in persons aged 45 years or younger.<sup>4</sup> Because the coronary arteries lie superficially on the

muscle wall, direct trauma with the resultant acute formation of coronary thrombosis is thought to be a probable mechanism of trauma-related acute MI.<sup>5</sup> A

shear force applied directly to the coronary artery can cause intimal tearing, potentially resulting in platelet aggregation and intracoronary thrombosis.<sup>6</sup> An existing atherosclerotic plaque might predispose the coronary arteries to trauma disruption.<sup>7</sup> In our patient, we believe that disruption of the coronary flow at the time of the initial chest trauma resulted in acute MI. The assumption is that intimal damage occurred with subsequent thrombotic occlusion.<sup>8</sup>

This report raises questions about the use of thrombectomy devices and the appropriate therapy in the setting of coronary occlusion after blunt injury. In this case, when the young man fell from the building, the external force injured the coronary artery and induced a stripping of the intima–medial layer.<sup>8</sup> The intimal lesion itself may have been responsible for the MI, by causing mechanical obstruction. We used thrombectomy to remove the intimal layer, which caused the coronary artery to spasm and did not result in blood flow. In this specific case, the use of a thrombectomy device was deleterious. Balloon angioplasty without thromboaspiration might have restored coronary flow properly. Our case demonstrates the diagnostic difficulty of identifying the underlying mechanism of coronary dissection after traumatic injury and determining the appropriate therapy.

## Conclusions

Thromboaspiration devices may not be suitable for the treatment of coronary occlusion caused by intimal stripping. Balloon angioplasty without thromboaspiration may be a more appropriate solution.

## Acknowledgments

We thank the study coordinators, Dangsheng Huang, Qiushuang Wang, and the participants.

## References

1. Tenzer ML. The spectrum of myocardial contusion: a review. *J Trauma*. 1985; 25: 620-627.
2. Allen RP, Liedtke AJ. The role of coronary artery injury and perfusion in the development of cardiac contusion secondary to nonpenetrating chest trauma. *J Trauma*. 1979; 19: 153-156.
3. Parmley LF, Manion WC, Mattingly TW. Nonpenetrating traumatic injury of the heart. *Circulation*. 1958; 18: 371-396.
4. Atalar E, Açil T, Aytemir K, et al. Acute anterior myocardial infarction following a mild nonpenetrating chest trauma – a case report. *Angiology*. 2001; 52: 279-282.
5. Sinha AK, Agrawal RK, Singh A, et al. Acute myocardial infarction due to blunt chest trauma. *Indian Heart J*. 2002; 54: 713-714.
6. Stewart JS. Primary traumatic coronary thrombosis. *Br Med J*. 1967; 1: 739-740.
7. Marcum JL, Booth DC, Sapin PM. Acute myocardial infarction caused by blunt chest trauma: successful treatment by direct coronary angioplasty. *Am Heart J*. 1996; 132: 1275-1277.
8. Keren A, Stessman J, Tzivoni D. Acute myocardial infarction caused by blast injury of the chest. *Br Heart J*. 1981; 46: 455-457.