

## Case Report

# Left Atrial Appendage Occlusion with the Amplatzer Amulet™ for Stroke Prevention in Atrial Fibrillation: The First Case in Greece

APOSTOLOS TZIKAS, LAMBROS KARAGOUNIS, MARIA BOUKTSI, ANTONIOS DREVELEGAS, DESPINA PARCHARIDOU, STATHIS IOANNIDIS, GEORGE KRASOPOULOS, GEORGE GIANNAKOULAS

*Interbalkan European Medical Center, Thessaloniki, Greece*

Key words:

**Structural heart disease, interventional cardiology, imaging.**

Left atrial appendage (LAA) occlusion has been introduced into clinical practice as a valuable alternative to oral anticoagulation for stroke prevention in patients with non-valvular atrial fibrillation. In this case presentation we describe the first LAA occlusion in Greece using the Amplatzer Amulet device. We also briefly discuss issues related to procedural safety and multimodality imaging for LAA occlusion.

*Manuscript received:*

June 12, 2013;

*Accepted:*

July 18, 2013.

*Address:*

Apostolos Tzikas

*Interbalkan European*

*Medical Center*

*10 Asklipiou St.*

*57001 Thessaloniki*

*Greece*

*e-mail:*

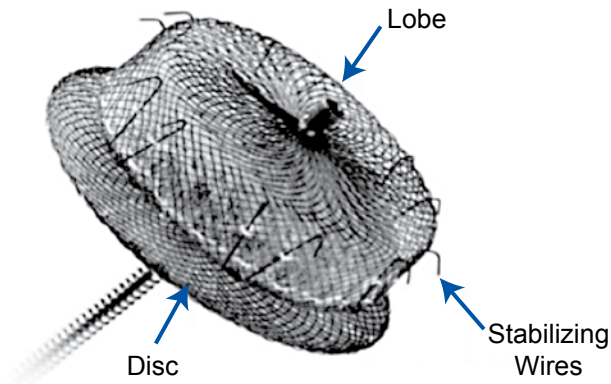
[aptzikas@yahoo.com](mailto:aptzikas@yahoo.com)

**A**trial fibrillation (AF), one of the most common cardiac arrhythmias, is considered responsible for up to 30% of all ischemic strokes.<sup>1</sup> The annual risk of AF-related stroke increases in elderly patients, rising from 1.5% for those aged 50-59 years to 23.5% for those aged 80-89 years.<sup>2</sup> The standard therapy for primary and secondary prevention of AF-related stroke is oral anticoagulants.<sup>3</sup> Echocardiographic studies have shown that in 90% of patients with non-valvular AF the thrombus is located in the left atrial appendage (LAA).<sup>4</sup> Recently, LAA occlusion has been introduced into clinical practice as a valuable alternative to oral anticoagulation (OAC) for patients who cannot tolerate anticoagulants or in case anticoagulants are ineffective. Results from the randomized clinical trial PROTECT AF for the Watchman device and initial registry reports for the Amplatzer Cardiac Plug (ACP) have been promising so far.<sup>5-8</sup> LAA occlusion was included in the latest ESC guidelines for the management of patients with AF (class of recommendation IIb, level of evidence B).<sup>3</sup> The Amplatzer Amulet device (AGA-St.

Jude Medical, MN, USA) is a successor of the ACP (Figure 1). Details regarding the device have been published elsewhere.<sup>9</sup> Herein we describe the first case of LAA occlusion in Greece using the Amplatzer Amulet.

## Case presentation

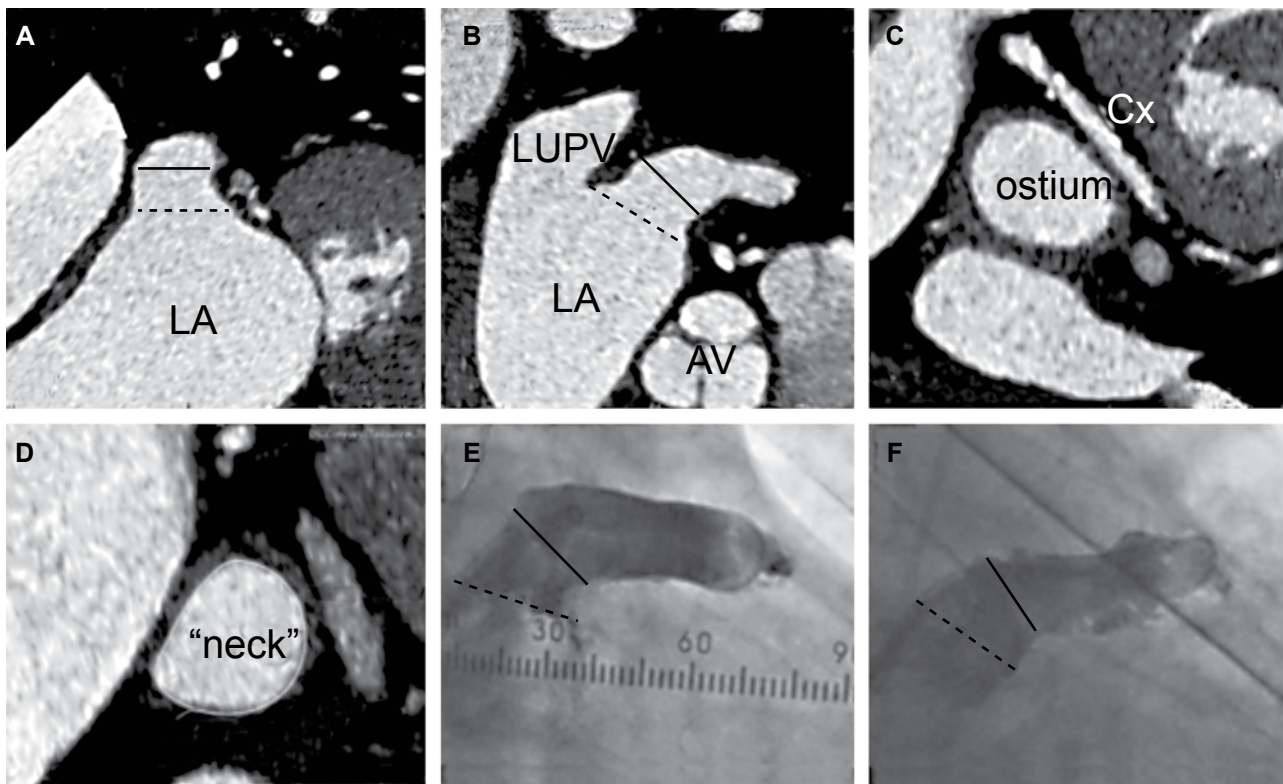
A physically active 76-year-old male with persistent AF was referred for LAA occlusion because of a transient ischemic attack (TIA) with hemiparesis 9 months previously, while on dabigatran 110 mg bid. The patient had a history of diabetes mellitus, arterial hypertension, peripheral vascular disease, coronary artery disease (3 previous PCIs 3-6 years ago), and a CHA<sub>2</sub>DS<sub>2</sub>VASc score of 7, which translates to a 21.5% annual risk for hospital admission and death due to thromboembolism. He was ineligible for warfarin because of labile INRs and had no history of bleeding. MRI angiography revealed small embolic infarcts in the brain and good quality cerebral arteries. After a multidisciplinary interrogation (neurologist, cardiologist, radiologist), the TIA



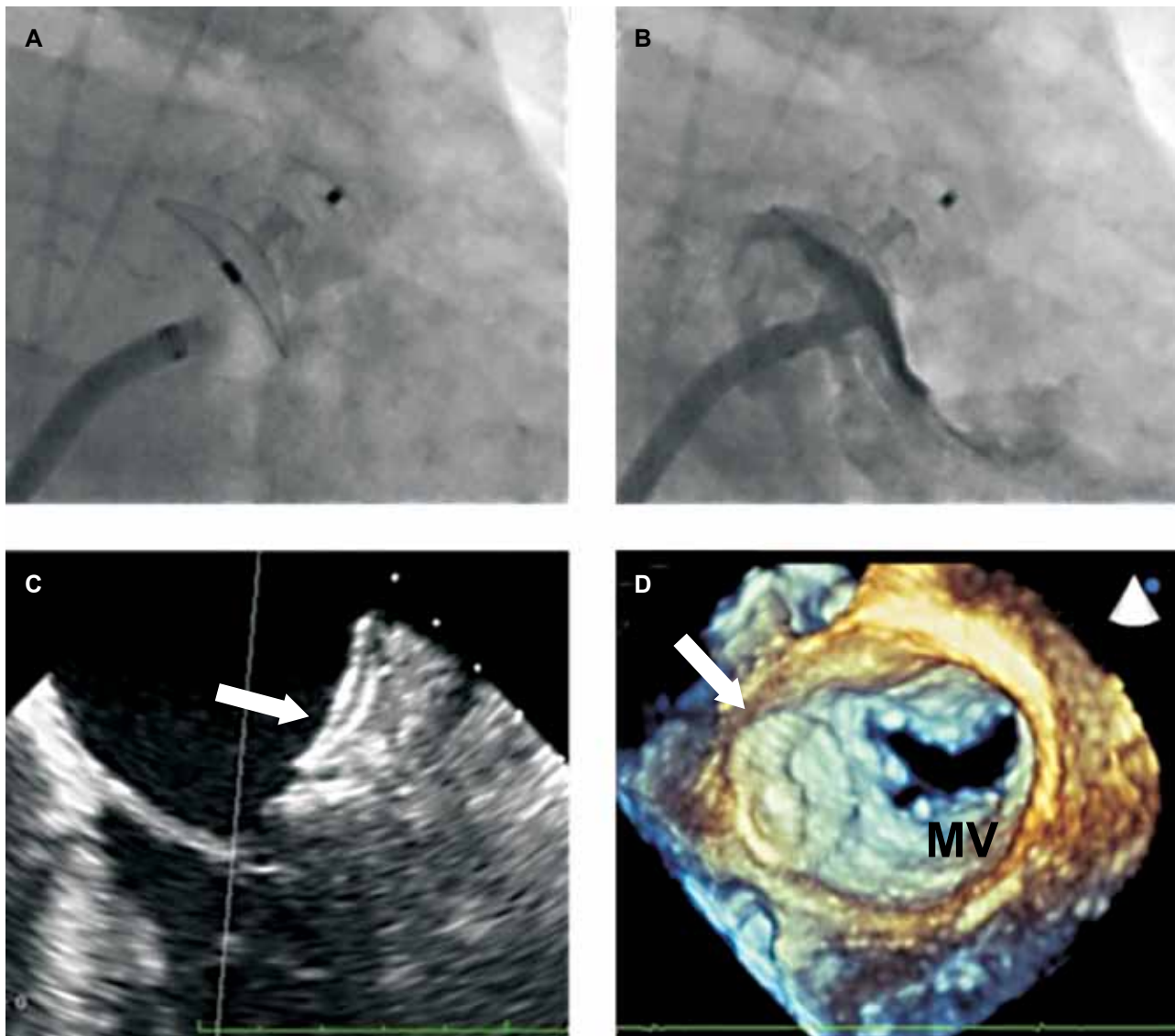
**Figure 1.** The Amplatzer Amulet™ device. The device consists of a lobe with stabilizing wires around it and a disk. The lobe acts as an anchoring mechanism securing the device in the “neck” of the left atrial appendage (LAA) (10-15 mm inside, distally to the ostium) whereas the disk seals the ostium, excluding the LAA from circulation.

was attributed to AF embolization and LAA occlusion was planned. The patient’s eligibility for treat-

ment with the Amplatzer Amulet was based on cardiac computed tomography angiography (CCTA) (Figure 2A-D). The presence of LAA thrombus was excluded. The LAA ostium was 20.2-25.6 mm (mean 23.9 mm, perimeter 72.2 mm) (Figure 2C) and the LAA “neck” (10 mm distally to the ostium) was 16.3-19.8 mm (mean 18.1 mm, perimeter 57.1 mm) (Figure 2D). The procedure was performed with the patient under general anesthesia and with transesophageal echocardiographic (TEE) and fluoroscopic guidance. Transseptal access was achieved via the right femoral vein, using an SL1 sheath and a BRK-1 needle (St. Jude Medical, MN, USA). Intravenous heparin was given with a target activated clotting time >250 s. A 5 F pigtail catheter was advanced through the transseptal sheath and an LAA angiogram was recorded (right anterior oblique 30° – cranial 15° view) (Figure 2E). The diameter of the LAA “neck” was 19.7 mm on angiography. The diameter of the LAA “neck” on TEE was 16.2 to 19.3 mm and the presence of a thrombus was excluded.



**Figure 2.** LAA measurements on CCTA and angiography. On CCTA, two orthogonal analysis windows (panels A and B) are used to define the LAA ostium (panel C) and “neck” (panel D). The dotted line corresponds to the LAA ostium and the straight line corresponds to the LAA “neck”, which is measured 10-15 mm distally to the ostium. Sizing for the Amplatzer Amulet is based on the mean diameter of the LAA “neck”. Panels E and F depict the LAA in RAO – cranial 15° and RAO – caudal 15° angiographic projections, respectively. LA – left atrium; LUPV – left upper pulmonary vein; Cx – circumflex coronary artery; LAA – left atrial appendage; CCTA – cardiac computed tomography angiography; RAO – right anterior oblique.



**Figure 3.** Multimodality imaging of the LAA after implantation of the Amplatzer Amulet device. The Amplatzer Amulet in its final position (panel A) on angiography. Contrast injection through the delivery sheath shows complete exclusion of the LAA from the circulation (panel B). TEE color-Doppler (panel C) and 3D-TEE (panel D) interrogation confirmed good positioning of the device (white arrow). LAA – left atrial appendage; TEE – transesophageal echocardiography; MV – mitral valve.

Based on the measurements of the LAA “neck”, a 22 mm Amplatzer Amulet device was chosen. The device was successfully implanted, through the Torque V 45-45 delivery sheath, in the intended position with no signs of residual shunt between the LAA and the left atrium on angiography. Complete LAA occlusion was confirmed by color-Doppler TEE. After careful stability testing the device was released. Final angiogram and 3D TEE verified complete occlusion of the LAA and a good circumferential apposition of the device disk on the LAA

ostium (Figure 3). No pericardial effusion or any other complication occurred. Total procedural time was 70 min and 100 mL of contrast were given. The patient was extubated in the catheterization laboratory and was discharged the following day on dabigatran 110 mg bid for 3 months and aspirin 100 mg qd for life. Two months after LAA occlusion the patient had no adverse events; a 3-month CCTA was planned in order to evaluate the completeness of closure and to guide decision making regarding anti-thrombotic treatment.

## Discussion

Currently, OAC treatment with warfarin, or new drugs such as dabigatran, apixaban, or rivaroxaban, is recommended in all patients with AF and  $\geq 1$  risk factor. However, in a recent publication, Kirley et al showed that, even in the era of new OAC drugs, only 60% of patients are properly treated.<sup>10</sup> The main reason for this OAC underuse is the increased risk of bleeding; physicians and patients are commonly reluctant to use OAC, despite the documented evidence supporting them. LAA occlusion is a new treatment option for primary and secondary prevention of stroke in patients with non-valvular AF. Recently, the 4-year results of PROTECT AF were released, showing the superiority of LAA occlusion with the Watchman device as compared to warfarin in terms of both primary efficacy and mortality.<sup>11</sup>

Technically, LAA occlusion is a rather demanding procedure with a substantial learning curve. The main concerns after the publication of PROTECT AF were related to the 7.7% rate of periprocedural complications, namely pericardial effusion and tamponade, stroke due to air embolism, and device embolization. Fortunately, the complication rate decreased to 3.7% in the PROTECT AF continued access protocol registry.<sup>5,6</sup> Similar results have been published for the ACP device.<sup>7,8</sup> The need for special operator skills (transseptal puncture experience, familiarity with self-expanding devices) in combination with the highly variable and delicate anatomy of the LAA may explain this phenomenon. Adequate training and careful patient selection are mandatory in order to avoid complications. Moreover, familiarity with LAA anatomy is important.

As in other "structural" heart interventions, the role of high-quality imaging is imperative. Before the procedure, a CCTA can provide valuable 3D information regarding the shape and dimensions of the LAA, the presence of thrombus, and its position in relation to the left atrium and the interatrial septum. Eligibility for treatment and sizing of the device to be implanted can be evaluated in advance and in great detail, decreasing procedural time and the need for multiple device deployments and wire exchanges. Consequently, patient safety is improved. During the procedure, adequate TEE guidance allows for an accurate transseptal puncture. In addition, TEE is used for the evaluation of complete LAA closure and device stability.

The Amplatzer Amulet is a second-generation

LAA occlusion device.<sup>9</sup> Compared to the ACP, it has a slightly longer lobe and a larger disk. It has more stabilizing wires around the lobe, which are also stiffer. The delivery cable has an inner wire that is used to evaluate the final position by releasing the tension on the system. Nevertheless, the implantation technique is practically the same: the target is to completely cover the LAA ostium with the device disk, creating continuity with the left atrial walls. Endothelialization is anticipated within 1-3 months. The current recommendation after LAA occlusion with the Amplatzer Amulet regarding antithrombotic treatment is aspirin 100 mg and clopidogrel 75 mg qd for 1-3 months and then only aspirin 100 mg qd for life. However, it should be noted that, for the moment, antithrombotic treatment after LAA occlusion is based on individual patient history and characteristics and no official recommendation exists.

Percutaneous LAA occlusion is now considered by many as a good alternative to OAC for stroke prevention in patients with AF. However, the initial promising results should be confirmed by large randomized clinical trials before this new treatment option is widely applied. In the meantime, careful patient selection and planning and adequate training of physicians are mandatory in order to offer safe and effective results to patients.

## References

1. Lloyd-Jones DM, Wang TJ, Leip EP, et al. Lifetime risk for development of atrial fibrillation: the Framingham Heart Study. *Circulation*. 2004; 110: 1042-1046.
2. Wolf PA, Abbott RD, Kannel WB. Atrial fibrillation as an independent risk factor for stroke: the Framingham Study. *Stroke*. 1991; 22: 983-988.
3. Camm AJ, Lip GY, De Caterina R, et al. 2012 focused update of the ESC Guidelines for the management of atrial fibrillation: an update of the 2010 ESC Guidelines for the management of atrial fibrillation. Developed with the special contribution of the European Heart Rhythm Association. *Eur Heart J*. 2012; 33: 2719-2747.
4. Blackshear JL, Odell JA. Appendage obliteration to reduce stroke in cardiac surgical patients with atrial fibrillation. *Ann Thorac Surg*. 1996; 61: 755-759.
5. Holmes DR, Reddy VY, Turi ZG, et al. Percutaneous closure of the left atrial appendage versus warfarin therapy for prevention of stroke in patients with atrial fibrillation: a randomised non-inferiority trial. *Lancet*. 2009; 374: 534-542.
6. Reddy VY, Holmes D, Doshi SK, Neuzil P, Kar S. Safety of percutaneous left atrial appendage closure: results from the Watchman Left Atrial Appendage System for Embolic Protection in Patients with AF (PROTECT AF) clinical trial and the Continued Access Registry. *Circulation*. 2011; 123: 417-424.
7. Park JW, Bethencourt A, Sievert H, et al. Left atrial append-

- age closure with Amplatzer cardiac plug in atrial fibrillation: initial European experience. *Catheter Cardiovasc Interv.* 2011; 77: 700-706.
8. Urena M, Rodés-Cabau J, Freixa X, et al. Percutaneous left atrial appendage closure with the AMPLATZER cardiac plug device in patients with nonvalvular atrial fibrillation and contraindications to anticoagulation therapy. *J Am Coll Cardiol.* 2013; 62: 96-102.
  9. Freixa X, Chan JL, Tzikas A, Garceau P, Basmadjian A, Ibrahim R. The Amplatzer™ Cardiac Plug 2 for left atrial appendage occlusion: novel features and first-in-man experience. *EuroIntervention.* 2013; 8: 1094-1098.
  10. Kirley K, Qato DM, Kornfield R, Stafford RS, Alexander GC. National trends in oral anticoagulant use in the United States, 2007 to 2011. *Circ Cardiovasc Qual Outcomes.* 2012; 5: 615-621.
  11. Reddy VY. Long term results of PROTECT AF: The mortality effects of left atrial appendage closure versus warfarin for stroke prophylaxis in AF. *Heart Rhythm Society 34th Annual Scientific Sessions*; May 9, 2013; Denver, CO.