

Original Research

Feasibility of Peripheral Venous Access for Temporary Right Ventricular Pacing

SPYRIDON DEFTEREOS¹, GEORGIOS GIANNOPOULOS¹, KONSTANTINOS RAISAKIS¹, CHARALAMPOS KOSSYVAKIS¹, VASILIKI PANAGOPOULOU¹, ANDREAS KAOUKIS¹, AGGELIKI-DESPOINA MAVROGIANNI², KONSTANTINOS DOUDOUMIS¹, ANDREAS THEODORAKIS¹, GEORGIOS BOBOTIS³, VLASIOS PYRGAKIS¹, CHRISTODOULOS STEFANADIS⁴

¹Department of Cardiology, Athens General Hospital "G. Gennimatas", ²Second Department of Cardiology, "G.N. Papanikolaou" Hospital, Thessaloniki, ³Cardiology Department, "G. Papageorgiou" Hospital, Thessaloniki, ⁴First Department of Cardiology, School of Medicine, University of Athens, Greece

Key words:

Temporary pacing, venous access, central, peripheral, complication.

Introduction: In this brief report, we present our experience from placing temporary pacing electrodes through peripheral venous access sites, at bedside, in a series of patients needing temporary pacing.

Methods: Consecutive patients requiring temporary pacing were selected. The median cubital or the basilic vein of the left upper extremity were used for catheterization at the bedside in all cases.

Results: 25 patients (17 men, age 64.6 ± 11.8) were included. The procedure was successful in 21 cases (84%), 18 of which were completed without the need for fluoroscopic guidance. The pacing leads remained for 4.2 ± 2.2 days. As expected, no serious complications related to venous puncture were observed. Although patients were allowed to be mobilized within the ward and engage in limited movements of the catheterized arm, in only one case was the lead displaced, requiring repositioning.

Conclusions: We provide observational evidence that the use of peripheral venous access for temporary pacing lead insertion (with no fluoroscopic guidance, as default strategy) is a safe and feasible choice that might be considered as an alternative to central vein catheterization.

Manuscript received:

August 16, 2011;

Accepted:

January 9, 2012.

Address:

Georgios Giannopoulos

Athens General Hospital

"G. Gennimatas"

154 Mesogeion Ave.

115 27 Athens, Greece

e-mail: [ggiann@](mailto:ggiann@med.uoa.gr)

med.uoa.gr

Peripheral venous access has been proposed in the past as a route for right heart access, mainly for diagnostic right heart catheterization.¹ However, it has not become mainstay, either for hemodynamic assessment of the right heart, or for other applications, such as obtaining an access route for temporary transvenous pacing, even though it may offer significant advantages compared to central venous access:² virtual elimination of the probability of lung puncture and pneumothorax, and avoidance of central venous line-related bloodstream infections.

In this brief report, we present our experience from placing temporary pacing electrodes through peripheral veins,

namely through the basilic or the median cubital vein, at bedside, in a series of patients who were admitted to a cardiology department and needed temporary pacing.

Methods

Consecutive patients requiring temporary pacing, either as a bridge to permanent pacemaker implantation or for bradycardia of reversible etiology, were selected for temporary pacing lead insertion at bedside, in the cardiology ward or the emergency room (unless fluoroscopic guidance was needed, in which case the patient was transferred to the electrophysiology laboratory). All patients provided informed consent.

The median cubital or the basilic vein of the left arm were used for catheterization in all cases. Using a hydrophilic guide wire, a 5-French peel-away introducer was inserted in the peripheral vein and used for introduction of the temporary pacing lead (Pacel™ Bipolar Pacing Catheters, St. Jude Medical, USA). The lead was advanced without fluoroscopic guidance (ideally, the electrode can be advanced through the basilic vein to the axillary vein and further into the subclavian, from where it can follow the usual route of insertion after catheterization of the subclavian vein, without the use of fluoroscopy)

(Figure 1). If obstacles were encountered, hindering the advancement of the pacing lead, the patient was transferred to the electrophysiology laboratory so that fluoroscopic guidance could be used.

Continuous variables are expressed as mean \pm standard deviation and categorical ones as counts and percentages.

Results

Twenty-five patients (17 men) were included (age 64.6 ± 11.8 years, range 49-91). The indications for

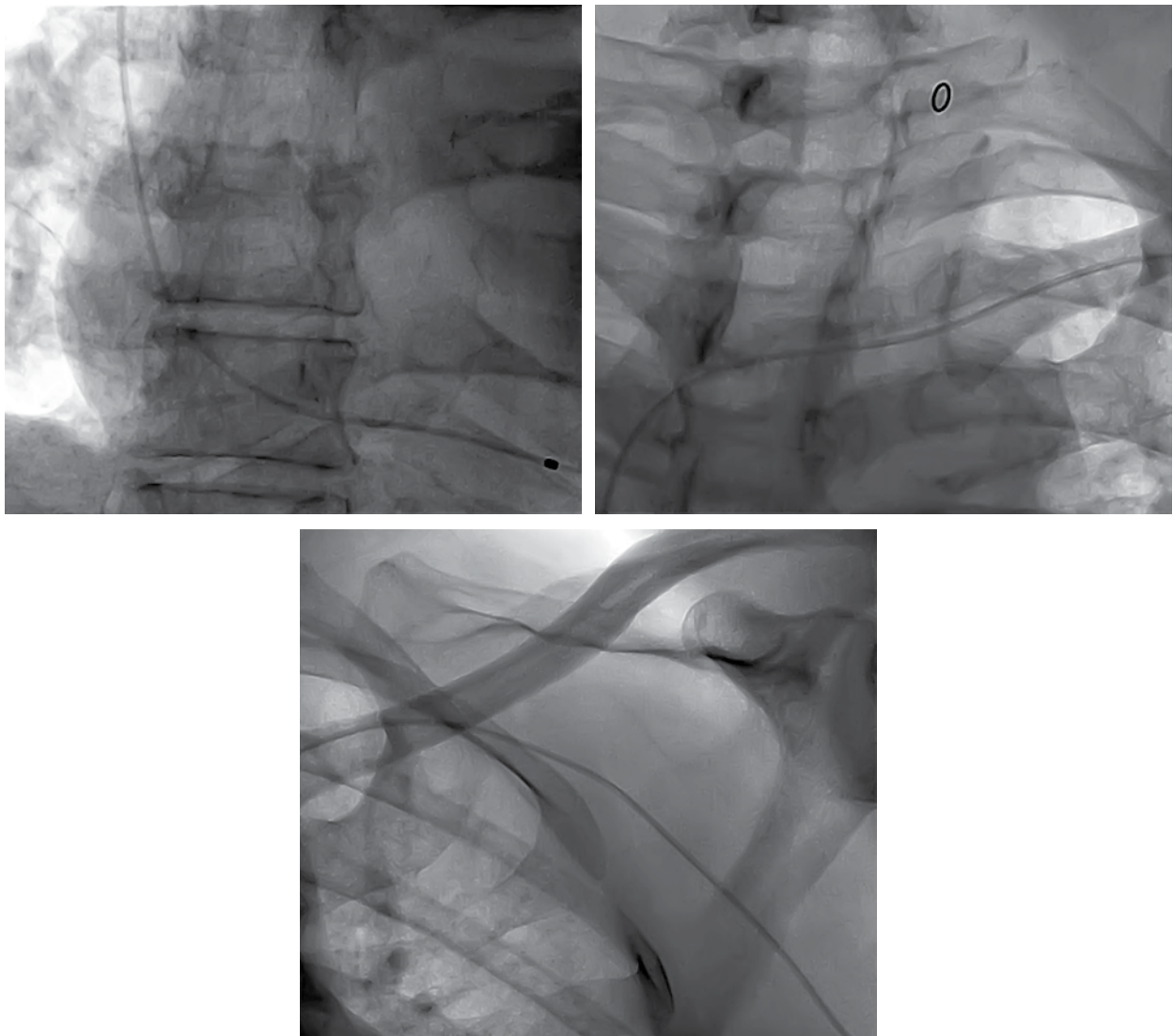


Figure 1. This 58-year-old patient needed temporary right ventricular pacing on an emergency basis due to advanced heart block during the acute phase of an inferior myocardial infarction. He was then taken to the catheterization lab, for primary coronary intervention. In these frames, from fluoroscopy loops recorded just before the angiogram, a bipolar temporary pacing lead can be seen at the apex of the right ventricle (top left frame), descending into the superior vena cava from the left subclavian vein (top right frame) and ascending to the axillary vein from the left basilic vein (bottom frame).

temporary pacing were advanced second degree or third degree heart block in 16 cases (64%), sinus node dysfunction in 7 (28%), and *torsades de pointes* secondary to sinus bradycardia in 2 (8%). The procedure was successful (resulted in reliable right ventricular pacing) in 21 cases (84%), 18 of which were completed without the need for fluoroscopic guidance. The reasons for failure were: inability to successfully catheterize the median cubital or the basilic vein (when the cephalic vein was catheterized, there was difficulty in successfully engaging the angle of insertion of the cephalic vein into the subclavian vein), and extremely small-sized or brittle peripheral veins (which explains why 3 of the 4 patients where the procedure failed were women). The mean time taken to insert the pacing lead and successfully pace the patient (measured from initial skin penetration of the venous puncture needle until the moment of recording the first right ventricular paced complex) was 16.1 ± 4.6 minutes.

The pacing leads remained for a mean of 4.2 ± 2.2 days. As expected, no serious complications related to venous puncture were observed. Two cases of thrombophlebitis of the catheterized peripheral vein were observed, which were self-limiting and remitted after removal of the lead. No cases of thromboembolism were observed. Although patients were allowed to be mobilized within the ward and engage in limited movements of the catheterized arm, in only one case was the lead displaced, requiring repositioning.

Discussion

Central vein cannulation is associated with relatively rare but potentially serious complications, most importantly arterial puncture (1-3%) and pneumo- or hemothorax (~1.5%).³ The occurrence of these complications may be even higher when central venous catheterization is performed in urgent or emergent settings, such as when patients require temporary pacing for complete heart block with hemodynamic compromise. The addition of a iatrogenic complication to the clinical status of these already compro-

mised patients may lead to extreme aggravation of their condition and outlook. Peripheral venous access for the placement of standard temporary pacing leads, proposed herein, appears to be a feasible and safe alternative to central venous access through the internal jugular or the subclavian vein.

The main drawback to the proposed procedure is the presence of small-sized tortuous peripheral veins in the upper extremities of some patients, which may render the catheterization of the basilic or the median cubital vein at the level of the antecubital fossa a rather arduous task, with uncertain success. However, experienced phlebotomists can manage to catheterize a peripheral vein in the vast majority of patients; in our series complete failure to gain peripheral venous access was uncommon. It is true that in our institution physicians had the option to immediately transfer the patient to the in-house electrophysiology laboratory for fluoroscopic guidance, which was very helpful, but this was only necessary in three of the 21 cases of successful lead placement. In any case, the need for fluoroscopic guidance is not a specific attribute of the proposed peripheral venous approach, since it may also arise when central venous catheterization is attempted.

In conclusion, we provide observational evidence that the use of peripheral venous access for temporary pacing lead insertion (with no fluoroscopic guidance, as default strategy) is a safe and feasible choice that might be considered as an alternative to central vein catheterization.

References

1. Gilchrist IC, Kharabsheh S, Nickolaus MJ, Reddy R. Radial approach to right heart catheterization: early experience with a promising technique. *Catheter Cardiovasc Interv.* 2002; 55: 20-22.
2. Deftereos S, Giannopoulos G, Kossyvakis C, et al. Feasibility and procedure-related patient discomfort of peripheral venous access for coronary sinus cannulation during electrophysiology procedures. *J Interv Card Electrophysiol.* 2012; 34: 161-165.
3. Ruesch S, Walder B, Tramèr MR. Complications of central venous catheters: internal jugular versus subclavian access – a systematic review. *Crit Care Med.* 2002; 30: 454-460.