

Case Report

The Use of the Multi-Electrode Duty-Cycled Radiofrequency Ablation Catheter PVAC for the Ablation of a Left Atrial Tachycardia

DIONYSSIOS LEFThERiOTIS¹, PANAYOTA FLEVARI¹, EFTIHIA SIMEONIDOU¹, DIMITRA NIOKOU², MARIA ANASTASIOU-NANA¹

¹Department of Cardiology, ²Department of Anesthesiology, "Attikon" University Hospital of Athens, Athens, Greece

Key words:

PVAC, left atrial tachycardia, ablation, pulmonary vein isolation.

The multi-electrode ablation catheter PVAC is used to simplify pulmonary vein isolation in patients undergoing ablation of atrial fibrillation. The use of the PVAC in cases of atrial tachycardia has not been reported before. In the present report, we present the use of the PVAC for the ablation of a left atrial tachycardia following pulmonary vein isolation. This case may suggest that the PVAC could ablate some atrial tachycardias without any adjunctive ablation catheter, given its ability to map, pace and apply energy over a relatively broad area.

Manuscript received:
May 16, 2011;
Accepted:
December 21, 2011.

Address:
Dionyssios I.
Leftheriotis

Department of
Cardiology
"Attikon" University
Hospital
Athens, Greece
e-mail: dleftheriotis@gmail.com

Pulmonary vein isolation (PVI) is a common treatment for patients with drug-refractory paroxysmal atrial fibrillation (AFib).^{1,2} The novel circular multi-electrode duty-cycled radiofrequency ablation catheter PVAC (Medtronic, Ablation Frontiers, Carlsbad CA, USA) is used to simplify the PVI procedure, and high acute success rates have been reported with this technique.³⁻⁶ Although left atrial tachycardias (ATs) may occur following AFib ablation, the use of PVAC for ablation of ATs has not been reported previously.⁷⁻⁹ In this report, we present a case of left AT induced following PVI and ablated using the PVAC.

Case presentation

A 70-year-old hypertensive woman was admitted to the hospital for ablation of symptomatic, drug-refractory AFib. She had a history of mastectomy, complicated with a severe lymphedema of the left upper extremity, and was under treatment

with propafenone, warfarin, ramipril, and analgesic agents (pregabalin, and a combination of acetaminophen and codeine phosphate). Propafenone was discontinued seven days before admission to the hospital, while warfarin was replaced by low molecular weight heparin three days before ablation. Transesophageal echocardiography performed 24 hours before the procedure ruled out the presence of thrombi in the left atrium (LA).

Following the sedation of the patient with a continuous intravenous infusion of propofol, a decapolar deflectable-tip catheter (Webster D-type, Biosence-Webster, CA, USA) was introduced into the coronary sinus (CS) via the left subclavian vein. Subsequently, a transseptal puncture was performed and heparin was infused to maintain an activated clotting time of 250 to 300 s throughout the procedure. Selective angiography of all four pulmonary veins (PVs) was performed and the PVAC was introduced into the LA via a sheath with a fixed curve (Frontier Advance 12

Fr transseptal sheath, Medtronic, Ablation Frontiers, Carlsbad CA, USA).

Subsequently, a three-dimensional reconstruction of the LA was performed using the EnSite NavX electroanatomic system (St. Jude, Austin TX, USA), for the purposes of a running study protocol at our laboratory, not related with the present report. This allowed us to better visualize the antra of the pulmonary veins. The PVAC was positioned at each antrum and radiofrequency (RF) energy was repeatedly deployed in a temperature-controlled (upper limit of 60°C), power-limited mode (maximum power 10 W). The duration of each application was 60 s in a 4:1 bipolar to unipolar ratio. Pacing from the CS was occasionally performed to differentiate the local signals or during sinus bradycardia. Complete PVI was documented in sinus rhythm by i) the lack of conduction to the LA during pacing within the PVs, and ii) mapping the PV ostia with the PVAC.

During the last application at the right inferior PV ostium, sinus bradycardia was observed again, and pacing from the CS was performed. This pacing induced an AT with a cycle length between 345 and 355 ms (Figure 1). The tachycardia was terminated by atrial extrasystoles or pacing bursts and consistently re-induced by pacing from the CS, demonstrating a consistent CS activation sequence and cycle length. During sinus rhythm, the PV ostia were mapped again by the PVAC and no conducting gaps across the ablation lines were detected. Subsequently, the PVAC was positioned at the left atrial isthmus (LAI), in order to better map the tachycardia. With pacing by the PVAC, the tachycardia was repeatedly entrained from different points of the LAI area with a post-pacing interval (PPI) almost equal to the AT cycle length (Figure 2). This was compatible with an LAI-dependent reentrant AT; therefore, RF current was deployed by all PVAC bipoles simultaneously across the LAI, over the region between the points of successful entrainment. The tachycardia was terminated during energy deployment (Figures 3 & 4), and it was not inducible following several pacing attempts. With the PVAC positioned in the left atrial appendage area, pacing maneuvers from the distal and proximal bipoles of the CS catheter were performed, but the complete LAI block was not documented.¹⁰ However, since the tachycardia was not induced, it was decided to terminate the procedure and keep the patient under close follow up.

Three days after ablation, the patient was discharged with instructions regarding antihypertensive

treatment and anticoagulation, and without any antiarrhythmic medication. For the next 6 months, she was followed monthly in the outpatients' clinic and 12-lead electrocardiograms were recorded. During this period, she remained asymptomatic and no episodes of AFib or AT were observed in the sequential electrocardiograms or in the 24-hour Holter recordings performed at the first, third and sixth month.

Discussion

PVI is the cornerstone of AFib ablation.¹¹ Complete PV disconnection with circumferential ablation in a wider area around the antral aspect of the PVs yields a better outcome than ablation in small areas around the ostia of the pulmonary veins (PVs) in patients with paroxysmal or short-standing persistent AFib.¹² PVAC is a novel circular ablation catheter used to simplify PVI by simultaneous RF current deployment through all bipoles located in its distal circular part in a single transseptal procedure.³⁻⁶ However, AFib ablation may lead to left atrial tachycardias in a considerable proportion of patients.^{8,9,13} Although a high acute success rate of AFib ablation with PVAC has been reported, the acute management of post-PVI left ATs has not been described so far.

To our knowledge, this is the first report to describe the ablation of a left AT using the PVAC. This tachycardia had the characteristics of a reentrant AT, related with the LAI area. The small variability of the cycle length, the consistent CS activation, and the fact that the AT was entrained from the LAI area could be compatible with a perimitral macro-reentry or a localized reentrant AT at the LAI.^{13,14} This would be in accordance with previous observations suggesting that the most common reentrant AT after PV isolation is atrial flutter around the mitral annulus.¹⁵ In the case of a LAI-dependent macro-reentry, deployment of RF current resulting in the creation of conduction block across the isthmus can terminate the tachycardia. However, complete LAI block is challenging, and often both endocardial and epicardial approaches are necessary, due to the variable shape and depth of the myocardial tissue in that area.¹⁶⁻¹⁸ In our case, a local micro-reentry in the LAI area might be the most likely mechanism, since the tachycardia was terminated and not inducible without documentation of complete bidirectional LAI block. The short post-pacing interval indicates the proximity of the pacing sites to the local circuit of the AT.^{19,20}

Detailed mapping with the PVAC of an AT following PVI would require a second mapping and ab-

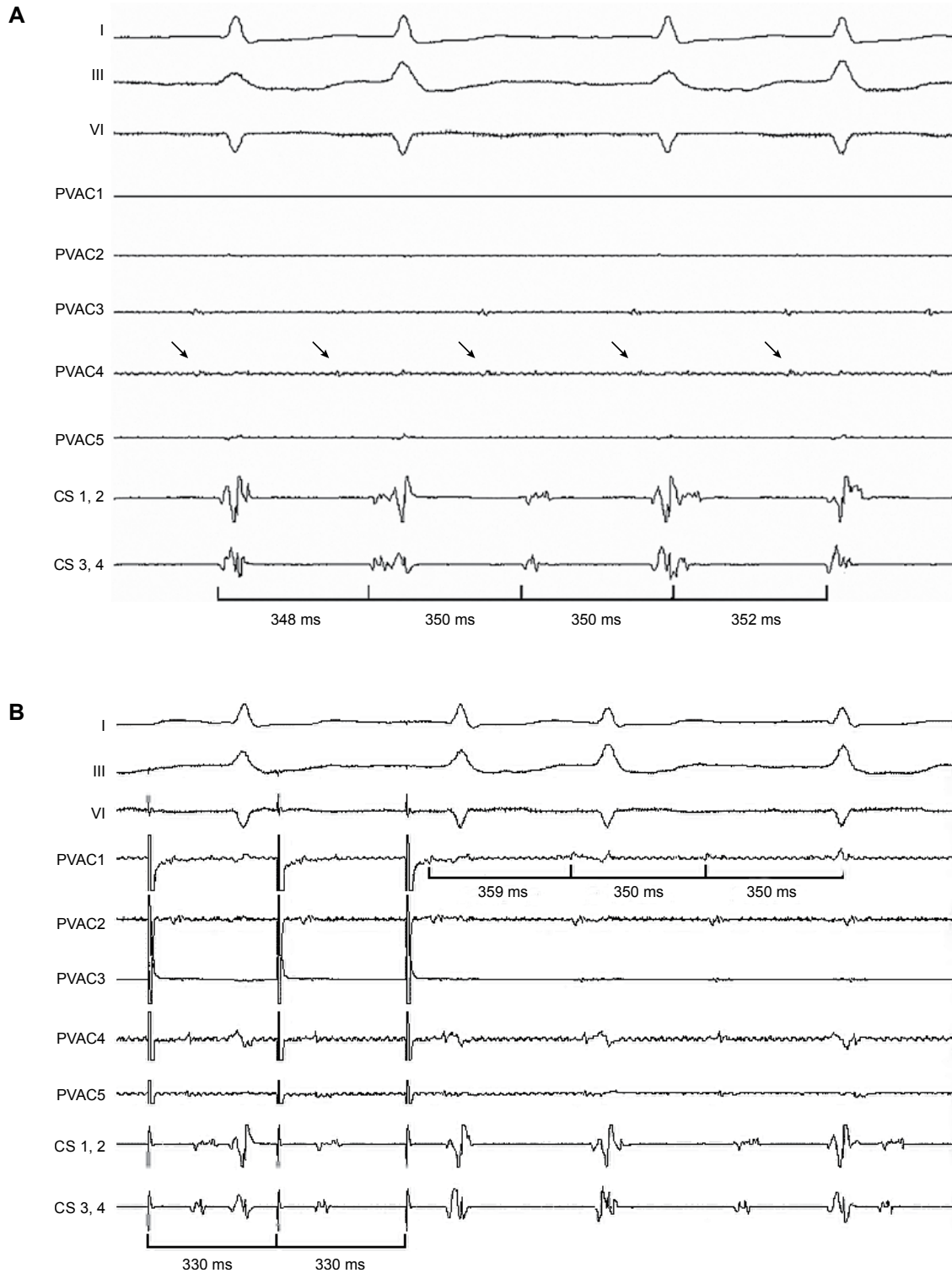


Figure 1. Electrocardiographic leads I, III and V1, along with electrograms recorded from the PVAC bipoles (PVAC 1 - PVAC 5) and the coronary sinus catheter (CS 1,2 and CS 3,4). A. The atrial tachycardia induced following pulmonary vein isolation with a rather stable cycle length is recorded by the CS catheter (in this strip the cycle length varies between 348 and 352 ms). The PVAC is located deep in the pulmonary vein ostium and records a low-voltage far-field atrial potential (arrows). B. The atrial tachycardia was entrained by pacing in the left atrial isthmus area from the PVAC (bipole 1) at a paced cycle length of 330 ms. The post-pacing interval was 359 ms, almost identical to the cycle length of the atrial tachycardia (350 ms).

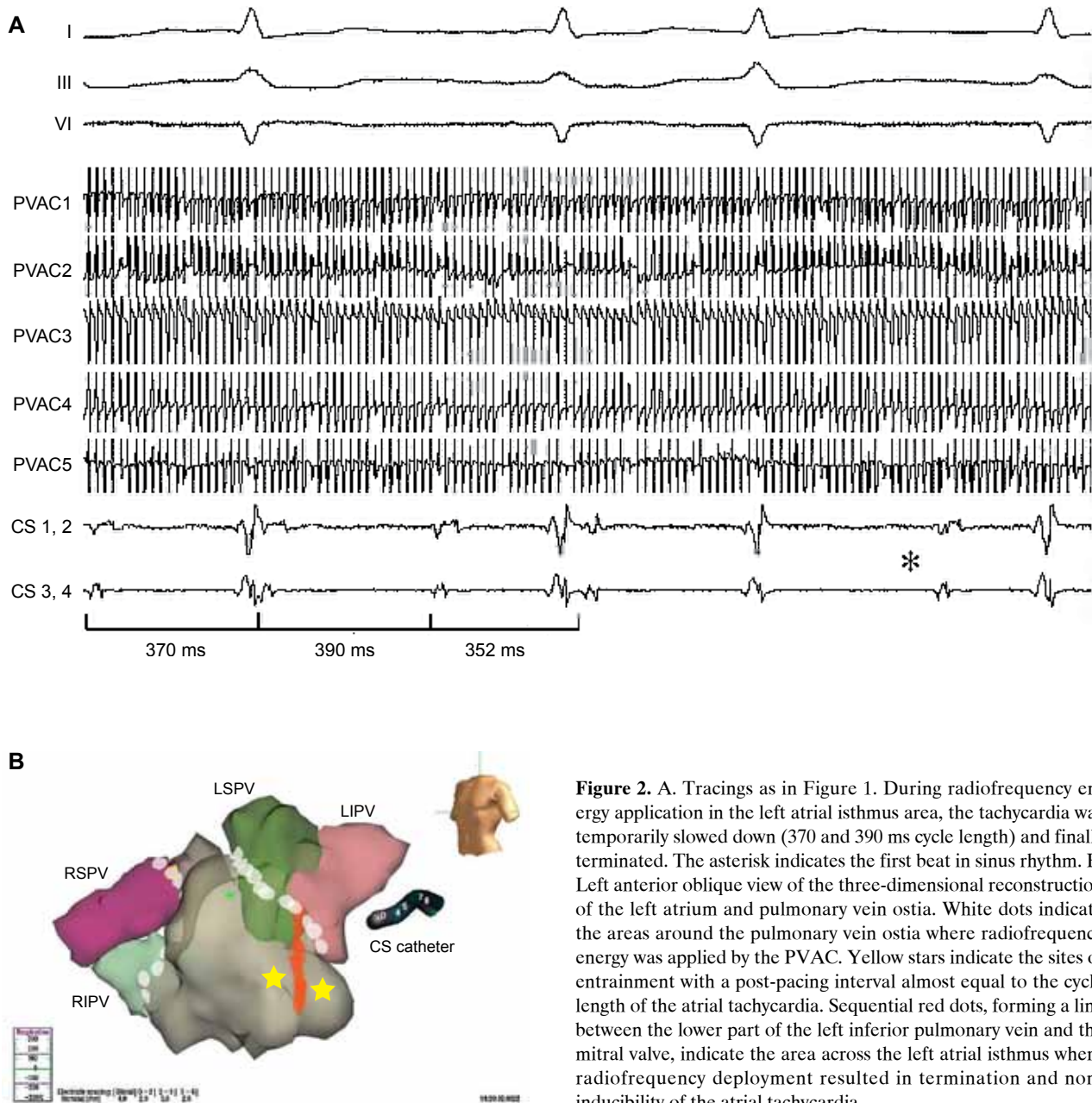


Figure 2. A. Tracings as in Figure 1. During radiofrequency energy application in the left atrial isthmus area, the tachycardia was temporarily slowed down (370 and 390 ms cycle length) and finally terminated. The asterisk indicates the first beat in sinus rhythm. B. Left anterior oblique view of the three-dimensional reconstruction of the left atrium and pulmonary vein ostia. White dots indicate the areas around the pulmonary vein ostia where radiofrequency energy was applied by the PVAC. Yellow stars indicate the sites of entrainment with a post-pacing interval almost equal to the cycle length of the atrial tachycardia. Sequential red dots, forming a line between the lower part of the left inferior pulmonary vein and the mitral valve, indicate the area across the left atrial isthmus where radiofrequency deployment resulted in termination and non-inducibility of the atrial tachycardia.

lating catheter (either a multipolar or a conventional irrigated-tip catheter), and this would increase the cost and time of the procedure. In such cases, the use of the PVAC for mapping and ablating the tachycardia could be tried before using a second catheter, and could turn out to be a time- and money-saving method, as the present case suggests. The ability of the PVAC to cover a relatively broad area for mapping, pacing and energy deployment might be an advantage of this catheter, and the use of other adjunctive catheters may not be necessary. Simultaneous delivery of RF current by all electrode pairs may have an effect similar to that of clas-

sic linear lesions across the isthmus of the local circuit, which terminate the tachycardia.¹³ However, since the catheter is designed for the PV ostia, further investigation is required in order to evaluate its efficacy in other areas and the risk of clotting during RF deployment.

References

1. Nault I, Miyazaki S, Forclaz A, et al. Drugs vs. ablation for the treatment of atrial fibrillation: the evidence supporting catheter ablation. *Eur Heart J.* 2010; 31: 1046-1054.
2. Fuster V, Rydén LE, Asinger RW, et al. ACC/AHA/ESC

- Guidelines for the Management of Patients With Atrial Fibrillation: Executive Summary A Report of the American College of Cardiology/American Heart Association Task Force on Practice Guidelines and the European Society of Cardiology Committee for Practice Guidelines and Policy Conferences (Committee to Develop Guidelines for the Management of Patients With Atrial Fibrillation) Developed in Collaboration With the North American Society of Pacing and Electrophysiology. *Circulation*. 2001; 104: 2118-2150.
3. Boersma LV, Wijffels MC, Oral H, Wever EF, Morady F. Pulmonary vein isolation by duty-cycled bipolar and unipolar radiofrequency energy with a multielectrode ablation catheter. *Heart Rhythm*. 2008; 5: 1635-1642.
 4. Beukema RP, Beukema WP, Smit JJ, et al. Efficacy of multi-electrode duty-cycled radiofrequency ablation for pulmonary vein disconnection in patients with paroxysmal and persistent atrial fibrillation. *Europace*. 2010; 12: 502-507.
 5. Raffa S, Grosse A, Brunelli M, Wauters K, Geller JC. Voltage mapping and pacing to assess the level of pulmonary venous isolation achieved with a novel circular multielectrode ablation catheter. *Europace*. 2010; 12: 933-940.
 6. Wiczonek M, Hoeltgen R, Akin E, Salili AR, Oral H, Morady F. Results of short-term and long-term pulmonary vein isolation for paroxysmal atrial fibrillation using duty-cycled bipolar and unipolar radiofrequency energy. *J Cardiovasc Electrophysiol*. 2010; 21: 399-405.
 7. Gerstenfeld EP, Callans DJ, Dixit S, et al. Mechanisms of organized left atrial tachycardias occurring after pulmonary vein isolation. *Circulation*. 2004; 110: 1351-1357.
 8. Chae S, Oral H, Good E, et al. Atrial tachycardia after circumferential pulmonary vein ablation of atrial fibrillation: mechanistic insights, results of catheter ablation, and risk factors for recurrence. *J Am Coll Cardiol*. 2007; 50: 1781-1787.
 9. Chang SL, Lin YJ, Tai CT, et al. Induced atrial tachycardia after circumferential pulmonary vein isolation of paroxysmal atrial fibrillation: electrophysiological characteristics and impact of catheter ablation on the follow-up results. *J Cardiovasc Electrophysiol*. 2009; 20: 388-394.
 10. Jaos P, Hocini M, O'Neill MD, et al. How to perform linear lesions. *Heart Rhythm*. 2007; 4: 803-809.
 11. Wright M, Haïssaguerre M, Knecht S, et al. State of the art: catheter ablation of atrial fibrillation. *J Cardiovasc Electrophysiol*. 2008; 19: 583-592.
 12. Arentz T, Weber R, Bürkle G, et al. Small or large isolation areas around the pulmonary veins for the treatment of atrial fibrillation? Results from a prospective randomized study. *Circulation*. 2007; 115: 3057-3063.
 13. Weerasooriya R, Jais P, Wright M, et al. Catheter ablation of atrial tachycardia following atrial fibrillation ablation. *J Cardiovasc Electrophysiol*. 2009; 20: 833-838.
 14. Chang SL, Tsao HM, Lin YJ, et al. Differentiating macroreentrant from focal atrial tachycardias occurred after circumferential pulmonary vein isolation. *J Cardiovasc Electrophysiol*. 2011; 22: 748-755.
 15. Chugh A, Oral H, Lemola K, et al. Prevalence, mechanisms, and clinical significance of macroreentrant atrial tachycardia during and following left atrial ablation for atrial fibrillation. *Heart Rhythm*. 2005; 2: 464-471.
 16. Knecht S, Hocini M, Wright M, et al. Left atrial linear lesions are required for successful treatment of persistent atrial fibrillation. *Eur Heart J*. 2008; 29: 2359-2366.
 17. Matsuo S, Wright M, Knecht S, et al. Peri-mitral atrial flutter in patients with atrial fibrillation ablation. *Heart Rhythm*. 2010; 7: 2-8.
 18. Wittkamp FH, van Oosterhout MF, Loh P, et al. Where to draw the mitral isthmus line in catheter ablation of atrial fibrillation: histological analysis. *Eur Heart J*. 2005; 26: 689-695.
 19. Mohamed U, Skanes AC, Gula LJ, et al. A novel pacing maneuver to localize focal atrial tachycardia. *J Cardiovasc Electrophysiol*. 2007; 18: 1-6.
 20. Tzeis S, Andrikopoulos G, Vardas P, Theodorakis G. Atrial tachycardia after ablation of atrial fibrillation: ten steps to diagnosis and treatment. *Hellenic J Cardiol*. 2011; 52: 345-351.