

## Case Report

## Role of Grey-Scale Intravascular Ultrasound and ChromaFlo in Deciding on Treatment Approach for Spontaneous Coronary Dissection in a Young Woman

SPYRIDON DEFTEREOS<sup>1</sup>, GEORGIOS GIANNOPOULOS<sup>1</sup>, AGGELIKI MAVROGIANNI<sup>2</sup>,  
ALEXANDROS SYKIOTIS<sup>1</sup>, VLASIOS PYRGAKIS<sup>1</sup>, GEORGIOS BOBOTIS<sup>2</sup>

<sup>1</sup>Cardiology Department, Athens General Hospital "G. Gennimatas", Athens, <sup>2</sup>Cardiology Department, "G. Papageorgiou" Hospital, Thessaloniki, Greece

**Key words:** Coronary, spontaneous, dissection, intravascular ultrasound, ChromaFlo.

Spontaneous coronary artery dissection (SCAD) is a rare cause of acute coronary syndromes. We present the case of a young woman with an acute coronary syndrome caused by SCAD, where grey-scale intravascular ultrasound (IVUS) and ChromaFlo were instrumental in deciding against interventional treatment. The patient's urgent angiogram gave the impression of a spiral dissection in the right coronary artery. IVUS confirmed the presence of an intimal flap and the ChromaFlo study showed unobstructed flow throughout the dissected segments. No atherosclerotic plaques or intramural hematomas were imaged on the IVUS pull-back. In this case, grey-scale IVUS was used to confirm the absence of atherosclerotic coronary artery disease and ChromaFlo to assess flow in the true and the false lumen, excluding the presence of no-flow intramural hematomas. Based on these findings, it was decided to adopt a conservative treatment strategy.

*Manuscript received:*  
February 11, 2011;  
*Accepted:*  
May 16, 2011.

*Address:*  
Georgios Giannopoulos

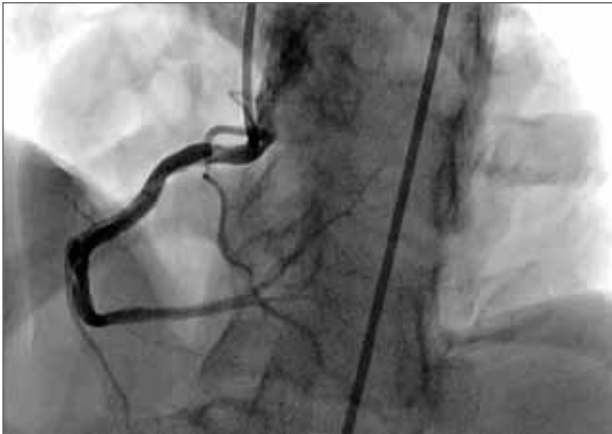Cardiology Department  
Athens General Hospital  
"G. Gennimatas"  
154 Mesogeion Ave.  
115 27, Athens, Greece  
e-mail: [ggiann@med.uoa.gr](mailto:ggiann@med.uoa.gr)

**S**pontaneous coronary artery dissection (SCAD) is a rare cause of acute coronary syndromes, although its true incidence may be underestimated.<sup>1,2</sup> Intravascular ultrasound (IVUS) has been used mainly in guiding the interventional treatment of coronary dissection, such as confirmation of guidewire placement in the true lumen.<sup>3</sup> We present the case of a young woman with an acute coronary syndrome caused by SCAD, where grey-scale IVUS, as well as the ChromaFlo modality, were decisive in choosing between treatment options.

### Case presentation

A 34-year-old woman, with no medical history, presented to our emergency department complaining of acute substernal chest

pain, with accompanying dynamic electrocardiographic changes and mild troponin I elevation. An angiogram performed on the same day showed a fully patent coronary tree; however, a linear flap-like transparency was shown in the right coronary artery (RCA), giving the impression of a spiral dissection, extending from the proximal segment, immediately after the branch to the right ventricle, to the distal part of the vessel (Figure 1). The vessel was patent, with no compromise of flow. In order to confirm the angiographic findings and assess the presence and extent of atherosclerotic disease, an IVUS examination was decided upon (s5™ Imaging System, Eagle Eye® Gold Catheter, Volcano Co., San Diego CA, USA). IVUS indicated the presence of an intimal flap (Figure 2A). The two lumens were more clearly imaged by

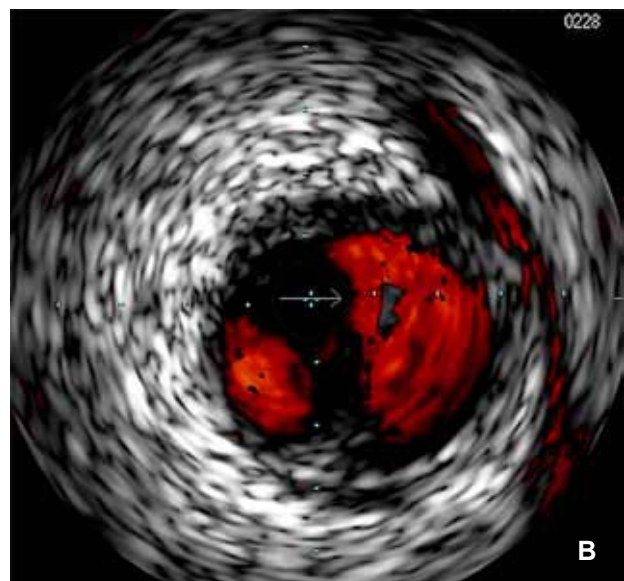
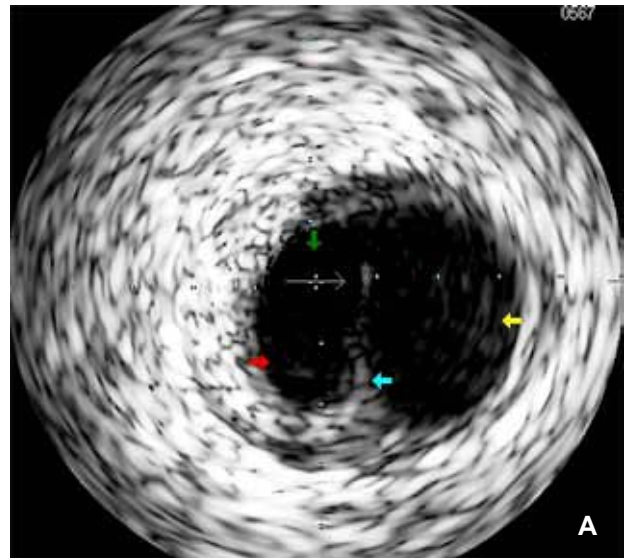


**Figure 1.** A left anterior oblique angiographic view with cranial angulation of the right coronary artery. A continuous intraluminal linear transparency is evident from the proximal part of the vessel. This picture strongly suggests dissection of the vessel wall.

ChromaFlo, a modality that depicts blood flow by comparing sequential axial IVUS images and interpreting any differences in the position of echogenic blood particles as blood flow (Figure 2B). The ChromaFlo study confirmed unobstructed flow throughout the dissected segments. No atherosclerotic plaques were imaged on the IVUS pull-back.

Although there are no large series, it is generally accepted that if there is no obstruction of antegrade flow in single-vessel spontaneous dissection, conservative management is a sound choice.<sup>3</sup> In our case, gray-scale IVUS was used to confirm the absence of atherosclerotic coronary artery disease and ChromaFlo to assess flow in the true and the false lumen, excluding the presence of no-flow intramural hematomas (which if left untreated could progress, leading to significant subsequent constriction of the vessel lumen and, thus, recurrent ischemia). Based on these findings, along with the patient's profile (menstruating young woman, with child-bearing potential), it was decided not to perform stenting.

The patient was put on dual antiplatelet treatment and observed in the cardiac care unit. An initial workup aiming at revealing connective tissue disorders and coagulopathies was negative. Ten days later, the patient was asymptomatic, with cardiac biomarkers within the reference range. A pre-discharge follow-up angiogram was performed, showing a virtually unchanged picture of the RCA (presence of intraluminal flap without flow compromise). The patient was still asymptomatic, without any intervening events, three months after discharge.



**Figure 2.** A: Intravascular ultrasound image revealing a flap (blue arrow) that transects the lumen of the vessel into the true lumen (red arrow), with the intravascular ultrasound catheter (green arrow), and the false lumen (yellow arrow). B: The ChromaFlo feature images blood flow in both lumens, which explains the angiographic image of a completely patent right coronary artery.

## Discussion

In cases of coronary dissection, IVUS can distinguish atherosclerotic plaques from intramural hematoma and also detect the media dissection, false and true lumen and, if present, the intimal flap. Treatment of spontaneous dissection in particular is often especially challenging, since it commonly affects young individuals with little or no atherosclerotic burden. Ther-

apy has traditionally been guided by clinical and angiographic findings. However, in small series of patients IVUS has been proven useful in the context of interventional treatment.<sup>3</sup> In the case presented here, IVUS contributed to reaching a decision for non-intervention, despite the extent of the dissection, as it confirmed the absence of significant atheromatous substrate, patency and unobstructed flow in the true lumen and absence of potentially progressing intramural hematomas, which can lead to subsequent encroachment of the lumen and possibly a new coronary event.

## References

1. Mortensen KH, Thuesen L, Kristensen IB, Christiansen EH. Spontaneous coronary artery dissection: a Western Denmark Heart Registry study. *Catheter Cardiovasc Interv.* 2009; 74: 710-717.
2. Vogiatzis I, Hadjimiltiades S, Sachpekidis V, Parcharidis G. Spontaneous coronary artery dissection and acute myocardial infarction during pregnancy. *Hellenic J Cardiol.* 2010; 51: 74-80.
3. Arnold JR, West NE, van Gaal WJ, Karamitsos TD, Banning AP. The role of intravascular ultrasound in the management of spontaneous coronary artery dissection. *Cardiovasc Ultrasound.* 2008; 6: 24.