

Case Report

Congenital Tricuspid Valve Blood Cyst: Imaging with Three-Dimensional Contrast Echocardiography

JULIA GRAPSA, WING-SEE CHEUNG, DAVID DAWSON, PETROS NIHOYANNOPOULOS

Department of Cardiology, Hammersmith Hospital, Imperial College NHS Trust, London, UK

Key words:

Tricuspid valve, cyst, three-dimensional echocardiography.

We describe the case of an 88-year-old woman who presented in WHO functional class III and breathless on exertion. She was investigated for pulmonary hypertension. However, two-dimensional echocardiography demonstrated a rounded mass attached to the septal leaflet of the tricuspid valve. Real-time three-dimensional echocardiography with contrast microbubbles was the imaging modality of choice to characterise the cyst and to guide the decision as to the best therapeutic approach for the patient.

Manuscript received:

April 4, 2010;

Accepted:

June 7, 2010.

Address:

Julia Grapsa

*Cardiology Department
Cardiovascular Sciences
Hammersmith Hospital
Du Cane Road,
London W12 0HS, UK
e-mail:*

jgrapsa@gmail.com

Congenital blood cysts are rare in adults but also usually asymptomatic. Here we describe a patient with symptoms of pulmonary hypertension, in whom a blood cyst was identified by echocardiography.

Case presentation

An 88-year-old woman presented in WHO functional class III and breathless on exertion. From her past medical history, she had had a multi-nodular goitre surgery 50 years before, hypothyroidism, an adrenal mass diagnosed 4 years before, systemic hypertension, type 2 diabetes mellitus and hyperlipidaemia. On examination, she was normotensive, with heart rate 51 beats/min and finger oxygen saturation in room air 91%. On auscultation, a high pitched systolic murmur was audible at the lower left sternal border. The electrocardiogram demonstrated sinus rhythm with a mean frontal QRS axis of 37 degrees. The R-wave in V1 was dominant and signs of right ventricular hypertrophy were present. A chest roentgenogram did not demonstrate any sign

of abnormality. During a 6-minute walk test, the patient walked for 60 metres with Borg dyspnoea scale rated 5 pre-test and 7 post-test. The patient stopped after 2 minutes because of breathlessness. Computed tomography and ventilation-perfusion scans were negative for pulmonary embolism. A cardiac magnetic resonance scan was also performed and demonstrated a rounded mass attached to the septal leaflet of the tricuspid valve. The composition of the mass could not be differentiated; therefore, a transoesophageal echocardiogram was suggested. However, the patient declined to have the transoesophageal echocardiogram. Therefore, we proceeded to the transthoracic echocardiogram.

The two-dimensional echocardiogram demonstrated a normal sized left ventricle with good systolic function. The left atrium was dilated and there was moderate mitral regurgitation due to prolapse of the anterior mitral leaflet. In addition, the patient had a mildly dilated, impaired and pressure loaded right ventricle and a dilated right atrium. The tricuspid regurgitation was moderate and there was

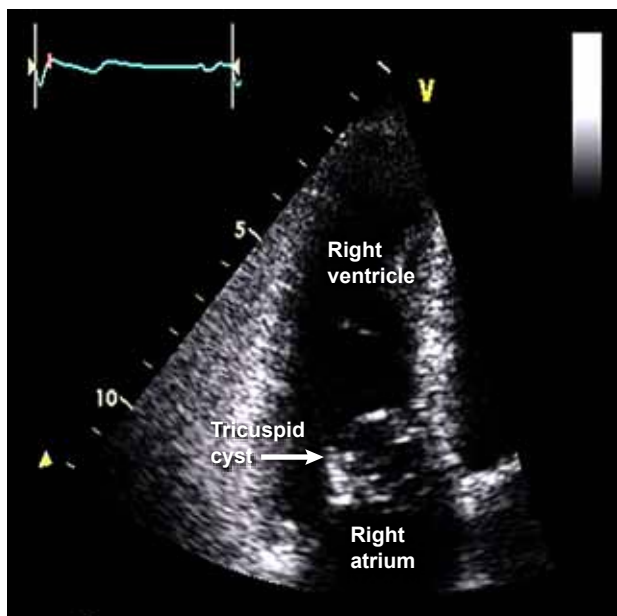


Figure 1. Transthoracic two-dimensional echocardiogram, showing the cyst attached to the septal tricuspid leaflet.

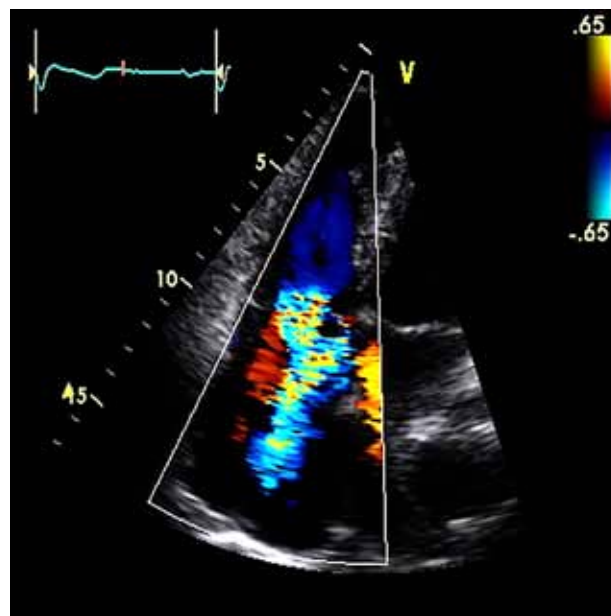


Figure 2. Moderate tricuspid regurgitation demonstrated with colour Doppler imaging.

a cyst attached to the septal leaflet, without prolapsing into the right atrium and with good apposition of leaflets. For the best characterisation of tissue and description of the cyst, a contrast three-dimensional (3D) echocardiogram with microbubbles was performed. It showed that the cyst was congenital and full of blood, with thin borders, and its size was 2.5 to 1.7 cm.

The patient had a right heart catheterisation with the cyst remaining intact. The catheterisation demonstrated a mean pulmonary arterial pressure of 22 (36/12) mmHg with a right ventricular systolic pressure of 35 mmHg and a mixed venous oxygen saturation of 76%. The left ventricular saturation was 97%, giving a cardiac output of 4.97 L/min and a cardiac index of 3.15. These findings were consistent with mild pulmonary hypertension related to left heart disease. It is known that this form of pulmonary hypertension requires no specific anti-pulmonary hypertensive therapy and it was decided that an intervention would not benefit the patient.

Discussion

The finding of congenital blood cyst was first described by Elsasser in 1844¹ and later, in 1957,² Kindred published the histological description of a cyst in the primordium of the tricuspid valve of an abnor-

mal human embryo. According to his histology report, it was believed that the cyst did not arise from endothelium but myocardium. Further pathology reports in 1996 by Marcato and his colleagues³ demonstrated that blood cysts derive from enlargement of blood and lymphatic valvular vessels. Also, they are rare in adults, they do not increase with age and they occasionally obstruct the right ventricular outflow tract.

Congenital blood cysts are usually asymptomatic. Once discovered, the differential diagnosis is right atrial myxoma, abscess, hydatid cyst, fibroelastoma or marantic endocarditis. The homogenous pattern of fluid and the absence of any calcification supports the diagnosis of a blood cyst.⁴ Excision is usually recommended only if there are any complications related to the cyst, such as right ventricular outflow tract obstruction.^{5,6}

The best and least invasive imaging of the cyst can be achieved with contrast 3D echocardiography with microbubbles, and this is the second case in the literature⁶ to be imaged with the specific modality. It can differentiate the cyst from a malignant mass and in three dimensions; all three leaflets are reconstructed in a model, as demonstrated in Figure 3. Furthermore, the assessment of regurgitation severity and the borders of the cyst attachment are important for a possible surgical resection.

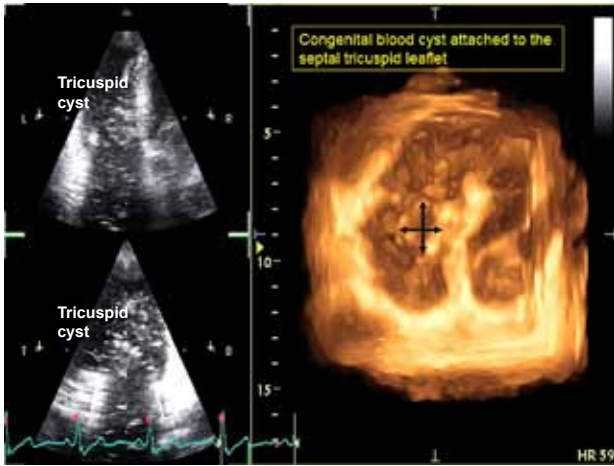


Figure 3. Real-time three-dimensional echocardiography. Reconstruction of the tricuspid valve from the short axis: the cyst is attached to the septal leaflet.

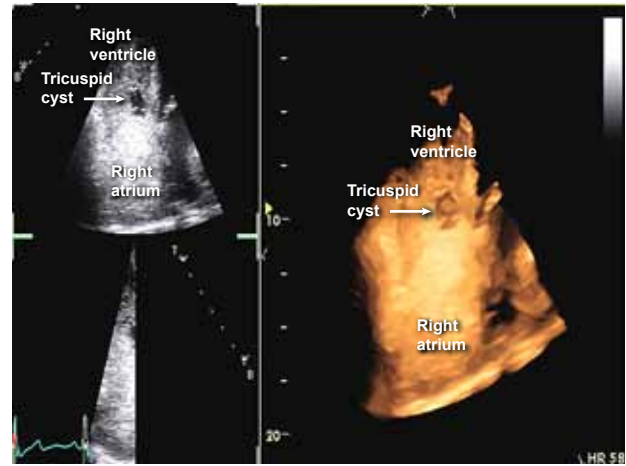


Figure 4. Real-time three-dimensional contrast echocardiography with microbubbles.

References

1. Elsasser C. Bericht uber die Ereignisse in der Gebaranstalt des Catherinen Hospital im Jahre 1844. *Med Correspondenzblatt.* 1844; 14: 297.
2. Kindred JE. A cyst in the primordium of the tricuspid valve of an abnormal human embryo. *Am J Pathol.* 1957; 33: 967-975.
3. Marcato PS, Benazzi C, Bettini G, et al. Blood and serous cysts in the atrioventricular valves of the bovine heart. *Vet Pathol.* 1996; 33: 14-21.
4. Zimmerman KG, Paplanus SH, Dong S, Nagle RB. Congenital blood cysts of the heart valves. *Hum Pathol.* 1983; 14: 699-703.
5. Gallucci V, Stritoni P, Fasoli G, Thiene G. Giant blood cyst of tricuspid valve. Successful excision in an infant. *Heart.* 1976; 38: 990-992.
6. Timberley J, Forfar C, Becher H, Pillai R. Heart within a heart: contrast 3D echocardiography imaging of a tricuspid valve blood cyst. *Circulation.* 2004; 110: e324-e325.