

Case Report

A Large Angiosarcoma of the Right Atrium: Anaesthetic Management

MRIDU PABAN NATH, NARESH DHAWAN, SANDEEP CHAUHAN, USHA KIRAN

Department of Cardiothoracic Anaesthesiology, C.N. Centre, AIIMS, New Delhi, India

Key words:

Angiosarcoma, cardiac tumours, cardiopulmonary bypass.

We present the case of a young man diagnosed with a right atrial mass and a large pericardial effusion. The patient had presented in the emergency department with chest pain, shortness of breath, pedal oedema and loss of appetite. A transthoracic echocardiogram showed a bright echodensity in the right atrium with a large pericardial effusion. He was treated for presumed tubercular pericardial effusion. Pericardiocentesis showed a straw-coloured non-tubercular pericardial effusion. Surgical removal of the right atrial tumour was planned with cardiopulmonary bypass support. The tumour could only be partially resected due to large adhesions with the myocardium. The patient suffered a cardiorespiratory arrest in the intensive care unit 3 hours after surgery due to persistent bleeding in the pericardial cavity with refractory hypovolemic shock and could not be revived. The pathological examination performed later revealed a primary cardiac angiosarcoma. The case highlights the initial clinical presentation, current diagnostic modalities, and anaesthetic management options for cardiac angiosarcoma.

Manuscript received:
July 27, 2009;
Accepted:
January 4, 2010.

Address:
Mridu Paban Nath

*H.No-3, Sarvodaya Path
ABC, Guwahati
Assam, India
PIN-781005
e-mail: drmridupaban@yahoo.com*

P rimary cardiac tumours occur rarely, with a reported incidence of 0.03% to 0.05%, and the majority of the tumours are benign.¹ Cardiac myxoma is the most common of these primary cardiac tumours. Malignant tumours of the heart are more likely to be metastatic in origin than a primary neoplasm. Sarcomas are the most common type of primary malignant tumours of the heart. Rhabdomyosarcomas are most common in children and angiosarcomas are more common in adults.² Angiosarcomas most commonly arise from the right atrium.³ Angiosarcomas have a tendency to occur in the third to fifth decade of life and are more common in males. Angiosarcomas are very aggressive, with a high incidence of metastasis at the time of diagnosis. Treatment options for primary angiosarcomas of the heart are limited. The mean survival of these patients with advanced disease is nine months.

Case presentation

A 25-year-old man, who had been asymptomatic 2 months previously, presented to a local practitioner with loss of appetite, breathlessness, abdominal distension and pedal oedema. On chest X-ray there was pericardial effusion with bilateral pleural collection, for which treatment was started with anti-tubercular therapy (ATT). The patient presented at our emergency department with severe chest pain and breathlessness. Urgent chest X-ray and transthoracic echocardiography revealed a large mass in the right atrium (RA), extending up to the right ventricle (RV), with massive pericardial effusion. Pericardiocentesis done under local anaesthesia yielded 1200 ml of straw-coloured fluid. A pericardial pigtail drain was placed for continuous drainage (Figure 1). Cell count of the pericardial fluid revealed predominantly lymphocytes (85%) and poly-

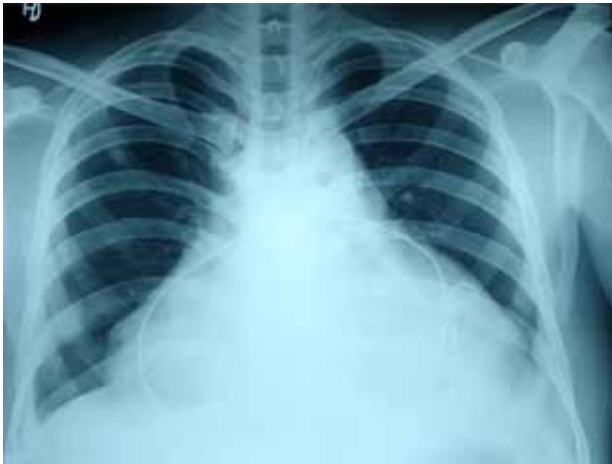

Figure 1. Chest X-ray showing epicardial pigtail drain *in situ*.

morphs (15%), and abundant red blood cells. Bacterial, fungal and acid fast bacilli cultures were negative and cytology was not diagnostic for malignancy. Other routine laboratory tests were normal. The patient was continued on ATT and intravenous broad-spectrum antibiotics were added.

Magnetic resonance imaging of the chest showed a large, broad-based intramural RA mass with pericardial effusion, and bilateral pleural effusion with multiple bilateral lung nodules and multiple haemangiomas in the liver; the differential diagnosis was angiosarcoma or tuberculoma. Repeat transthoracic echocardiography showed pericardial effusion with a large (95 × 62 mm) mass in the RA. The mass was attached to the intra-atrial septum and projected into the RV cavity through the tricuspid valve, producing a gradient of 13 mmHg with diastolic RV outflow tract collapse and normal left ventricular function. The electrocardiogram showed sinus tachycardia, right axis deviation, incomplete right bundle branch block and a suggestion of RA enlargement. With the preoperative provisional diagnosis of angiosarcoma, the patient was scheduled for excision of the RA mass.

The patient was taken to the operating theatre and administered 100% O₂ via face mask while monitoring was started. Pulse oximetry revealed O₂ saturation 95%, blood pressure as recorded by non-invasive blood pressure measurement 110/60 mm Hg, and heart rate 110 beats/min. A right radial artery catheter, a triple lumen central venous catheter (14, 16, 16 gauge, 16 cm length; Arrow International, USA) was inserted percutaneously using 2% lignocaine local anaesthetic via the right femoral vein (to prevent

tumour dislodgement and embolism). The central venous pressure was measured as 20 mmHg.

Induction of anaesthesia was achieved with thiopentone 2mg/kg, fentanyl 5 µg/kg, midazolam 0.02 mg/kg and rocuronium bromide 0.9 mg/kg. There was a fall in blood pressure of about 30 mmHg from baseline during induction, which responded to intravenous fluid (500 ml 6% Voluven). Arterial blood gases following intubation revealed pH 7.32, pO₂ 95 mm Hg, SpO₂ 96%. Oxygen saturation remained at 94-96% until the initiation of cardiopulmonary bypass (CPB).

After induction of general anaesthesia, a multi-plane transoesophageal echocardiography (TOE) probe was placed in the upper oesophageal position. There was minimal pericardial effusion. As the probe was positioned at the mid oesophageal level, a mass (9 × 6 cm) was found to occupy most of the RA with extension to the RV through the tricuspid valve (Figure 2). The mass was heterogeneous in nature, with multiple irregular echo-lucent areas. This large mass significantly decreased the contractility of RA and RV. No mass was seen in other cardiac structures. Anaesthesia was maintained with boluses of fentanyl, pancuronium, midazolam and intermittent sevoflurane inhalation anaesthesia.

Before initiation of CPB, methylprednisolone 30 mg/kg and epsilon amino caproic acid (EACA) 100 mg/kg were given, with additional doses of EACA 100 mg/kg on CPB and after weaning from CPB. Total CPB and cross-clamp times were 125 and 82 minutes, respectively. Intraoperatively, the RA mass was found to have infiltrated the entire wall of the RA, tricuspid valve and RV. Only partial resection of the mass

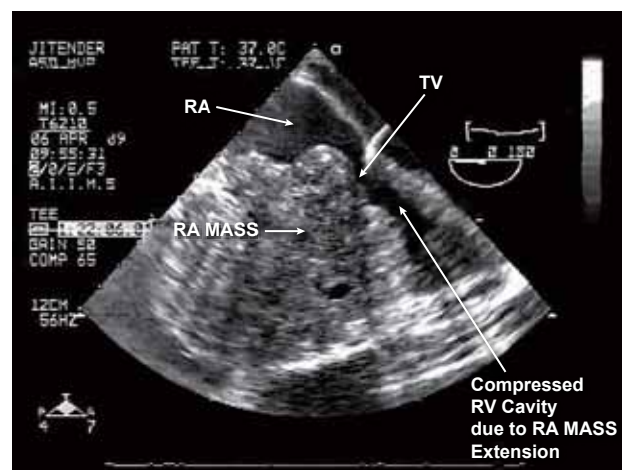


Figure 2. Transoesophageal echocardiography showing a right atrial mass involving the tricuspid valve and right ventricle.

was possible, with partial resection of the tricuspid valve. Massive bleeding was present from the venous sinuses of the cut edge of the RA wall. On post-operative TOE, the RA and RV were partially tumour free, with severe tricuspid regurgitation and severe RV dysfunction. Dobutamine (5-10 µg/kg/min) and sodium nitroprusside (0.5 µg/kg/min) were started at rewarming. Heparin was reversed with protamine and termination of CPB became possible after addition of noradrenaline (0.1 µg/kg/min) infusion to maintain haemodynamics. At the termination of CPB, while the patient was breathing 100% O₂, the pO₂ was 247 mm Hg, with SpO₂ 99%, pCO₂ 30 mmHg, and pH 7.45, while heart rate was 100 beats/min and blood pressure 90-100/50-60 mm Hg. Post CPB red blood cells, platelet concentrate and fresh frozen plasma were started to maintain the RA pressure between 8-10 mmHg and to correct for the continued bleeding into the pericardial cavity.

Postoperatively, the patient was moved to the intensive care unit (ICU) and mechanical ventilation was continued in pressure regulated volume control mode, with full inotropic support. Noradrenaline infusion was increased to 0.2 µg/kg/min in response to haemodynamic fluctuations. In the ICU, the patient developed persistent hypotension (systolic blood pressure 40-50 mmHg) and did not respond to volume and inotropes along with adrenaline 0.2 µg/kg/min, exhibiting diffuse continuous bleeding in the pericardial cavity. The patient had a sudden cardiac arrest after about 3 hours and CPR was started, but the patient did not respond to the treatment. The histopathology report of the tumour mass confirmed the diagnosis of angiosarcoma.

Discussion

Primary tumours of the heart are rare in occurrence and approximately 95% of all primary malignant cardiac tumours are sarcomas. Angiosarcoma is the most common primary cardiac malignant tumour and is an extremely rare, rapidly spreading vascular tumour. It is seen more commonly in males than in females, usually presenting between the third and fifth decade of life.^{4,5} The location of cardiac tumours varies according to the type of tumour.⁶ Malignant tumours are located mainly on the right side of the heart. Ninety percent of angiosarcomas are located in the RA and there is a high incidence of pericardial involvement.⁷ This predilection for the right heart often leads to right-sided congestive heart failure, superior *vena ca-*

va obstruction and pericardial effusion. Presenting symptoms are non-specific and include:

- tumour mass that obstructs intracardiac blood flow or interferes with valve function,
- arrhythmias or pericardial effusion with tamponade,
- tumour embolism,
- systemic or constitutional symptoms.

Other presenting symptoms include haemoptysis secondary to diffuse pulmonary haemorrhage⁸ and clinical features related to metastasis. In our case, the tumour arose from the RA and presented with a large pericardial effusion and symptoms of right heart failure. The atypical clinical presentation, the rareness and the rapidly evolving nature of this malignancy are responsible, at least in part, for the late diagnosis in almost all reported cases.⁹

Owing to the aggressive behaviour of angiosarcomas and the high incidence of metastasis at the time of diagnosis, treatment options are limited. Results of surgical resection alone have been discouraging. According to Herrmann et al,¹⁰ out of 40 patients undergoing surgery for cardiac angiosarcomas, in 16 patients the disease was so advanced that only a biopsy of the tumour, pericardium, or the lung could be performed. The mean survival of these patients with advanced disease was 9 months and depended on whether adjuvant treatment with radiation and/or chemotherapy was given.

Angiosarcomas are traditionally associated with a poor prognosis. Surgical resection with or without adjuvant radiation or chemotherapy is the main treatment modality. Surgical treatment can palliate intracardiac obstruction. Chemotherapy after surgical resection has offered no increased survival benefit when compared to surgery alone.¹⁰ Due to the rarity of this disease, there are no accepted treatment guidelines. Novel therapeutic approaches, including heart transplantation and autotransplantation after "bench surgical resection", have been reported but do not improve long-term survival. A multidisciplinary approach, involving surgery, irradiation, adjuvant chemotherapy, and immunotherapy using interleukin-2, may offer hope for increased survival in selected patients.¹¹

Newer imaging techniques, such as contrast echocardiography and perfusion imaging, may play a valuable role in the better delineation of cardiac tumours. Computed tomography and MRI have excellent diagnostic advantages with regard to tumour delineation and spread. High-resolution cardiac MRI may show effects on valvular and myocardial function. The use

of fluorine-18 fluorodeoxyglucose positron emission imaging adds additional information about tumour metabolism and may aid in early surgical resection.¹²

TOE is a useful imaging modality for the assessment of cardiac masses. High resolution and the proximity between the transducer and heart provide superior evaluation of the tissue characteristics of cardiac masses compared with transthoracic echocardiography.¹³ The availability of the intraoperative TOE examination played other pivotal roles in the management of this patient. The presence of a large atrial mass caused severe tricuspid regurgitation, rendering the central venous pressure measurement unreliable for evaluation of the volume status. TOE was therefore helpful in evaluating the volume status and guiding the fluid administration. A comprehensive TOE examination was valuable before the initiation of surgical intervention, to confirm the location of the tumour and to rule out extension of thrombus into or from the inferior *vena cava*. TOE monitoring during surgical manipulation of the heart also helped in the early detection and diagnosis of tumour fragmentation, dislodgement, or embolisation, which can have fatal consequences and may hinder weaning from CPB. TOE monitoring during surgical removal of the mass also helped to ensure the completeness of excision and to rule out the existence of residual atrial septal defects after surgical closure.¹⁴

Emergency pericardiocentesis is necessary for patients with tamponade to relieve the increased end-diastolic pressure and inadequate ventricular filling. Diagnostic pericardiocentesis with cultures and cytological examination should be performed to establish a definitive diagnosis of malignancy. If the effusion is small, or if the patient's life expectancy is very short, pericardiocentesis may be deferred. The decision to treat a patient is more often based on physiological issues and symptoms rather than on the size or appearance of an effusion. Treatment techniques include percutaneous insertion of pericardial drainage catheters (typically by a subxiphoid route). A surgical procedure or balloon catheter can be used to create a pericardial window to drain the fluid or, infrequently, pericardial stripping can be performed. Systemic chemotherapy and radiotherapy to the pericardium have also been effective in controlling some pericardial effusions.¹⁵ In our patient a pigtail pericardial drainage catheter was also inserted to relieve impending tamponade.

Anaesthetic considerations in patients with RA tumours include hypoxaemia, low cardiac output, pos-

sible right to left shunt, and potential pulmonary emboli. These patients' symptomatology can be exacerbated by changes in body position. There is no gold standard for the anaesthetic management of RA angiosarcoma, the optimal management depends on the judicious administration of anaesthetic drugs that do not cause any cardiac depression.

The hypotension upon induction of anaesthesia was in all probability secondary to the mass obstructing RV filling. Another mechanism of hypotension in these patients might include a decrease in systemic vascular resistance in the presence of a fixed cardiac output, i.e. fixed flow around the tumour. Venodilatation can decrease RA pressure, allowing the atrium to collapse and exacerbate mechanical obstruction of the tricuspid valve by the tumour. Chest compression may displace the tumour mechanically, decreasing RV filling. The administration of norepinephrine can help in resuscitation by increasing systemic vascular resistance.¹⁶ However, in our patient hypotension after induction responded to volume infusion only.

After the induction of general anaesthesia, it is necessary to obtain additional venous access in order to continue with aggressive fluid resuscitation and blood pressure control. Central venous catheterisation in the head and neck was avoided in this case, given the high risk of disturbing the atrial mass and showering septic emboli into the pulmonary circulation. If required, the placement of the jugular catheter can be done under direct echocardiographic visualisation of the mass.¹³ In our patient we choose the femoral venous route. Some authors prefer the antecubital vein, without advancement of the central venous cannula to the full distance, to assess central pressure and deliver medications centrally.¹⁶ A case report exists where a cardiac angiography catheter was passed around the myxoma without incident.¹⁷

Peripheral pedal oedema and right heart failure can be the consequences of pulmonary hypertension due to recurrent tumour embolisation and RV outflow tract obstruction, or due to obstruction of the superior *vena cava*. Cardiac angiosarcomas grow rapidly, usually within the myocardial wall, and are characterised by friability and a tendency towards bleeding. They are, therefore, often associated with cardiac tamponade and recurrent pericardial effusion, multi-septate haemopericardium being the most frequent echocardiographic finding in the few cases reported. Myocardial rupture may occur due to tumoral infiltration and necrosis of the wall.¹⁸ In the present case, RV dysfunction was too far advanced and incomplete

resection of the tumour because of its severe infiltration of the atrial wall, tricuspid valve and RV, with excision of the tricuspid valve, led to more severe dysfunction. This RV dysfunction was further worsened by ongoing bleeding from the residual tumour.

Adequate surgical resection with repair of the cardiac defect by plication of the RV, effectively reapproximating the tricuspid annulus, may result in a good operative outcome.¹⁹ But in our patient the tumour was so extensive that complete resection was not possible.

Treatment of acute right heart failure consists of optimising preload in an attempt to maximise forward flow out of the RV,²⁰ to support the function of the RV and decrease RV afterload. Additionally, inotropic agents such as dobutamine^{21,22} and milrinone²³ may be useful in the support of the failing right heart. In an animal model of acute right heart failure and hypotension, norepinephrine increased RV blood flow and contractility while decreasing pulmonary vascular resistance.^{24,25} Our patient developed severe RV dysfunction following CPB, for which sodium nitroprusside was started to reduce afterload and dobutamine was started to improve the contractility as well as to reduce RV afterload. Norepinephrine was added to wean from CPB and later on in the ICU adrenaline was added when the patient developed refractory hypotension.

In summary, this patient presented the authors with many challenges. The institution of early and aggressive resuscitation measures, coordination of the intraoperative approach with the surgical team, and the use of intraoperative TOE helped contribute to the good management of such cases. But the ultimate outcome depends on the stage of presentation and the local involvement of the tumour.

References

1. Oliver WC, Nuttal GA. Kaplan's Cardiac Anesthesia 5th edition. pp. 765-766.
2. Burke AP, Virmani R. Atlas of tumor pathology. 3rd ed. Washington (DC) 7 Armed Forces Institute of Pathology, 1995.
3. Glancy DL, Morales JB, Roberts WC. Angiosarcoma of the heart. *Am J Cardiol.* 1968; 2: 413-419.
4. Silverman NA. Primary cardiac tumors. *Ann Surg.* 1980; 191: 127-138.
5. Amonkar GP, Deshpande JR. Cardiac angiosarcoma. *Cardiovasc Pathol.* 2006; 15: 57-58.
6. Meng Q, Lai H, Lima J, Tong W, Qian Y, Lai S. Echocardiography and pathologic characteristics of primary cardiac tumors: a study of 149 cases. *Int J Cardiol.* 2002; 84: 69-75.
7. Shapiro LM. Cardiac tumours: diagnosis and management. *Heart.* 2001; 85: 218-222.
8. Adem C, Aubry MC, Tazelaar HD, Myers JL. Metastatic angiosarcoma masquerading as diffuse pulmonary hemorrhage: clinicopathologic analysis of 7 new patients. *Arch Pathol Lab Med.* 2001; 125: 1562-1565.
9. Kontogiorgi M, Exarchos D, Charitos C, et al. Primary right atrium angiosarcoma mimicking pericarditis. *World J Surg Oncol.* 2007; 5: 120.
10. Herrmann MA, Shankerman RA, Edwards WD, Shub C, Schaff HV. Primary cardiac angiosarcoma: a clinicopathologic study of six cases. *J. Thorac Cardiovasc Surg.* 1992; 103: 655-664.
11. Kakizaki S, Takagi H, Hosaka Y. Cardiac angiosarcoma responding to multidisciplinary treatment. *Int J Cardiol.* 1997; 62: 273-275.
12. Freudenberg LS, Rosenbaum SJ, Schulte-Herbrüggen J, et al. Diagnosis of a cardiac angiosarcoma by fluorine-18 fluorodeoxyglucose positron emission tomography. *Eur Radiol.* 2002; 12 Suppl 3: S158-161.
13. Huang J, Bouvette MJ, Zhou J, Dwyer GJ 3rd, Bhopatkar S, Bhatia A. A large angiosarcoma of the right atrium. *Anesth Analg.* 2009; 108: 1755-1757.
14. Riad MG, Parks JD, Murphy PB, Thangathurai D. Infected atrial myxoma presenting with septic shock. *J Cardiothorac Vasc Anesth.* 2005; 19: 508-511.
15. Vaitkus PT, Herrmann HC, LeWinter MM. Treatment of malignant pericardial effusion. *JAMA.* 1994; 272: 59-64.
16. Moritz HA, Azad SS. Right atrial myxoma: case report and anaesthetic considerations. *Can J Anaesth.* 1989; 36: 212-214.
17. Catt K, Denborough MA, Grigg L, Sloman G. Myxoma of the right atrium. *Br Heart J.* 1962; 24: 525-528.
18. Ayyaz Sultan, Ahmed Amour, Sarfraz Khan. Cardiac angiosarcoma presenting with death due to cardiac perforation. *Br J Cardiol.* 2006; 13: 213-215.
19. McFadden PM, Ochsner JL. Atrial replacement and tricuspid valve reconstruction after angiosarcoma resection. *Ann Thorac Surg.* 1997; 64: 1164-1166.
20. Goldstein JA, Barzilai B, Rosamond TL, Eisenberg PR, Jaffe AS. Determinants of hemodynamic compromise with severe right ventricular infarction. *Circulation.* 1990; 82: 359-368.
21. Ferrario M, Poli A, Previtali M, et al. Hemodynamics of volume loading compared with dobutamine in severe right ventricular infarction. *Am J Cardiol.* 1994; 74: 329-333.
22. Meyer RJ, Kern KB, Berg RA, Hilwig RW, Ewy GA. Post-resuscitation right ventricular dysfunction: delineation and treatment with dobutamine. *Resuscitation.* 2002; 55: 187-191.
23. Haraldsson Á, Kieler-Jensen N, Ricksten SE. The additive pulmonary vasodilatory effects of inhaled prostacyclin and inhaled milrinone in postcardiac surgical patients with pulmonary hypertension. *Anesth Analg.* 2001; 93: 1439-1445.
24. Vlahakes GJ, Turley K, Hoffman JI. The pathophysiology of failure in acute right ventricular hypertension: hemodynamic and biochemical correlations. *Circulation.* 1981; 63: 87-95.
25. Salisbury PF. Coronary artery pressure and strength of right ventricular contraction. *Circ Res.* 1955; 3: 633-638.