

Original Research

A Stepwise Algorithm for the Surgical Resection of a Hyper-Nephroma Involving the Inferior *Vena Cava*

HARALABOS PARISSIS¹, VINCENT YOUNG²

¹Department of Cardiothoracic Surgery, Royal Victoria Hospital, Belfast, UK; ²Department of Cardiothoracic Surgery, St James's Hospital, Dublin, Ireland

Key words: Renal tumour involving IVC, renal cell carcinoma growing into the right atrium.

Manuscript received:
July 15, 2010;
Accepted:
September 19, 2010.

Address:
Haralabos Parissis

Department of
Cardiothoracic Surgery
West Wing
Royal Victoria Hospital
Grosvenor Rd
BT12 6BA, Belfast
United Kingdom
e-mail:
hparissis@yahoo.co.uk

Introduction: Techniques for the resection of renal tumours (RT) with extension to the inferior *vena cava* (IVC) are based on the experience of individual units. We attempt to provide a logical approach to the surgical strategies in a stepwise fashion.

Methods: Over 6 years, 9 patients with RT invading the IVC underwent surgery. There were 6 males. The extension was at level IV in 3 and III in 6 cases. Cardiopulmonary bypass was used in 7 and hypothermia and circulatory arrest in 2 patients with level IV disease. The results and an algorithm of the plan of action in relation to the level of extension are presented.

Results: Regarding postoperative morbidity, inotropic support was needed in 5 patients, a prolonged ICU stay in 3 (33.3%), tracheostomy in 1 (11.1%). Methicillin-resistant *Staphylococcus aureus* infection occurred in 1, sepsis in 2, cerebrovascular accident in 1. There were 2 deaths (22.2%). For level I-II disease there was no cardiothoracic involvement. For level III we used cardiopulmonary bypass and control of the cavo-atrial junction. For level IV or suboptimal thrombectomy of level III disease, we used brief periods of circulatory arrest and repair of the cavotomy with a pericardial patch.

Conclusions: Total clearance of the IVC from an adherent tumour is important for prognosis, therefore extensive level III and IV disease presents a surgical challenge. We recommend cardiopulmonary bypass for level III and brief periods of total circulatory arrest for level IV disease.

Involvement of the inferior *vena cava* (IVC) in patients undergoing surgery for renal cell carcinoma (RCC) is rare (4-8%).¹ The overall 5-year survival following successful resection in such a cohort of patients can be as much as 40-50%;^{2,3} therefore, one should not preclude surgical therapy in this group of patients.⁴ A level I tumour involves the renal vein, level II extends inside the IVC but below the liver, a level III tumour involves the IVC and hepatic veins up to the level of the diaphragm, and a level IV tumour extends inside the right side of the heart.^{1,3}

The level of IVC involvement dictates the surgical strategies and mandates the development of a plan of action that should be

safe, reproducible and reliable. A favourable outcome in patients with non-metastatic renal carcinoma and IVC involvement correlates with complete clearance of the IVC from tumour-thrombus. This principle can sometimes only be achieved following an optimal exposure of the infra and supra-hepatic IVC concomitantly with clearance of the IVC-right atrial junction. Furthermore, prevention of tumour disruption and pulmonary embolism has to be considered during thrombectomy and manipulation of the diseased *cava*.

The guidelines regarding the various techniques for the resection of RCC with IVC extension are very scattered in the literature. In this article, by reviewing our

own experience we attempt to provide a systematic approach to the cardiothoracic surgical strategies in a stepwise fashion. The results and an algorithm of the plan of action in relation to the level of extension are presented.

Methods

Over 6 years, 9 patients with RCC invading the IVC underwent surgery. There were 6 males. The extension was at level IV in 3 and level III in 6 cases. Cardiopulmonary bypass (CPB) was used in 7 patients and hypothermia and circulatory arrest in two patients with level IV disease. Abdominal MRI (Figure 1) is useful to determine the extent of IVC involvement with tu-

mour-thrombus. Perioperative transoesophageal echocardiography (TOE, Figure 2) further adds to the planning of the operation because it provides information regarding the amount of adherence, supra-hepatic extension and mobility of the tumour. A multidisciplinary approach is needed. Metastatic disease is a contraindication for surgical therapy and has to be ruled out.

Surgical approach

The initial step consists of mobilisation of the affected kidney with retroperitoneal lymphadenectomy. No irreversible steps are taken until the resection is guaranteed.

For level I-II disease there is usually no cardiothoracic involvement. Limited cavotomy with the brief use of an intermittent caval clamp above and below the lesion is usually adequate. The actual need for cardiac surgical involvement is usually contemplated when the tumour-thrombus involves level III and beyond. We favour a standard midline laparotomy and assessment of resectability of the renal tumour.

Following sternotomy, institution of CPB is achieved using a split venous cannula: superior *vena cava*

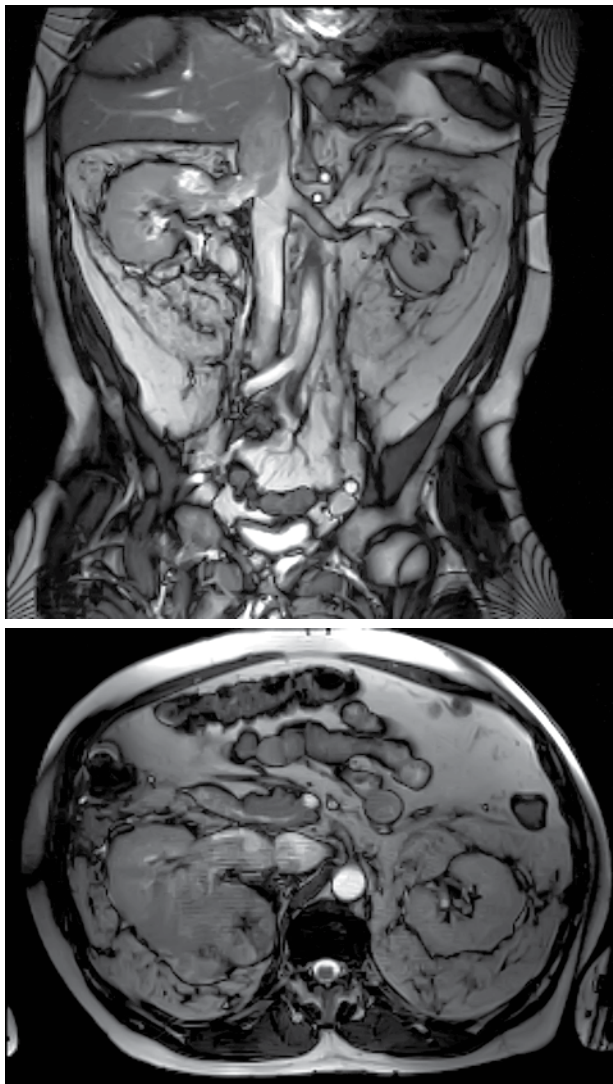


Figure 1. MRI images of a tumour extending from the upper pole of the right kidney into the inferior *vena cava*. The tumour extends above the level of the diaphragm (level IV).

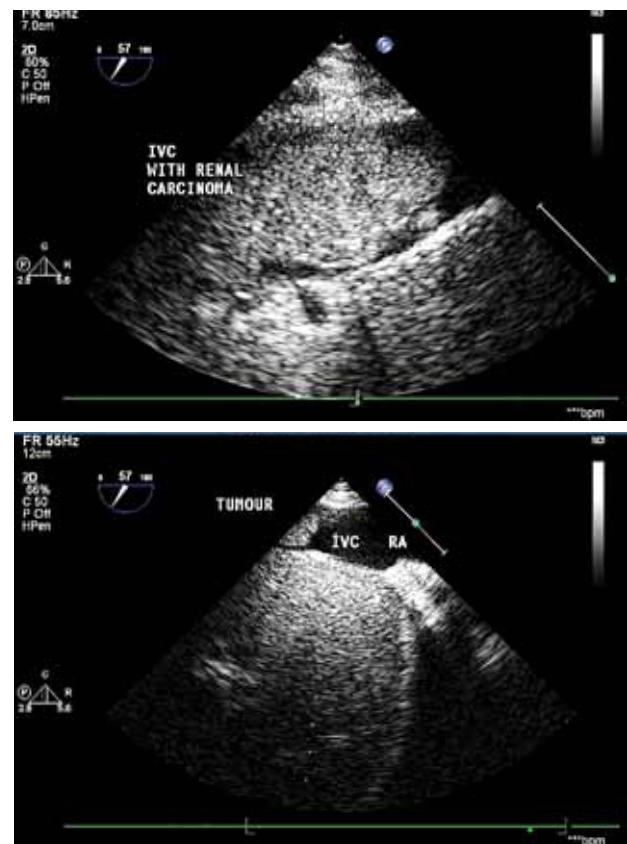


Figure 2. Echo images of a hyper-nephroma extending into the inferior *vena cava*.

and right femoral vein. Control of the cavo-atrial junction is attempted in order to prevent tumour embolisation. That can be achieved by splitting the diaphragm through the central tendon towards the IVC. The *porta hepatitis* is dissected so that blood supply to the liver can be briefly interrupted (Pringle manoeuvre) during cavotomy to further facilitate a bloodless surgical field. Furthermore, by applying a cross-clamp on the sub-diaphragmatic aorta during caval extirpation of the tumour, bloodless operative conditions can be achieved.

Level IV involvement presents a challenge; the disease extends into the right atrium (RA) with various degrees of infiltration and adherence into the wall of the IVC. Under those circumstances the use of total circulatory arrest (TCA) has become a focus

of controversy. The pathophysiological sequelae of the use of TCA are balanced against the risk of a sub-optimal tumour clearance. We, like others, believe that with such extension of the disease the wall of the IVC is infiltrated by tumour and unless a completely bloodless field is instituted, only by blunt dissections, it is impossible to achieve complete clearance.

Therefore, for level IV extension of the tumour, or for suspected “suboptimal thrombectomy” for level III disease, we advocate a brief period of TCA. During the cooling period in an arrested heart, the RA is opened and tumour mobilisation around the ostium of the IVC is carried out. Endarterectomy knives further facilitate optimal extirpation of the tumour by negotiating anatomical planes (Figure 3) of excision. During TCA the

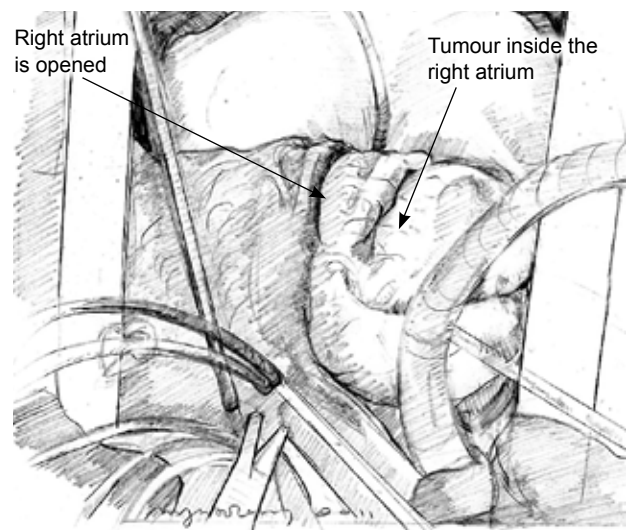
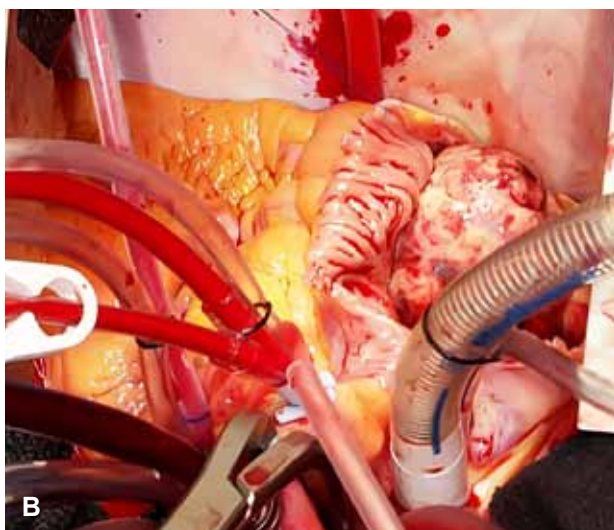
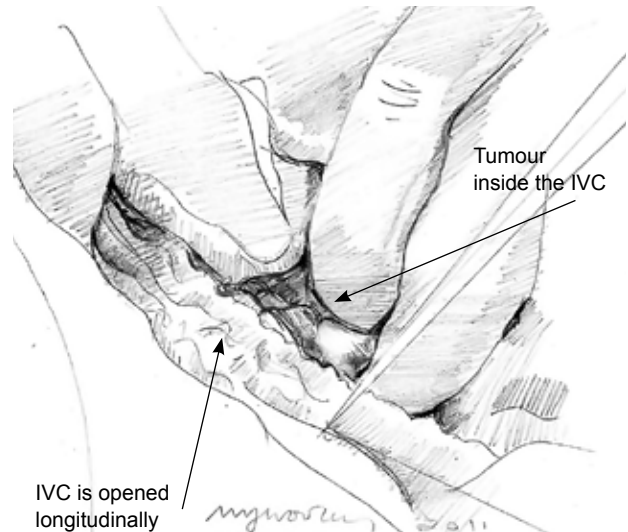
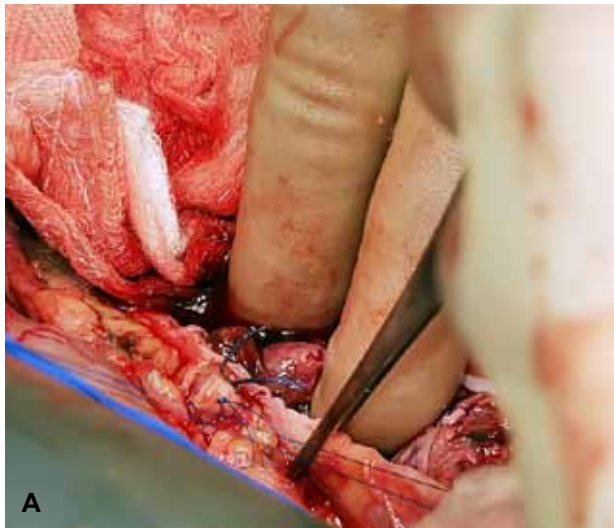


Figure 3. Images taken intraoperatively. Cardiopulmonary bypass with a brief period of circulatory arrest is established in order to facilitate cavotomy and removal of the tumour under direct vision. A. Renal cell carcinoma with tumour extension to the inferior vena cava (IVC). Opening of the IVC and removal of the tumour. B. Opening of the right atrium. The tumour is seen to fill the right atrial cavity.

cava is incised up to 10 cm cephalad in a longitudinal fashion, taking care to include with the specimen the origin of the renal vein, which is usually involved with the tumour. Clearance of the inside of the IVC using sharp and blunt dissections can be then carried out under direct vision. Having mobilised the tumour proximally at the IVC-RA junction, final extraction is usually achieved in continuity with the nephrectomy specimen. Furthermore, tumour embolisation to the lungs is avoided. This way provides a controlled bloodless environment for facilitation of complete tumour clearance. Always, the cavotomy is repaired with the use of a pericardial patch in order to avoid narrowing of the *cava*.

Results

The postoperative morbidity was high, reflecting the compromised preoperative health status of this group of patients. The blood and blood product requirement was high, supportive inotropic treatment was implemented in 5 patients, a prolonged ICU stay was needed in 3 patients (33.3%) and tracheostomy in 1 (11.1%). Methicillin-resistant *Staphylococcus aureus* infection occurred in 1 patient, sepsis in 2, cerebrovascular accident in 1. The perioperative mortality was high (2 patients, 22.2%). Table 3 shows the postoperative outcomes in this patient population.

Discussion

Bissada et al reported that, in 34.6% of patients with RCC and luminal propagation of the tumour into the IVC, metastasis had occurred.⁵ According to the same authors, 11.1% of those patients who underwent surgery were found to have micro-metastasis. The incidence of level III and IV disease was around 40%. Therefore, this pathology is genuinely an uncommon condition; furthermore, it is usually level III and IV of tumour extension that alerts the urologist to seek cardiothoracic expertise. According to Lubahn et al,⁶ in about 50% of patients with renal tumours involving the IVC cardiothoracic involvement is warranted. The overall incidence of extensive IVC disease involving the right atrium, according to Bissada et al⁵ and Hermanek et al,⁷ is around 27.7% of the cases of IVC involvement.

Level I or II is probably the commonest entity, occurring in 60-65% of the cases, and is usually treated by local resection. However, although the involvement of the IVC in renal cancer is generally not a vascular invasion by the malignancy,⁸ one could argue

that, following removal of the thrombus-tumour from the IVC, there is invariably an area that indicates sub-endothelial invasion. In addition, in 12.9% of the patients in the series reported by Bissada et al⁵ the IVC wall was invaded by tumour.

Supra-hepatic extension of the tumour (level III disease) poses a challenge, especially when the tumour is densely adhering to the venal wall or when the hepatic veins contain propagating segments of tumour. Generally, for level III disease some institutions⁹ favour cavotomy without the use of CPB¹⁰ or with the use of venous-venous bypass.^{6,11} Lubahn et al,⁶ in a large series of patients, concluded that the need for invasive cardiovascular procedures increased the risk of perioperative complications. The advantages of using venovenous bypass are the restoration of haemodynamic stability during venal clamping and also the fact that there is no need for systemic heparinisation. However, one could argue that, without CPB and possibly without additional manoeuvres to reduce the venous return (i.e. Pringle manoeuvre), a bloodless field cannot be achieved during cavotomy. Furthermore, the unavoidable haemodynamic instability at that time has another adverse impact: the surgeon is "pushed" to complete the extirpation of the thrombus against the clock. That can possibly lead to debulking of the tumour. It could also lead to dislodgement of tumour material and subsequent pulmonary embolism. Therefore, in addition to CPB for level III disease, we would also favour the approach used by Chowdhury et al,¹² whereby intermittent cross-clamp of the sub-diaphragmatic aorta is applied. This brief manoeuvre would further optimise the conditions for a bloodless surgical field.

In the situation where the IVC is completely occluded by the tumour in level III disease, then probably the patient may tolerate clamping of the IVC at the junction with the RA without significant haemodynamic compromise. Then one could claim that CPB is not necessary. Nevertheless, one should bear in mind the theoretical risk, that debulking of the tumour increases the incidence of local recurrence.

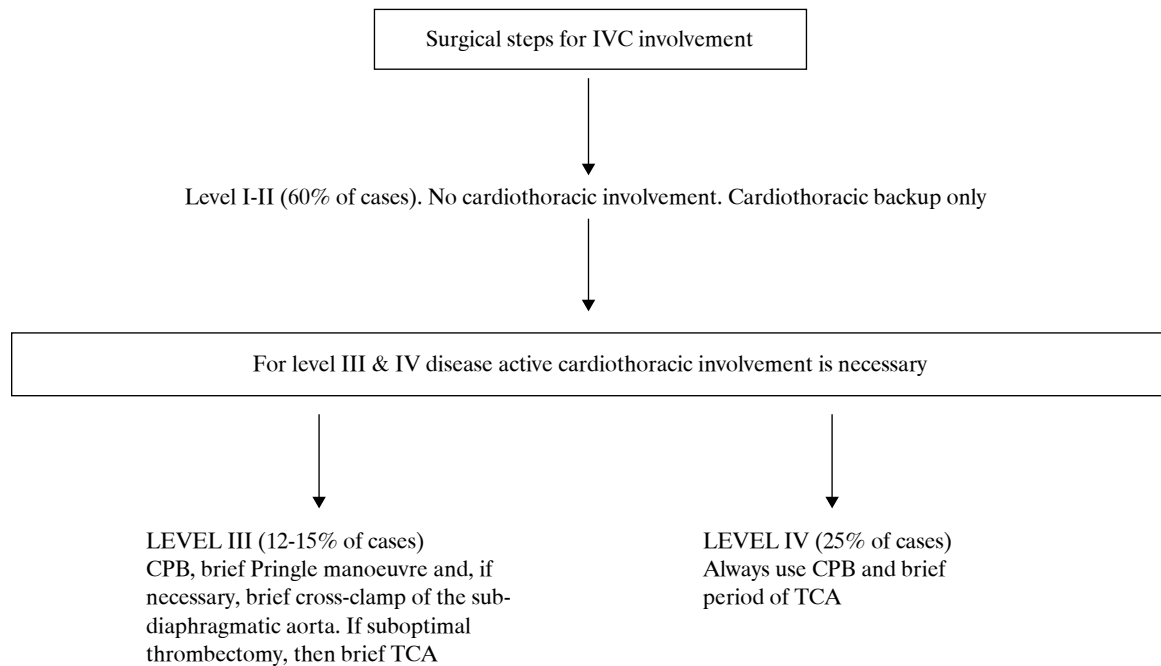
For level IV disease with tumour extension in the RA, controversy still exists regarding the need for TCA. Sosa et al¹³ reported poor survival for patients with level IV disease. Cerwinka et al¹⁴ advocate excision of supra-diaphragmatic tumours off-pump with no TCA. In contrast, Chiappini et al¹⁵ and Mazzola et al¹⁶ claim that the use of TCA provides a safe technique for removing the tumour thrombus in a bloodless field, and has good early and long-term re-

Table 1. Patient demographics and findings.

Sex	Pre-op creatinine (μmol/L)	Height (cm)	Weight (kg)	Euroscore	Operation findings	CPB (min)	Cross-clamp time (min)
M	175	182	85	4	Left kidney tumour, Level IV	111	43
M	132	182	90	7	Left kidney tumour, Level III	51	17
F	108	154	60	7	Right kidney tumour, Level IV	101	37
M	124	178	76	5	Right kidney tumour, Level III	22	0
F	79	166	76	3	Right kidney tumour, Level III	36	0
M	144	183	80	4	Right kidney tumour, Level IV	89	19
M	104	170	106	2	Right kidney tumour, Level III	0	0
F	103	155	72.5	5	Left kidney tumour, Level IV	75	25
M	86	180	66	2	Left kidney tumour, Level III	13	0

CPB – cardiopulmonary bypass.

Table 2. Algorithm for cardiothoracic input according to the level of inferior vena cava (IVC) involvement by tumour.



CPB – cardiopulmonary bypass; TCA – total circulatory arrest.

Table 3. Surgical outcomes.

Hospital stay (days)	Euroscore	Pulmonary complications	Discharge to	Cause of death
19	4	Reintubation/tracheostomy	Another hospital	N/A
55	7	Reintubation & ventilation	Died in hospital	Septicaemia
164	7	None	Another specialty within hospital	Multiple organ failure
24	5	None	Another specialty within hospital	N/A
20	3	None	Another hospital	N/A
19	4	None	Another specialty within hospital	N/A
14	2	None	Home	N/A
24	5	Pleural effusion no drainage	Home	N/A
33	2	Pneumonia	Home	N/A

sults. We, like Schimmer et al,¹⁷ believe that when the tumour thrombus has invaded the caval wall or reaches the right atrium/ventricle then TCA becomes a necessity. We consider that this approach has improved the safety and efficacy of a difficult surgical task by facilitating controlled dissection, providing a bloodless field, and reducing the risk of tumour embolisation.

However, according to Cooper et al,¹⁸ the use of TCA increases the risk of complications up to 40% and also increases perioperative mortality. Furthermore, as per Schimmer et al,¹⁷ the risk of bleeding (at least theoretically) could be exponentially higher because of: 1) the profound hypothermia itself; 2) an extended bypass time as a result of cooling-rewarming; and 3) the fact that these patients have undergone extensive retroperitoneal dissections and have accessory venous collaterals due to the IVC obstruction.

The need for extensive surgery with a relatively good outcome has been outlined by various groups. According to Tanaka et al² and Yazici and associates,¹⁹ the length of tumour extension is not an incremental risk factor for adverse survival. Likewise, Chiappini et al¹⁵ state that tumour extension into the IVC, to whatever degree, is not associated with an adverse prognosis, provided a complete resection is advocated.

Survival is associated with the tumour characteristics (grade of tumour cells) and lymph node involvement.² Throughout the literature, the overall 5-year survival has been reported to be between 40-50% overall.^{3,18,20}

Conclusions

In summary, advance IVC involvement poses a surgical challenge. In this report we have discussed the pros and cons of the various approaches. In principle, for local clearance one should take into consideration:

- a multidisciplinary approach with proper pre-operative evaluation of the extension of the tumour
 - optimal control of haemodynamic conditions during cavotomy
 - ability to visually assess the extent of the tumour invasion
 - avoidance of tumour fragmentation and embolisation, and
 - repair of the IVC without narrowing of the vessel.
- In this paper, although the number of patients re-

ported is small, we have attempted to provide a clear strategy for tackling a difficult and unusual entity.

Acknowledgement

The authors would like to thank Melanie Woolley for the medical illustrations.

References

1. Babu SC, Mianoni T, Shah PM, et al. Malignant renal tumor with extension to the inferior vena cava. *Am J Surg.* 1998; 176: 137-139.
2. Tanaka M, Fujimoto K, Okajima E, Tanaka N, Yoshida K, Hirao Y. Prognostic factors of renal cell carcinoma with extension into inferior vena cava. *Int J Urol.* 2008; 15: 394-398.
3. Belis JA, Levinson ME, Pac WE. Complete radical nephrectomy and vena caval thrombectomy during circulatory arrest. *J Urol.* 2000; 163: 434-436.
4. Skinner DG, Pritchett TR, Lieskovsky G, Boyd SD, Stiles QR. Vena caval involvement by renal cell carcinoma. Surgical resection provides meaningful long-term survival. *Ann Surg.* 1989; 210: 387-392.
5. Bissada NK, Yakout HH, Babanouri A, et al. Long-term experience with management of renal cell carcinoma involving the inferior vena cava. *Urology.* 2003; 61: 89-92.
6. Lubahn JG, Sagalowsky AI, Rosenbaum DH, et al. Contemporary techniques and safety of cardiovascular procedures in the surgical management of renal cell carcinoma with tumor thrombus. *J Thorac Cardiovasc Surg.* 2006; 131: 1289-1295.
7. Hermanek P, Schrott KM. Evaluation of the new tumor, nodes and metastases classification of renal cell carcinoma. *J Urol.* 1990; 144: 238-241.
8. Kalkat M, Abedin A, Rooney S, et al. Renal tumors with cavo-atrial extension: surgical management and outcome. *Interact Cardiovasc Thorac Surg.* 2008; 7: 981-985.
9. Nesbitt JC, Soltero ER, Dinney CP, et al. Surgical management of renal cell carcinoma with inferior vena cava tumor thrombus. *Ann Thorac Surg.* 1997; 63: 1592-1600.
10. Langenburg SE, Blackbourne LH, Sperling JW, et al. Management of renal tumors involving the inferior vena cava. *J Vasc Surg.* 1994; 20: 385-388.
11. Belgrano E, Liguori G, Trombetta C, Siracusano S, Bucci S, Zingone B. Modified pump-driven venous bypass in surgery for renal cell carcinoma (RCC) involving the inferior vena cava (IVC). *World J Urol.* 2002; 20: 56-58.
12. Chowdhury UK, Mishra AK, Seth A, et al. Novel techniques for tumor thrombectomy for renal cell carcinoma with intraatrial tumor thrombus. *Ann Thorac Surg.* 2007; 83: 1731-1736.
13. Sosa RE, Muecke EC, Vaughan ED, McCarron JP. Renal cell carcinoma extending into the inferior vena cava: the prognostic significance of the level of vena caval involvement. *J Urol.* 1984; 132: 1097-1100.
14. Cerwinka WH, Ciancio G, Salerno TA, Soloway MS. Renal cell cancer with invasive atrial tumour thrombus excised off-pump. *Urology.* 2005; 66: 1319.
15. Chiappini B, Savini C, Marinelli G, et al. Cavoatrial tumor thrombus: single-stage surgical approach with profound hypothermia and circulatory arrest, including a review of the literature. *J Thorac Surg.* 2002; 124: 684-688.
16. Mazzola A, Gregorini R, Villani C, et al. Cavoatrial tumor

- thrombectomy with systemic circulatory arrest and antegrade cerebral perfusion. *Ann Thorac Surg.* 2007; 83: 1564-1565.
17. Schimmer C, Hillig F, Riedmiller H, Elert O. Surgical treatment of renal cell carcinoma with intravascular extension. *Interact Cardiovasc Thorac Surg.* 2004; 3: 395-397.
 18. Cooper WA, Duarte IG, Thourani VH, et al. Hypothermic circulatory arrest causes multisystem vascular endothelial dysfunction and apoptosis. *Ann Thorac Surg.* 2000; 69: 696-702; discussion 703.
 19. Yazici S, Inci K, Bilen CY, et al. Renal cell carcinoma with inferior vena cava thrombus: The Hacettepe experience. *Urol Oncol.* 2010; 28: 603-609.
 20. Terakawa T, Miyake H, Takenaka A, Hara I, Fujisawa M. Clinical outcome of surgical management for patients with renal cell carcinoma involving the inferior vena cava. *Int J Urol.* 2007; 14: 781-784.