

## Cardiac Imaging

# Fungal Endocarditis of the Superior *Vena Cava*: The Role of Transesophageal Echocardiography

ILIAS K. KARABINOS, MARIA KOKLADI, DEMOSTHENES KATRITSIS

Cardiology Dept., Euroclinic of Athens, Greece

**Key words:** Fungal endocarditis, superior vena cava, echocardiography, kidney transplantation, transvenous catheter.

*Manuscript received:*  
November 29, 2009;  
*Accepted:*  
April 16, 2010.

*Address:*  
Ilias K Karabinos

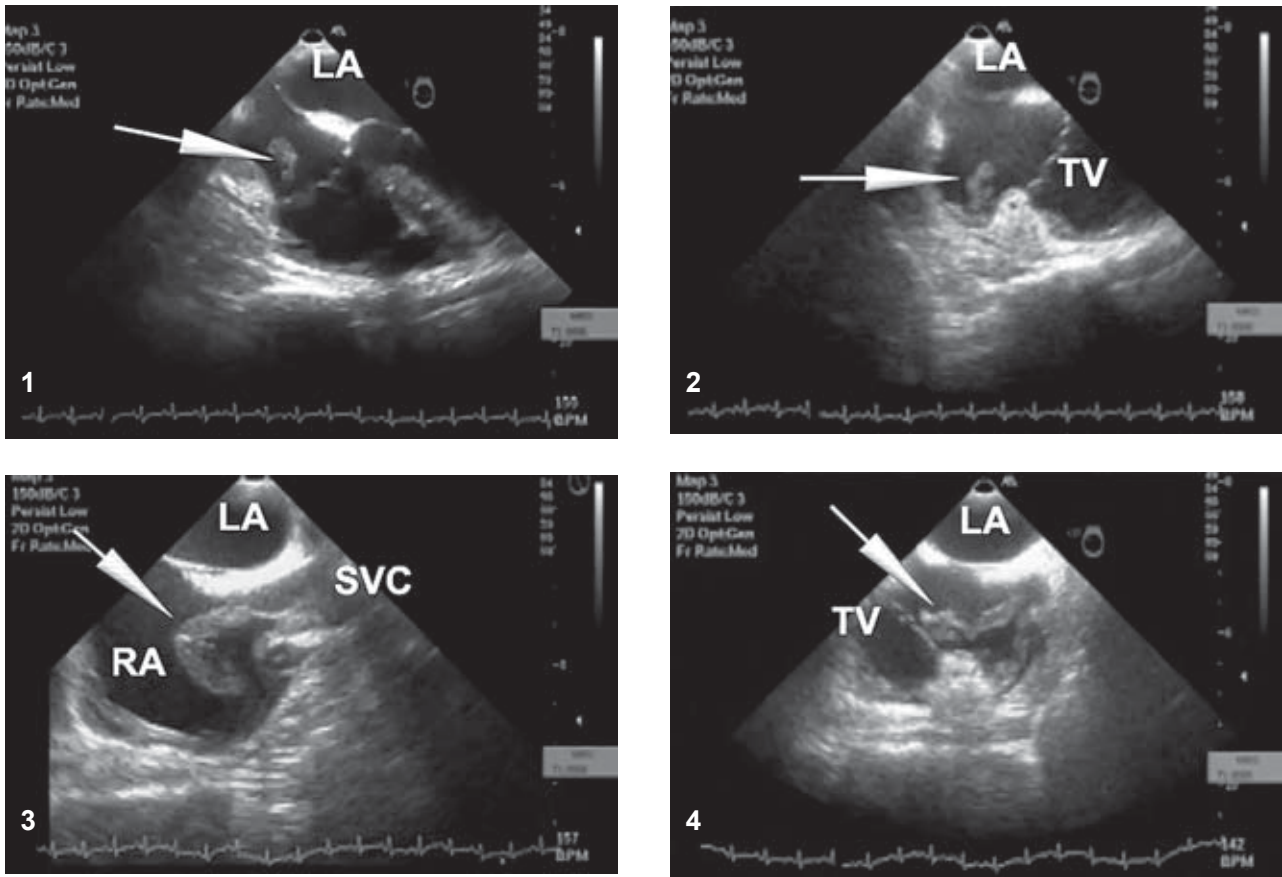
17 Solomou St.  
111 47 Galatsi  
Athens Greece  
e-mail: [ilias.karabinos@lycos.com](mailto:ilias.karabinos@lycos.com)

A 20-year old male with kidney transplantation was diagnosed as having focal segmented glomerulosclerosis 7 months after the transplantation. He was on standard immunosuppressive medication and adjunctive therapy with plasmapheresis was recommended. A transvenous catheter was inserted into his right subclavian vein, and was changed every 7-8 days. The patient was doing well, but one month after cessation of plasmapheresis he became pyrexial, with recorded temperature up to 40° C and concomitant heavy sweating. Although transthoracic echocardiography was inconclusive, the suspicion was raised of a small mobile mass on the posterior wall of the right atrium. Thus, five days after the onset of fever, the patient was admitted to our hospital for transesophageal echocardiography.

Transesophageal echocardiography in the 4-chamber view disclosed a small mobile mass (Figures 1 & 2, arrow) on the free wall of the right atrium close to the tricuspid annulus. However, in the next mid-esophageal bicaval view (110°) we detected a long (>4.7 cm), elongated mobile mass, originating from the outflow of the superior vena cava, protruding into the right atrium (Figure 3, arrow) and approaching the tricuspid valve (Figure 4, arrow). Consecutive blood cultures were

found to be positive for *Candida albicans*. The patient was diagnosed as suffering from catheter-related fungal endocarditis and administration of intravenous amphotericin B was commenced. However, due to the large size of the vegetation, surgical removal of the lesion was deemed necessary. The pathologic examination confirmed the diagnosis of a fungal vegetation caused by *C. albicans*.

Intravascular catheter-related infections are a major cause of morbidity and mortality.<sup>1</sup> *C. albicans* is a recognized cause of catheter-related bloodstream infection.<sup>2</sup> For management of fungemia from an intravascular catheter, decisions regarding therapeutic approaches should be based on the severity of the patient's illness, and the presence of complications, such as endocarditis.<sup>3</sup> In the case presented here, the lesion in the superior vena cava and the involvement of the endocardium were identified only by transesophageal echocardiography. Conventional echocardiography was not sufficient to properly assess the dimensions and extent of the vegetation. Transesophageal echocardiography has proven efficacy in diagnosing catheter-related infections and guiding individual therapeutic strategies and should be considered a standard diagnostic procedure in this setting.



**Figures 1-4.** For descriptions see text. LA – left atrium; RA – right atrium; SVC – superior *vena cava*; TV – tricuspid annulus.

## References

1. Raad I, Hanna H, Maki D. Intravascular catheter-related infections: advances in diagnosis, prevention, and management. *Lancet Infect Dis.* 2007; 7: 645-657.
2. Mermel LA, Farr BM, Sherertz RJ, et al. Guidelines for the management of intravascular catheter-related infections. *Clin Infect Dis.* 2001; 32: 1249-1272.
3. Rubinstein E, Lang R. Fungal endocarditis. *Eur Heart J.* 1995; 16 (Suppl B): 84-89.