

## Case Report

## Radial Artery Angioplasty After Perforation During Diagnostic Cardiac Catheterisation

IOANNIS MAMARELIS<sup>1</sup>, IOANNIS KANTOUNAKIS<sup>2</sup>, PANAGIOTIS KOTILEAS<sup>1</sup>, PANAGIOTIS TAKOS<sup>1</sup>, THEODOROS STEFANOPOULOS<sup>2</sup>

<sup>1</sup>Haemodynamic Laboratory, Cardiology Department, <sup>2</sup>Department of Invasive Radiology, 401 General Army Hospital, Athens, Greece

**Key words: Trans-radial access, complications of trans-radial cardiac catheterisation, percutaneous radial artery angioplasty.**

The use of the radial artery as an access site for diagnostic and interventional cardiac procedures has been extensively developed in recent years as a result of reduced complications at puncture site, reduced costs and the improvement in the patients' quality of life. The complications of trans-radial procedures are rarely major and very rarely life threatening — a key benefit of the radial approach. We describe the case of a patient who underwent percutaneous radial artery angioplasty, because of perforation caused during diagnostic cardiac catheterisation, in order to complete the catheterisation procedure before the patient proceeded to endovascular treatment of a sub-renal abdominal aortic aneurysm.

**R**adial artery access for diagnostic and invasive purposes<sup>1,2</sup> has started to become popular in recent years. This route offers many advantages:<sup>3</sup> it causes significantly fewer access-site complications, allows faster patient mobilisation, and is better tolerated by the patients.

The radial technique requires particular dexterity and has an appreciable learning curve,<sup>4</sup> which explains its limited adoption in clinical practice.<sup>5</sup> However, its associated complications — radial artery spasm, failure of arterial puncture, vascular anomalies, and failure to reach the ascending aorta — are obstacles that can be overcome with appropriate training,<sup>6</sup> with the result that a similar success rate to that of femoral access can be achieved, together with fewer haemorrhagic and vascular complications.<sup>7,8</sup>

### Case presentation

A man aged 75 years, with known risk factors for coronary artery disease (hypercholesterolaemia, hypertension, obesity)

was admitted for a coronary angiographic examination because of stable angina, prior to endovascular treatment of a sub-renal aneurysm in the abdominal aorta. The decision was taken to proceed with cardiac catheterisation via the radial artery, taking into account the patient's extreme obesity as well as the pressing need to avoid puncturing the femoral arteries because of the scheduled endovascular aorto-bi-iliac stent graft implantation for the sub-renal abdominal aneurysm.

The patient first underwent an Allen test and oximetry analysis to confirm double perfusion of the palmar arch. Puncture of the right radial artery was performed under local anaesthesia with 1 ml xylocaine 2% subcutaneously, using a 20 G paracentesis needle and a 0.022" hydrophilic guidewire. A short (10 cm) hydrophilic 6 F sheath (Terumo Radifocus Introducer II, Japan) was placed in the right radial artery and a "drug cocktail" consisting of 5000 IU standard heparin, 5 mg verapamil, and 200 µg nitroglycerine was administered intra-arterially.

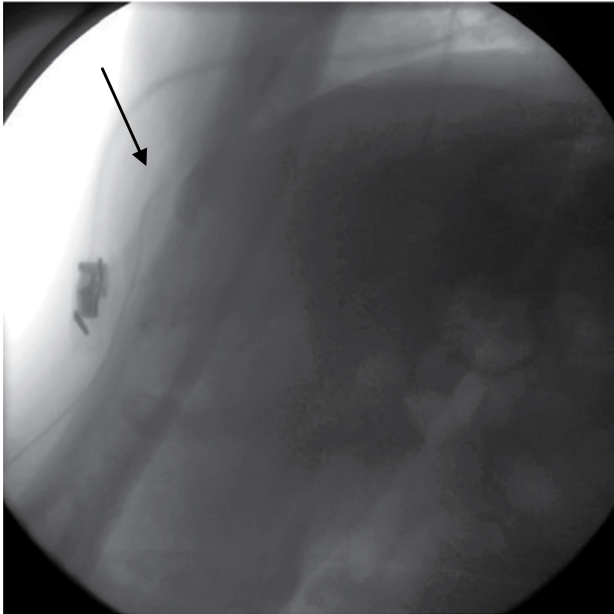
*Manuscript received:*  
March 7, 2009;  
*Accepted:*  
December 22, 2009.

*Address:*  
Ioannis Mamarelis

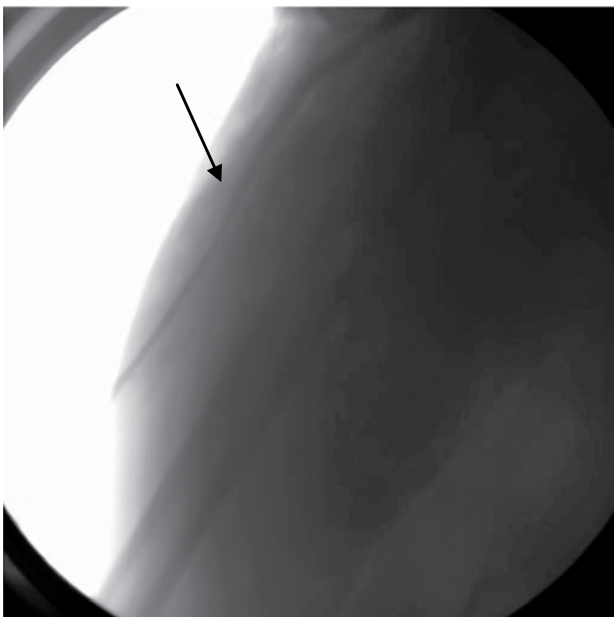
25A Kamelias St.  
153 44 Gerakas  
Attica, Greece  
e-mail: [imamarelis@gmail.com](mailto:imamarelis@gmail.com)

After sheath placement in the right radial artery, a 0.035" J-tipped guidewire was advanced to the middle of the forearm, where resistance was encountered (Figure 1) due to tortuosity and accompanying arterial spasm (Figure 2).

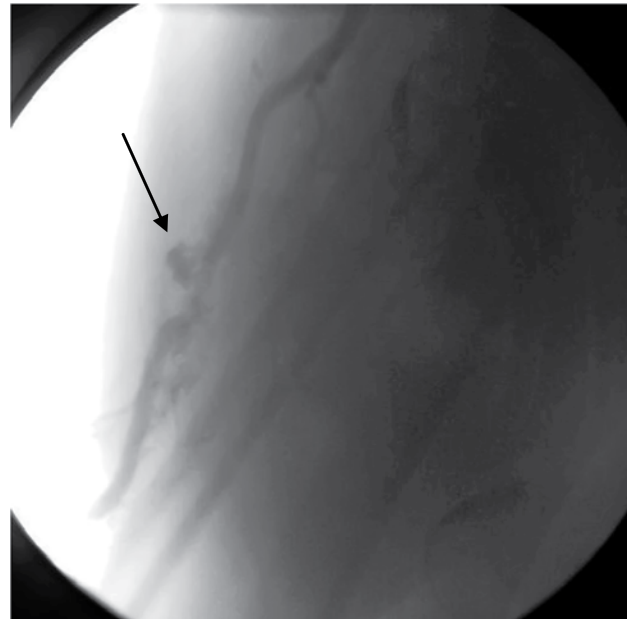
A 6 F Multipurpose catheter (MP1) was inserted through the sheath, and angiography of the forearm revealed a radial artery perforation at a point of extreme tortuosity, together with leaking of contrast medium into the forearm (Figure 3).



**Figure 1.** Difficulty advancing the guiding catheter (arrow).



**Figure 2.** Right radial artery spasm (arrow).




**Figure 3.** Injury (arrow) to the radial artery with leakage of contrast medium (tuft).

The therapeutic options for treating the radial artery perforation were either to stop the catheterisation and apply external pressure to the forearm, in order to avoid compartment syndrome and pseudoaneurysm, or to attempt invasive treatment with percutaneous angioplasty.

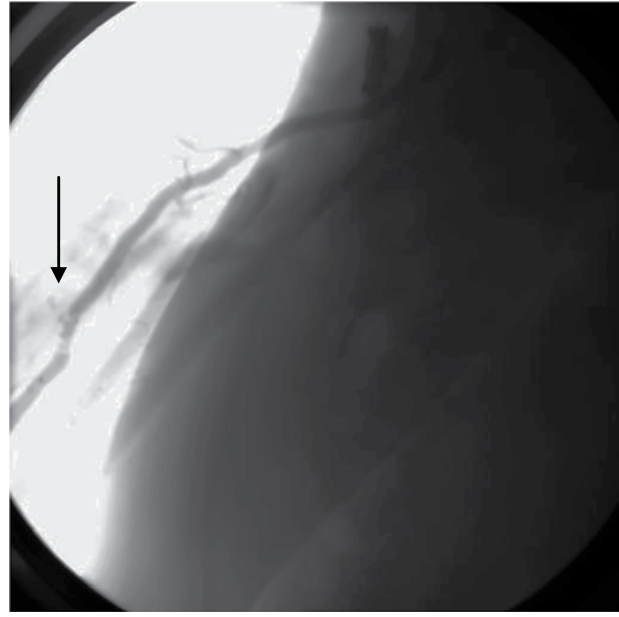
The need for the patient to undergo endovascular stent graft implantation for the sub-renal abdominal aneurysm, where knowledge of the coronary anatomy would be required, led us to decide to continue our attempt at coronary artery imaging after first correcting the radial artery rupture in an invasive manner.

Our invasive strategy included an attempt to seal the radial artery perforation using prolonged inflations of an angioplasty balloon, while trying, if feasible, to avoid the deployment of a covered stent because of the risk of future restenosis (a consequence of endothelial hyperplasia at the stent margins), or stent fracture and thrombosis from the muscle masses of the forearm, taking into account the wide ranging movements of supination and pronation usually made by that limb.

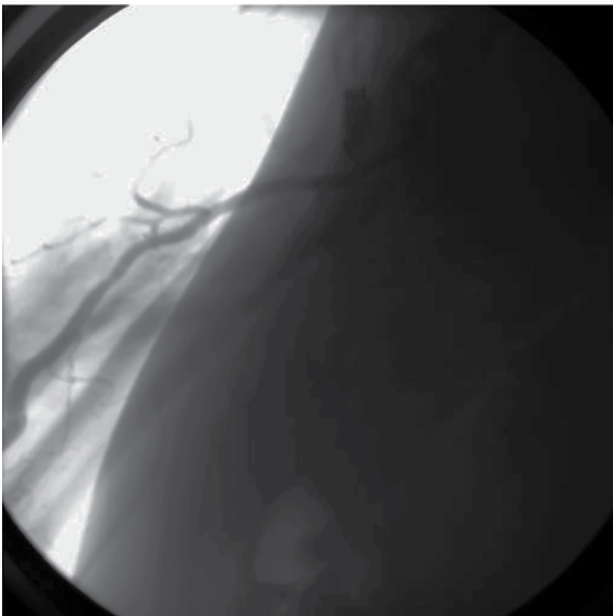
A 0.014" Floppy guidewire was advanced to the middle of the forearm and prolonged inflations of a 3.5 × 15 mm angioplasty balloon were performed at the site of the rupture (Figures 4 & 5). The pictures taken immediately after the radial artery angioplasty revealed full patency of the lumen, without any further extravasation of contrast medium (Figure 6).



**Figure 4.** Placement of a 3.5 × 15 mm angioplasty balloon (arrow) at the point of injury.



**Figure 5.** Partial restoration with leakage (arrow) of a small amount of contrast medium from the point of injury.



**Figure 6.** Full restoration of flow with no leakage of contrast medium during imaging of the radial artery.

Subsequently, the angioplasty balloon was advanced along the guidewire in order to help the guiding catheter ascend to the aorta so that the coronary angiography could be performed. This revealed atherosclerotic coronary vessels without any critical stenosis that would need invasive treatment.

Before the diagnostic catheter was withdrawn, a

final angiographic check was made of the radial artery, which confirmed full flow without extravasation and the presence of only a limited intramuscular haematoma in the forearm.

The arterial sheath was removed from the radial artery as soon as the angioplasty had been completed and a TR Band compression system (Terumo, Japan) was applied to the puncture site for 3 hours.

The patient's clinical course was uneventful and the next day he successfully underwent aorto-bi-iliac stent graft implantation in the abdominal aorta.

## Discussion

Radial artery access is an attractive alternative method for diagnostic cardiac catheterisation,<sup>9</sup> since it offers the patient the opportunity to undergo extra-cardiac surgery even on the same day as the catheterisation. Radial artery access is also an interesting option<sup>10</sup> in a large number of patients who are to undergo angioplasty, provided the operators are experienced, state-of-the-art materials are available, and there is a willingness to crossover to a femoral approach should the radial option fail.

The radial artery is not an end artery; it is easily compressible,<sup>11</sup> with the result that haemorrhage can be easily controlled and haemorrhagic complications are significantly reduced.<sup>12</sup> This makes the radial artery the method of choice today<sup>13</sup> for both diagnos-

tic catheterisation and percutaneous angioplasty, especially for acute coronary syndromes,<sup>14</sup> the elderly (>70 years),<sup>15</sup> women, and obese patients who have a high risk of peripheral complications from femoral access.<sup>16</sup> In addition, there are no main nerves or veins close to the radial artery, which reduces the risk of damage to such structures that could lead to neuropathies or arteriovenous fistulas. Post-procedure bed rest is not necessary, thus allowing the patient immediate mobilisation, greater comfort, and rapid discharge from the hospital.<sup>17</sup> All those things entail an improvement in the patient's quality of life, while the feeling of loss of privacy from the exposure and instrumentation in the very personal groin area is avoided. In addition, the patient can return more rapidly to personal and working activities, which results in a reduction in hospital costs of 10-15%.

Nevertheless, the penetration of the method into clinical practice has been limited, with 30% of the catheterisations performed in Europe using the radial artery, compared with only 10% in the USA. This is mainly due to the longer learning curve required for radial, as compared to femoral artery access, combined with the complications of arterial spasm, failure of arterial puncture, vascular anomalies, and inability to reach the ascending aorta.<sup>18</sup>

In the protocol that has been applied for the last year in our hospital for systematic diagnostic catheterisation and angioplasty using the radial artery, the percentage of successful procedures performed via the radial artery was comparable with that of femoral access (97% versus 99%, respectively), while there was a striking and significant increase from the first half of the period to the second in the number of cases where radial artery access was preferred for the coronary angiography or angioplasty procedure (from 35% in the first 6 months to 47% in the second).<sup>19</sup>

Radial artery perforation is one of the vascular complications<sup>20</sup> of the radial technique, which also include dissection, haematoma, haemorrhage, pseudoaneurysm,<sup>21</sup> arteriovenous fistulae, and upper extremity ischaemia. These complications are few, occur only rarely (<0.06%),<sup>22</sup> but can prevent the continuation of the catheterisation. The most likely cause of the injury to the radial artery in our case was the advancement of the guidewire through a tortuous section of vessel in combination with arterial spasm.

Retrograde radial angiography with the infusion of a tiny quantity of contrast medium (3 ml) can assist in the detection of vascular anomalies<sup>23</sup> in patients with unsuitable anatomy, and generally provides the

invasive physician with the opportunity to organise a strategic plan whereby the anomaly can be bypassed, or the access route can be changed promptly with a view to avoiding vascular complications and thus gaining valuable time.

Revascularisation of long sections of peripheral arterial occlusions, aneurysms, and vascular complications, such as dissection, perforation, pseudoaneurysm, and arteriovenous fistulae, can be treated successfully using covered stents,<sup>24</sup> although the long-term results have not yet been clearly elucidated, especially for small-sized arteries.<sup>25</sup>

In the case reported here we decided not to abandon the procedure, but to continue the cardiac catheterisation and to repair the radial artery rupture with angioplasty alone, without deploying a covered stent. Eschewing the stent avoided the risk of future complications from covered stent implantation, such as restenosis, stent fracture and thrombosis, while at the same time keeping down the cost of the procedure. This strategy was, we believe, safe, and allowed the completion of the diagnostic imaging of the coronary arteries, with the possibility of coronary angioplasty had that become necessary.

## References

1. Louvard Y, Krol M, Pezzano M, et al. Feasibility of routine transradial coronary angiography: a single operator's experience. *J Invasive Cardiol.* 1999; 11: 543-548.
2. Mann T. The radial approach for coronary angiography and stenting. *Heart.* 1999; 82: 411-412.
3. Lim VYT, Chan CNS, Kwok V, Mak KH, Koh TH. Transradial access for coronary angiography and angioplasty: a novel approach. *Singapore Med J.* 2003; 44: 563-569.
4. Louvard Y, Lefevre T, Morice MC. Radial approach: what about the learning curve? *Cathet Cardiovasc Diagn.* 1997; 42: 467-468.
5. Vefali V, Arslan U. Our experience with transradial approach for coronary angiography. *Turk Kardiyol Dern Ars.* 2008; 36:163-167.
6. Eccleshall SC, Banks M, Carroll R, Jaumdally R, Fraser D, Nolan J. Implementation of a diagnostic and interventional transradial programme: resource and organisational implications. *Heart.* 2003; 89: 561-562.
7. Agostoni P, Biondi-Zoccai GGL, de Benedictis ML, et al. Radial versus femoral approach for percutaneous coronary diagnostic and interventional procedures; Systematic overview and meta-analysis of randomized trials. *J Am Coll Cardiol.* 2004; 44: 349-356.
8. Pristipino C, Trani C, Nazzaro MS, et al. Major improvement of percutaneous cardiovascular procedure outcomes with radial artery catheterisation: results from the PREVAIL study. *Heart.* 2009; 95: 476-482.
9. Tse TS, Lam KKH, Tsui KL, et al. Feasibility of transradial coronary angiography and angioplasty in Chinese patients.

- Hong Kong Med J. 2006; 12: 108-114.
10. Gilchrist IC, French JK. Radial access for cardiac catheterization is not radical. *Am Heart J.* 2008; 156: 805-807.
  11. Rihal CS, Holmes DR. Transradial cardiac catheterization: is femoral access obsolete? *Am Heart J.* 1999; 138: 392-393.
  12. Hamon M, Coutance G. Transradial intervention for minimizing bleeding complications in percutaneous coronary intervention. *Am J Cardiol.* 2009; 104: 55C-59C.
  13. Hamon M, Nolan J. Should radial artery access be the "gold standard" for PCI? *Heart.* 2008; 94: 1530-1532.
  14. Brasselet C, Tassan S, Nazeyrollas P, Hamon M, Metz D. Randomised comparison of femoral versus radial approach for percutaneous coronary intervention using abciximab in acute myocardial infarction: results of the FARMI trial. *Heart.* 2007; 93: 1556-1561.
  15. Bagur R, Bertrand OF, Rodés-Cabau J, et al. Comparison of outcomes in patients > or =70 years versus <70 years after transradial coronary stenting with maximal antiplatelet therapy for acute coronary syndrome. *Am J Cardiol.* 2009; 104: 624-629.
  16. Eichhöfer J, Horlick E, Ivanov J, et al. Decreased complication rates using the transradial compared to the transfemoral approach in percutaneous coronary intervention in the era of routine stenting and glycoprotein platelet IIb/IIIa inhibitor use: a large single-center experience. *Am Heart J.* 2008; 156: 864-870.
  17. Jabara R, Gadesam R, Pendyala L, et al. Ambulatory discharge after transradial coronary intervention: Preliminary US single-center experience (Same-day TransRadial Intervention and Discharge Evaluation, the STRIDE Study). *Am Heart J.* 2008; 156: 1141-1146.
  18. Lefevre T, Louvard Y. Description and management of difficult anatomy encountered during transradial intervention. In Hamon M, McFadden E, editors. *Transradial approach for cardiovascular interventions.* 1st ed. Carpiquet, France: Europa Stethoscope Media; 2003. 203. p. 241-254.
  19. Koutoulakis E, Mamarelis I, Kotileas P, Takos P. Transradial approach for coronary angiography and percutaneous angioplasty. One center experience of the feasibility, the efficacy and safety of the technique. *Hellenic J Cardiol.* 2009; 50: Supplement.
  20. Gunasekaran S, Cherukupalli R. Radial artery perforation and its management during PCI. *J Invasive Cardiol.* 2009; 21: E24-26.
  21. Williams PD, Eccleshall S. Delayed presentation of radial artery pseudoaneurysm secondary to catheter trauma during percutaneous coronary intervention. *Heart.* 2009; 95: 1084.
  22. Harcombe A. Complications of transradial procedures. *Br J Cardiol.* 2002; 9 (Supplement 2); 10-11.
  23. Lo TS, Nolan J, Fountzopoulos E, et al. Radial artery anomaly and its influence on transradial coronary procedural outcome. *Heart.* 2009; 95: 410-415.
  24. Mauro M, Murphy K, Thomson K, Vendrux A, Zollikofer C. Stents; Peripheral Stent Grafts. In: *Image Guided Interventions, Volume I.* Saunders and Elsevier; 2008. p. 100-103.
  25. Kaufman JA, Lee MJ. *Vascular Interventions.* In: *Vascular and Interventional Radiology: The Requisites.* Mosby Elsevier; 2004. p. 94-96.