

## Case Report

## The “Crush” Technique as a Therapeutic Approach for a Bifurcation Lesion in a Saphenous Venous Graft

IOANNIS KARALIS, GEORGE KOCHIADAKIS, NIKOLAOS IGOUMENIDIS, EMMANUEL SKALIDIS, STAVROS CHRYSOSTOMAKIS, PANOS VARDAS

*Cardiology Department, University Hospital of Heraklion, Crete, Greece*

Key words:  
**Angioplasty, transluminal, percutaneous coronary, stents**

Bifurcation lesions of native coronary arteries are common in daily practice and different strategies for percutaneous coronary intervention have been suggested for their treatment. The “crush” technique, with the use of drug-eluting stents in both the main and the side branch, is a relatively simple procedure that ensures complete lesion coverage, even for bifurcations that have extensive disease within the side branch. We present the case of a bifurcation lesion in a Y-shaped saphenous venous graft in a patient who had previously undergone coronary artery bypass graft surgery. The literature lacks reports regarding the management of such patients. Implementation of the “crush” technique in the specific case resulted in a satisfactory angiographic and long-term clinical outcome.

*Manuscript received:*  
November 5, 2009;  
*Accepted:*  
June 3, 2010.

*Address:*  
Panos E. Vardas

*Cardiology Dept.,  
Heraklion University  
Hospital  
P.O. Box 1352  
711 10 Heraklion  
Crete, Greece  
e-mail: [cardio@med.uoc.gr](mailto:cardio@med.uoc.gr)*

**L**ong-term freedom from angina and ischaemic events following coronary artery bypass graft (CABG) surgery with the use of saphenous venous grafts (SVGs) is limited by the development of graft stenosis. The therapeutic option of percutaneous coronary interventions (PCIs) in these patients is challenging and is associated with high complication rates. This is particularly true in cases where surgeons use more sophisticated techniques to accomplish a satisfactory result, such as the formation of a Y-shaped venous graft to supply two branches of the native coronary tree.

Dealing with bifurcation lesions is common in native coronary arteries, making up 15-20% of PCI cases performed.<sup>1</sup> The anatomical patterns of the stenosis, however, together with variations in the diameter of each of the branches and the angle at which the side branch originates from the main branch, have traditionally caused this type of lesion to be associated with lower

periprocedural success rates, higher rates of restenosis and an increased risk of side-branch occlusion.<sup>2</sup> Various techniques have been introduced in an attempt to improve outcomes. In 2003, Colombo et al described the “crush” technique of treating bifurcations, with the use of drug-eluting stents, as a relatively simple method that ensures complete coverage of the side branch ostium, aiming to reduce the high rates of side-branch restenosis.<sup>3</sup>

We present the case of a Y-shaped saphenous venous graft bifurcation lesion in a patient with a medical history of CABG operation, treated using the “crush” technique. Our aim was to demonstrate the feasibility of the technique in the setting of a venous graft lesion and to present the immediate angiographic and long-term clinical outcomes of the procedure.

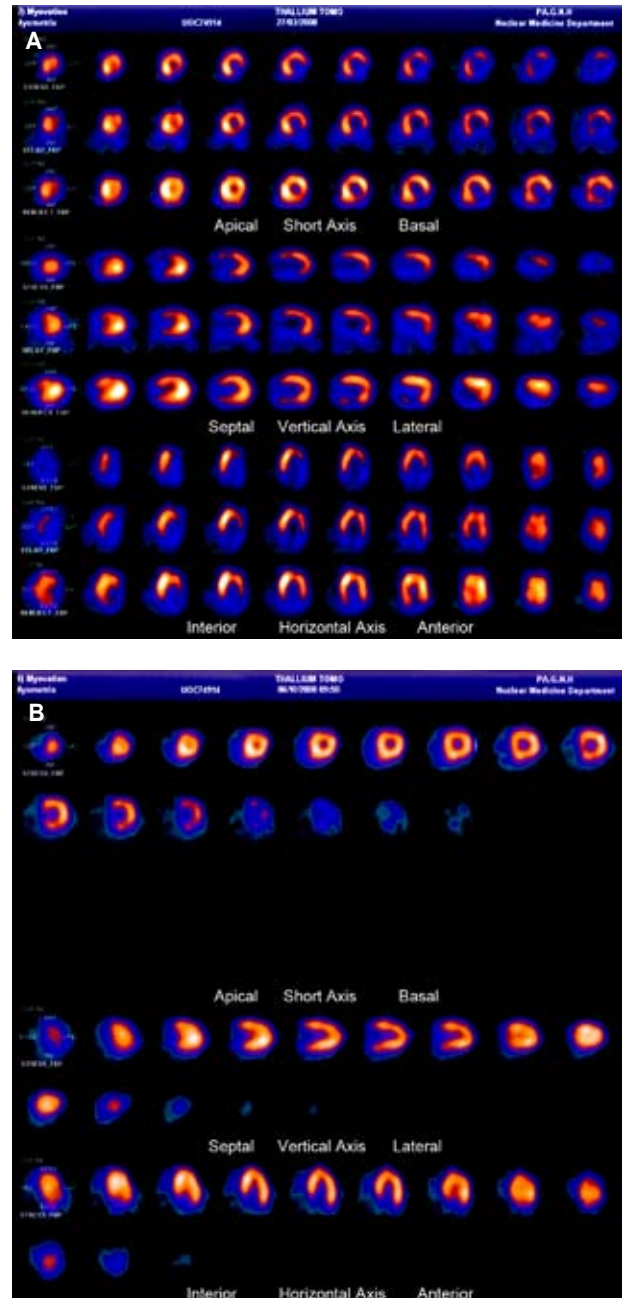
### Case presentation

A 78-year-old male patient, ex-smoker,

with a medical history of hypertension, insulin-treated diabetes, hyperlipidaemia and renal impairment (serum creatinine levels 1.8 mg/dl, estimated creatinine clearance 32.5 ml/min) came to the outpatient clinic of our hospital complaining of gradually worsening exertional dyspnoea over the previous 6 months. He had a known history of coronary artery disease, with lesions involving all three main vessels, and had undergone a CABG operation 10 years before. According to the surgical report, an inverted Y-shaped venous graft was used to supply both the left anterior descending (LAD) and the right coronary artery (RCA). Following the bypass operation, the patient remained quite well, leading an active life, until dyspnoea appeared. The patient was initially referred for a myocardial perfusion scan, which demonstrated reversible ischaemia in the inferior and lateral walls (Figure 1A). Coronary angiography confirmed the presence of heavily diseased native coronary arteries (Figures 2A, 2B) and revealed a tight lesion at the bifurcation site of the Y-shaped venous graft, causing an 80-90% stenosis of the lumen (Figure 2C, 2D).

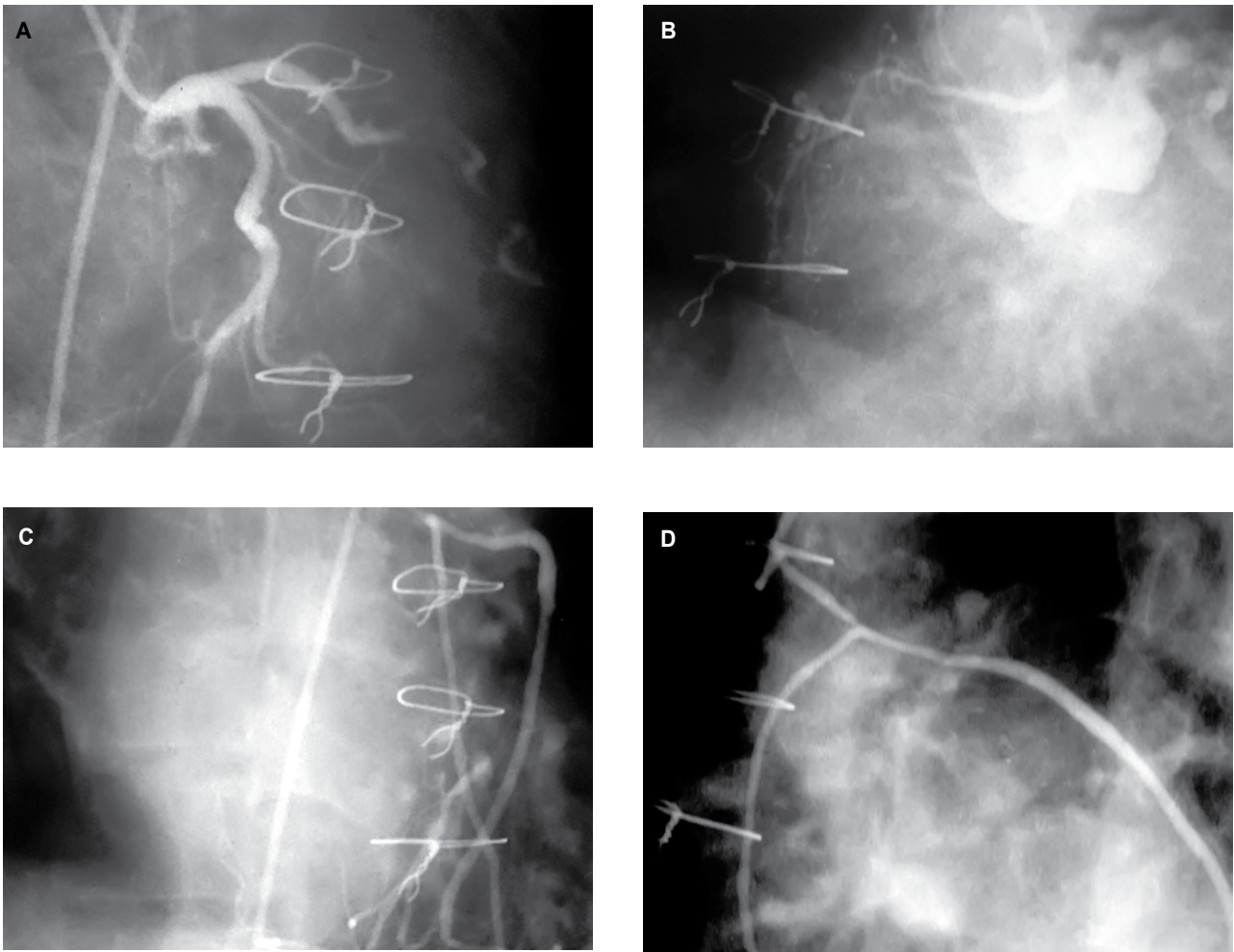
The decision was made to treat the lesion of the venous graft as we would treat one in the native coronary arteries. Given the degree of atherosclerosis involving both branches of the Y-shaped venous graft, a stenting technique fully covering the bifurcation segment of the graft was considered as the most appropriate; the “crush” technique, with the use of paclitaxel-eluting stents, was selected. The venous graft branch supplying the LAD was considered as the main branch of the bifurcation while the one supplying the RCA was considered as the side branch. Both branches of the graft were wired using standard balanced middle-weight wires and pre-dilated with 2.5 mm balloons up to 12 atm. Following the “crush” technique described below, a 3.0 × 20 mm paclitaxel-eluting stent was used for the side branch while a 3.5 × 24 mm stent was used for the main branch. The final result was optimised with a final kissing balloon (using 3.0 mm balloons for both the main branch and the side branch; Figure 3), leaving no residual stenosis. Most authors suggest the use of embolic protection devices, or other sophisticated techniques,<sup>4,5</sup> for interventions performed in saphenous venous grafts: however, this option was not available in our catheterisation laboratory when the procedure was performed.

The patient was discharged from the department two days later and was re-evaluated on a routine basis at one and three months. Six months after the procedure he underwent a new perfusion scan (Figure

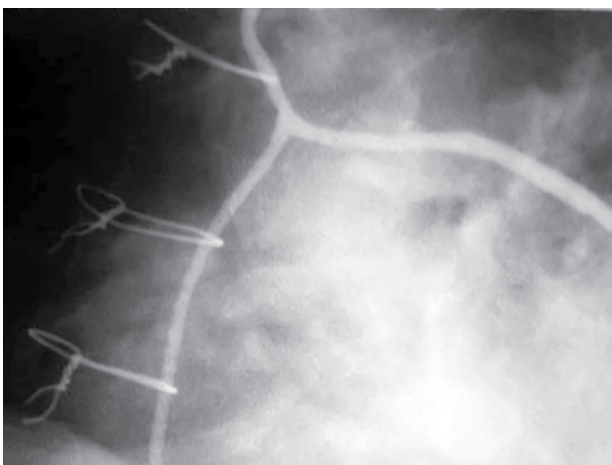


**Figure 1.** Myocardial perfusion scan. A. prior to percutaneous coronary intervention (PCI), demonstrating reversible ischaemia in the inferior and lateral walls; B. follow up, 6 months post PCI.

1B). The patient exercised for 6 minutes and 45 seconds, achieving a maximal exercise workload, with no symptoms of chest pain or shortness of breath. The perfusion scan failed to reveal areas of reversible ischaemia. At the time of writing it is 18 months post-PCI and the patient remains asymptomatic. He is still on dual antiplatelet therapy (aspirin 100 mg + clopidogrel 75 mg).



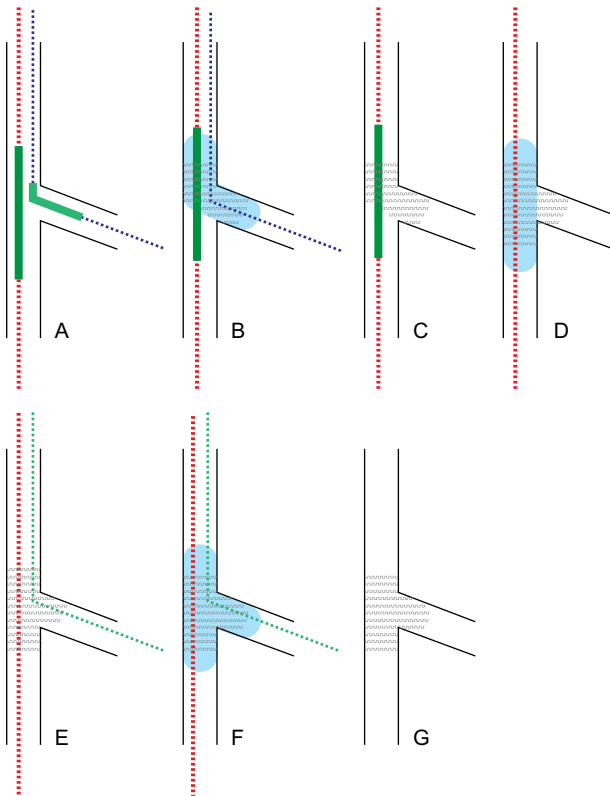
**Figure 2.** Heavily diseased native coronary arteries and vein grafts. A: left coronary artery; B: right coronary artery; C-D: Y-shaped venous graft.



**Figure 3.** Final angiographic result for the Y-shaped venous graft.

### ***The “crush” technique: description of the procedure***

The procedure has been described in the past and is presented schematically in Figure 4.<sup>3,6</sup> The technique requires the use of a guide catheter of at least 7 F. Both the main vessel and the side branch are wired and prepared for stent implantation with predilatation as necessary. The stents are positioned in such a way that the proximal part of the side branch stent protrudes well into the main branch (4-5 mm proximally to the carina of the bifurcation). The main branch stent fully covers the bifurcation lesion and it is crucial that its proximal part is always more proximal in the coronary tree than the proximal marker of the stent for the side branch. Following appropriate positioning of the stents, the side branch stent is deployed



**Figure 4.** Schematic description of the crush technique. A: wires and stents positioned in main vessel and side branch; B: inflation of stent in side branch; C: side branch stent and wire removal; D: expansion of main vessel stent; E: side branch re-wired through the stent struts; F: final kissing balloon; G: final result.

first and the balloon is carefully removed, ensuring that the stent in the main vessel remains in place. The wire of the side branch is usually also removed. The stent in the main vessel is subsequently deployed, thus crushing the proximal part of the side branch stent to the main vessel wall proximally to the carina. It is usually advisable to perform a post-dilatation of the main branch stent with a high-pressure balloon, in order to facilitate re-wiring of the side branch, and a final kissing balloon.

## Discussion

The present case demonstrates that using the “crush” procedure for the treatment of a venous graft bifurcation lesion is feasible, achieving a satisfactory angiographic result and a favourable long-term clinical outcome. The case is unique in the literature, since this type of Y-shaped venous graft is rarely used in CABG operations.

Treating bifurcation lesions, even in the setting of native coronary arteries, remains an issue of controversy among interventional cardiologists. Initial attempts to treat such lesions were made in the era of balloon angioplasty, with poor results. Failure was attributed to plaque shift between the two branches and led to attempts at plaque volume reduction using techniques such as rotational atherectomy. The introduction of bare metal stents (BMS) improved outcomes and various strategies were suggested.<sup>7-9</sup> Despite this improvement, however, bifurcation lesions were subject to higher rates of restenosis and need for target lesion revascularisation (TLR) compared to non-bifurcated ones. Historical data suggest a TLR rate of 16% to 38%, the worse outcomes usually being associated with stent deployment in both the main vessel and the side branch, compared to single branch stenting (and provisional stenting of the side branch).<sup>10,11</sup> In the same studies, the recorded numbers of major adverse cardiac events (MACE) at six months, defined as cardiac death, acute myocardial infarction or target vessel revascularisation, were similarly very high, ranging from 17% to 51%.

The introduction of drug-eluting stents into clinical practice significantly reduced the restenosis rates of relatively simple lesions and created reasonable hopes for better outcomes in the treatment of complicated bifurcation lesions. Initial reports concerning the use of sirolimus-eluting stents in such patients seemed favourable, as far as patency of the main branch was concerned, but suggested higher restenosis rates of the side branch ostium.<sup>12-14</sup> This was attributed to incomplete coverage of the side branch ostium and led to the reintroduction of previously reported techniques to allow stenting of the side branch when needed: the classic T-stenting involves stenting of the side branch ostium with a second stent then deployed in the main branch; V-stenting involves the delivery and expansion of two stents simultaneously, with the proximal edges of the stents in contact, forming a small proximal carina; in simultaneous kissing stents, two stents are accommodated side by side in the main branch (proximally to the bifurcation); culotte provides excellent cover of the side branch ostium using two stents, while other techniques described are Y-stenting and the “skirt”.<sup>15</sup> Dedicated bifurcation stents represent a different perspective in the solution of this problem, aiming to maintain safe access to the side branch as well as to ensure full coverage of the carina and the side branch ostium. Several such stents are already available or under

clinical trials. However, most of them did not become very popular, since they proved bulky and difficult to deliver through tortuous and calcified vessels, while quite often accurate positioning and deploying of those stents proved tricky in practice.<sup>16</sup>

Colombo et al<sup>3</sup> suggested the “crush” technique, described above. The “crush” technique is a relatively simple strategy that ensures complete lesion coverage, even for bifurcation lesions that have extensive disease within the side branch. Preliminary short-term data were encouraging, suggesting that this strategy could be used effectively for bifurcation lesions.<sup>3</sup> Long-term outcomes of the method have also been published, with MACE-free survival rates at 9 months reported as 83.5% for the overall population and 94.2% when left main stenosis (LMS) lesions are excluded from the analysis<sup>17</sup>. The reduced efficacy of the method in the treatment of LMS bifurcations represents a matter for concern and has also been documented in other studies.<sup>18</sup> Ge et al have demonstrated that final kissing balloon and post-dilatation are almost mandatory in the “crush” technique, since they are associated with a significantly reduced side-branch late lumen loss and need for TLR.<sup>19</sup> In most cases, the lack of a final kissing balloon leads to under-expansion and malapposition of the struts, whereas post-dilatation opens the struts, optimising access to the side branch, and corrects stent deformation, therefore providing optimal scaffolding and delivery of the drug.

The safety of drug-eluting stents used in venous grafts was initially supported by some non-randomised trials, suggesting a similar benefit compared to BMS,<sup>20,21</sup> while later small randomised trials have suggested a beneficial effect over BMS, with lower rates of in-stent restenosis.<sup>22,23</sup> Bifurcation lesions of saphenous venous grafts are rarely seen in the clinical setting. Techniques commonly used in bifurcations of native coronary arteries, such as the “crush” procedure, seem, however, to be technically feasible and are associated with a satisfactory angiographic and clinical outcome.

We recognise the lack of angiographic follow up as a weakness of the present report. However, the risk of contrast-induced nephropathy for the particular patient was unacceptably high (advanced age, diabetes, reduced creatinine clearance) and we considered that to suggest a new diagnostic angiogram for confirmation of our result would be unethical. Moreover, both the lack of clinical symptoms and the follow-up perfusion scan suggested patency of the graft and the absence of haemodynamically significant restenosis.

## References

1. Myler RK, Shaw RE, Stertz SH, et al. Lesion morphology and coronary angioplasty: current experience and analysis. *J Am Coll Cardiol.* 1992; 19: 1641-1652.
2. Fischman DL, Savage MP, Leon MB, et al. Fate of lesion-related side branches after coronary artery stenting. *J Am Coll Cardiol.* 1993; 22: 1641-1646.
3. Colombo A, Stankovic G, Orlic D, et al. Modified T-stenting technique with crushing for bifurcation lesions: immediate results and 30-day outcome. *Catheter Cardiovasc Interv.* 2003; 60: 145-151.
4. Dimopoulos AK, Manginas A, Pavlides G, Cokkinos DV. PCI in severely degenerated saphenous vein graft using a novel mesh-covered stent together with a conventional embolic protection system. *Hellenic J Cardiol.* 2009; 50: 429-435.
5. Hamilos MI, Kochiadakis GE, Karalis I, Skalidis EI, Igoumenidis NE, Vardas PE. Combined use of aspiration catheter and distal embolisation protection device to facilitate angioplasty of a totally occluded saphenous vein graft. *Hellenic J Cardiol.* 2007; 48: 117-121.
6. Iakovou I, Colombo A. Two-stent techniques for the treatment of coronary bifurcations with drug-eluting stents. *Hellenic J Cardiol.* 2005; 46: 188-198.
7. Lefèvre T, Louvard Y, Morice MC, Loubeyre C, Piéchaud JF, Dumas P. Stenting of bifurcation lesions: a rational approach. *J Interv Cardiol.* 2001; 14: 573-585.
8. Pan M, Suárez de Lezo J, Medina A, et al. Simple and complex stent strategies for bifurcated coronary arterial stenosis involving the side branch origin. *Am J Cardiol.* 1999; 83: 1320-1325.
9. Yamashita T, Nishida T, Adamian MG, et al. Bifurcation lesions: two stents versus one stent—immediate and follow-up results. *J Am Coll Cardiol.* 2000; 35: 1145-1151.
10. Al Suwaidi J, Berger PB, Rihal CS, et al. Immediate and long-term outcome of intracoronary stent implantation for true bifurcation lesions. *J Am Coll Cardiol.* 2000; 35: 929-936.
11. Lefèvre T, Louvard Y, Morice MC, et al. Stenting of bifurcation lesions: classification, treatments, and results. *Catheter Cardiovasc Interv.* 2000; 49: 274-283.
12. Assali A, Raz Y, Vaknin-Assa H, et al. Beneficial 2-years results of drug-eluting stents in saphenous vein graft lesions. *EuroIntervention.* 2008; 4: 108-114.
13. Colombo A, Moses JW, Morice MC, et al. Randomized study to evaluate sirolimus-eluting stents implanted at coronary bifurcation lesions. *Circulation.* 2004; 109: 1244-1249.
14. Pan M, de Lezo JS, Medina A, et al. Rapamycin-eluting stents for the treatment of bifurcated coronary lesions: a randomized comparison of a simple versus complex strategy. *Am Heart J.* 2004; 148: 857-864.
15. Iakovou I, Ge L, Colombo A. Contemporary stent treatment of coronary bifurcations. *J Am Coll Cardiol.* 2005; 46: 1446-1455.
16. Sheiban I, Omedé P, Biondi-Zoccai G, Moretti C, Sciuto F, Trevi GP. Update on dedicated bifurcation stents. *J Interv Cardiol.* 2009; 22: 150-155.
17. Hoye A, Iakovou I, Ge L, et al. Long-term outcomes after stenting of bifurcation lesions with the “crush” technique: predictors of an adverse outcome. *J Am Coll Cardiol.* 2006; 47: 1949-1958.
18. Park S-J, Kim Y-H, Lee B-K, et al. Sirolimus-eluting stent implantation for unprotected left main coronary artery steno-

- sis: comparison with bare metal stent implantation. *J Am Coll Cardiol.* 2005; 45: 351-356.
19. Ge L, Airoidi F, Iakovou I, et al. Clinical and angiographic outcome after implantation of drug-eluting stents in bifurcation lesions with the crush stent technique: importance of final kissing balloon post-dilation. *J Am Coll Cardiol.* 2005; 46: 613-620.
  20. Brilakis ES, Berger PB. Should bare metal or drug-eluting stents be used during PCI of saphenous vein graft lesions: waiting for Godot? *Catheter Cardiovasc Interv.* 2008; 72: 815-818.
  21. Tsuchida K, Ong ATL, Aoki J, et al. Immediate and one-year outcome of percutaneous intervention of saphenous vein graft disease with paclitaxel-eluting stents. *Am J Cardiol.* 2005; 96: 395-398.
  22. Brilakis ES, Lichtenwalter C, de Lemos JA, et al. A randomized controlled trial of a paclitaxel-eluting stent versus a similar bare-metal stent in saphenous vein graft lesions the SOS (Stenting of Saphenous Vein Grafts) trial. *J Am Coll Cardiol.* 2009; 53: 919-928.
  23. Vermeersch P, Agostoni P, Verheye S, et al. Randomized double-blind comparison of sirolimus-eluting stent versus bare-metal stent implantation in diseased saphenous vein grafts: six-month angiographic, intravascular ultrasound, and clinical follow-up of the RRISC Trial. *J Am Coll Cardiol.* 2006; 48: 2423-2431.