

## Cardiac Imaging

# Sixty-Four Slice Computed Tomography as an Alternative Modality for the Non-Invasive Diagnosis of Left Ventricular Pseudoaneurysm

PANAGIOTIS G. MARNELOS, GEORGIOS P. GEORGHIOU, LAMPROS E. MITSELOS, TATIANA Y. MICHAELIDES, CHRISTOS P. CHRISTOU, MARINOS C. SOTERIOU

*Cardiology and Cardiothoracic Department, American Heart Institute, Nicosia, Cyprus*

Key words: **Cardiac imaging, myocardial rupture.**

*Manuscript received:*  
April 8, 2009;  
*Accepted:*  
July 10, 2009.

*Address:*  
Panagiotis G. Marnelos

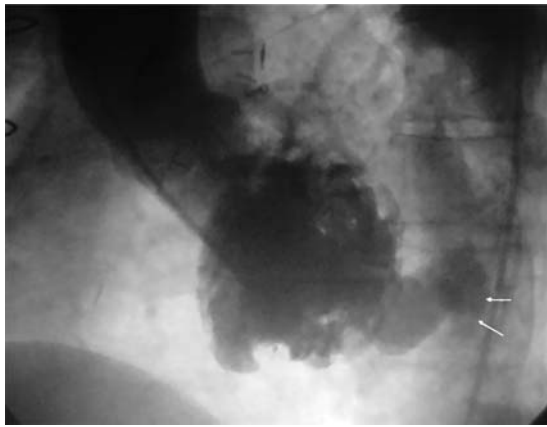
*Department of*  
*Cardiology*  
*American Heart Institute*  
*P.O. Box 25610*  
*13111, Nicosia*  
*Cyprus*  
*e-mail:*  
[panagiotis.marnelos@gmail.com](mailto:panagiotis.marnelos@gmail.com)

**L**eft ventricular (LV) pseudoaneurysms form when cardiac rupture is contained by adherent pericardium or scar tissue.<sup>1</sup> Thus, unlike a true LV aneurysm, an LV pseudoaneurysm contains no endocardium or myocardium.<sup>2</sup> Free intrapericardial rupture usually results in cardiac tamponade and death.<sup>3</sup> Less frequently, cardiac rupture is contained and LV pseudoaneurysm formation occurs. The most common aetiology of LV pseudoaneurysm is myocardial infarction; inferior infarcts are approximately twice as common as anterior infarcts.<sup>4</sup> Angiography of the LV and coronary arteries is considered to be the best available test for the diagnosis of LV pseudoaneurysm, with a diagnostic accuracy >85%. Transthoracic two-dimensional echocardiography appears to be diagnostic in about 25% of patients, while transoesophageal echocardiography and magnetic resonance imaging appear to have diagnostic accuracies of >75%. While the diagnosis is usually established by left ventriculography, the recent improvement in the quality of computed tomography (CT) scans has allowed for non-invasive detection.<sup>5</sup>

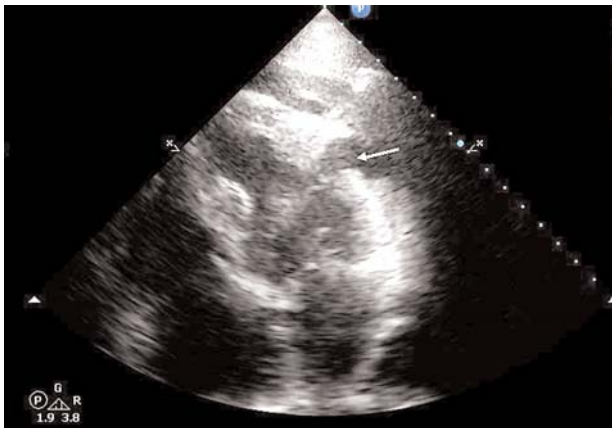A 72-year-old man with a past medical history of coronary artery bypass grafting was admitted to another hospital, in a haemodynamically stable condition, with a late presentation of inferior wall myocardial infarction. The patient underwent cardiac catheterisation, which revealed an occluded vein graft to the left circumflex artery, while the left internal mammary artery (LIMA)

to the left anterior descending artery and the vein graft to the right coronary artery were patent. The left ventriculography revealed contrast penetration in the pericardial cavity through a narrow neck, possibly representing a pseudoaneurysm (Figure 1). The patient was referred to our centre for surgical treatment. The transthoracic echocardiogram on admission confirmed the presence of an LV pseudoaneurysm at the mid segment of the inferolateral wall (Figure 2), in addition to severe LV systolic dysfunction. As a preoperative evaluation of a redo sternotomy, a contrast 64-slice CT was done in order to gain more information about retrosternal adhesions and the position of the LIMA.<sup>6</sup> This information is of great importance for the surgeon in reducing the incidences of sternotomy-related injury. In the same session the contrasted 64-slice CT scan successfully provided a precise image of the pseudoaneurysm (Figures 3 & 4). The patient was then scheduled for resection of the LV pseudoaneurysm.

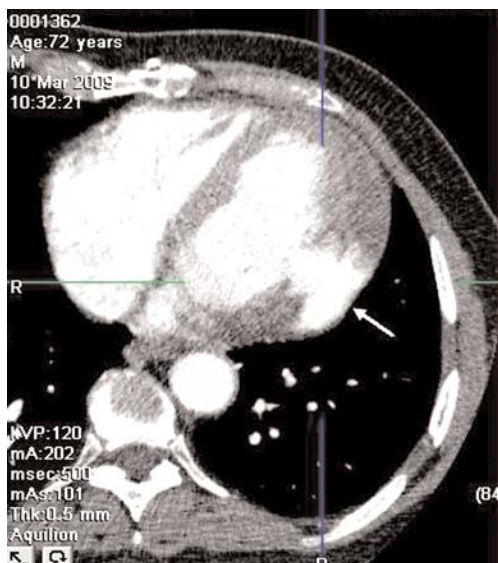After dissection of the anterior wall of the heart, further dissection of the lateral and posterior wall of the heart was performed under cardiopulmonary bypass because of dense adhesion. The LV pseudoaneurysm was located in the posterolateral wall, adherent to the posterior pericardium. After complete immobilisation of the LV, the pseudoaneurysm was opened under aortic cross clamp. The neck of the pseudoaneurysm was identified and closed with a Gore-Tex patch. The ventriculotomy



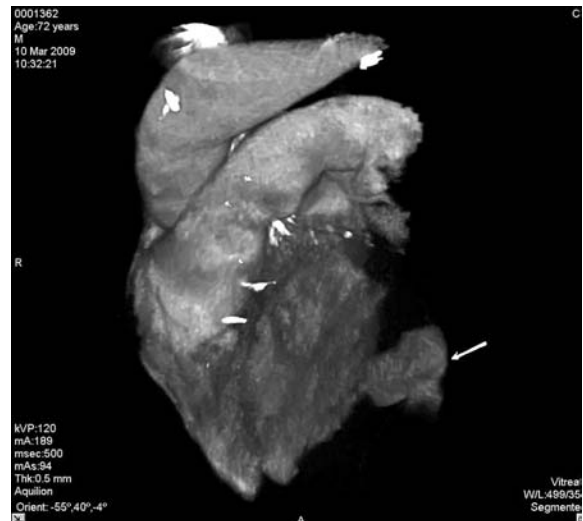
**Figure 1.** Left ventriculography: left anterior oblique view (arrows).



**Figure 2.** Transthoracic echocardiogram: apical 4-chamber view (arrow).



**Figure 3.** 64-slice contrasted computed tomography scan: axial image (arrow).



**Figure 4.** 64-slice contrasted computed tomography scan: volume rendering image (arrow).

was then closed with multiple buttressed sutures. The postoperative course was uneventful.

Contrast 64-slice CT should be considered an alternative, non-invasive modality for the diagnosis and preoperative planning of an LV pseudoaneurysm. We acknowledge that multislice CT is not a diagnostic tool for the serial assessment of these patients, as contrast echocardiography offers similar information by the bedside in unstable patients admitted to the coronary care unit, while in addition it does not expose patients to excessive radiation following other diagnostic procedures such as coronary angiography.

## References

1. Dachman AH, Spindola-Franco H, Solomon N. Left ventricular pseudoaneurysm. Its recognition and significance. *JAMA*. 1981; 246: 1951-1953.
2. Vlodayer Z, Coe JJ, Edwards JE. True and false left ventricular aneurysms. Propensity for the latter to rupture. *Circulation*. 1975; 51: 567-572.
3. Van Tassel RA, Edwards JE. Rupture of heart complicating myocardial infarction: Analysis of 40 cases including nine examples of left ventricular false aneurysm. *Chest*. 1972; 61: 104-116.
4. Davidson KH, Parisi AF, Harrington JJ, Barsamian EM, Fishbein MC. Pseudoaneurysm of the left ventricle: an unusual echocardiographic presentation. Review of the literature. *Ann Intern Med*. 1977; 86: 430-433.
5. Stefanadis CI. Cardiovascular imaging: all techniques under one roof. *Hellenic J Cardiol*. 2008; 49: 201.
6. Exarchos DN, Baltouka A, Mihos C, et al. Imaging and evaluation of coronary artery bypass graft patency by 16-slice multidetector computed tomography. *Hellenic J Cardiol*. 2007; 48: 258-267.