

Case Report

PCI in Severely Degenerated Saphenous Vein Graft Using a Novel Mesh-Covered Stent Together with a Conventional Embolic Protection System

ANTONIS K. DIMOPOULOS, ATHANASSIOS MANGINAS, GREGORY PAVLIDES,
DENNIS V. COKKINOS

Department of Cardiology, Onassis Cardiac Surgery Centre, Athens, Greece

Key words: Saphenous vein graft, embolic protection, no-reflow.

Although the protection with filter-based devices during percutaneous coronary intervention (PCI) in a saphenous vein graft (SVG) reduces major adverse cardiac events, a large number of patients undergoing SVG PCI still experience these events. New methods must be used in order to reduce this incidence. Novel local plaque-trapping stents have been developed and show promise in pilot human testing. We present 2 cases of patients with degenerated SVGs and a large amount of plaque volume, who underwent coronary angioplasty in our department. Considering the high risk of distal embolization, we used a standard distal embolic protection system and a recently developed mesh-covered stent. This combination approach has not yet been studied very well.

Manuscript received:
December 28, 2008;
Accepted:
May 5, 2009.

Address:
Antonis K.
Dimopoulos

51 Zoodohou Pigis St.
15771 Melissa
Athens, Greece
e-mail:
antdim21@gmail.com

The treatment of a diseased saphenous vein graft (SVG) represents one of the major current challenges in current percutaneous coronary intervention (PCI). Patients with diseased SVGs represent one of the highest-risk subgroups of patients undergoing PCI. They are associated with a greater incidence of slow flow and higher rates of periprocedural myocardial infarction, largely owing to distal embolization of the abundant and friable atherosclerotic debris in diseased SVGs. Although embolic protection with either balloon occlusion devices or filter-based devices during SVG PCI reduces major adverse cardiac events (MACE), many patients undergoing SVG PCI still experience adverse events.¹⁻⁵ We report on 2 patients who underwent PCI in degenerated SVGs, with the simultaneous use of 2 different protection systems.

Case presentation

Case 1

The first patient was a 61-year-old male with a history of diabetes mellitus, hypertension and dyslipidemia, who underwent coronary artery bypass grafting in 1993 after an extensive anterior myocardial infarction. He received a left internal mammary graft (LIMA) to the left anterior descending (LAD) artery, two SVGs to a large first diagonal branch and the posterior descending branch of the right coronary artery (RCA), and a free right internal mammary artery (RIMA) graft to the second obtuse marginal branch of the left circumflex (LCx) artery. Two years ago he was admitted to hospital with unstable angina and underwent cardiac catheterization that demonstrated patency of all arterial and vein grafts; he was initially stabilized on medical therapy. He remained

asymptomatic until 6 months prior to his latest admission, when symptoms of accelerated angina began. He underwent SPECT with TL-201, which showed scar and mild ischemia in the LAD territory as well as a large area of ischemia in the inferior wall, considered responsible for the symptoms. He was readmitted to our hospital for clinical evaluation and diagnostic catheterization.

The patient had no symptoms at rest. The physical examination demonstrated normal heart sounds with a mild holosystolic murmur (2/6), and no symptoms of congestion. The 12-lead resting ECG demonstrated sinus rhythm, with q waves in the anterior wall leads and no ST/T abnormalities.

The patient underwent diagnostic cardiac catheterization, which demonstrated severe three-vessel disease with all the native vessels occluded. The LIMA graft was patent, but the distal LAD segment beyond the anastomosis had multiple stenoses up to 70-80%. The free RIMA graft was also patent without major stenosis. The SVG to the first diagonal presented moderate ectasia with diffuse atheromatosis, but no severe stenosis. The second SVG, placed in the periphery of an RCA with large distribution, had a moderate to se-

vere stenosis (60-70%, minimal lumen diameter 2 mm) in its proximal portion. The lesion displayed angiographic features of a ruptured plaque, an appearance that was not evident in the previous coronary angiography two years before. Figure 1 shows the lesion and its “high risk” characteristics for distal embolization (old graft with severe degeneration and large ulcerated plaque). The lesion was considered as the culprit lesion and the decision was taken to perform angioplasty with stenting after pretreatment with intravenous heparin, intracoronary nitroglycerin and intracoronary verapamil. Before the intervention we performed an intravascular ultrasound study using a Volcano IVG/Data recorder (Volcano corporation, Rancho Cordova CA, USA). The plaque area and the plaque burden were calculated (Figure 2A).

Considering the high level of risk for distal embolization, we decided to perform the intervention using not one but two different protection devices, in an attempt to keep the risk of adverse events to the minimum. During the first step, a distal protection Filter Wire EZ (Boston Scientific, USA) device was passed into the SVG across the proximal target stenosis

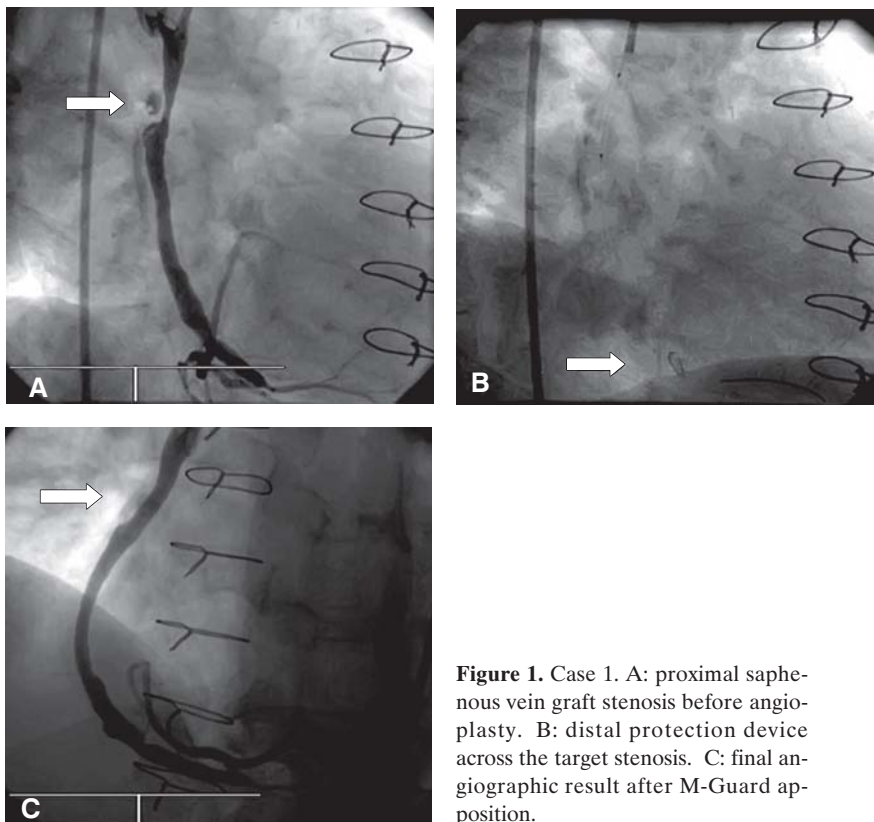


Figure 1. Case 1. A: proximal saphenous vein graft stenosis before angioplasty. B: distal protection device across the target stenosis. C: final angiographic result after M-Guard apposition.

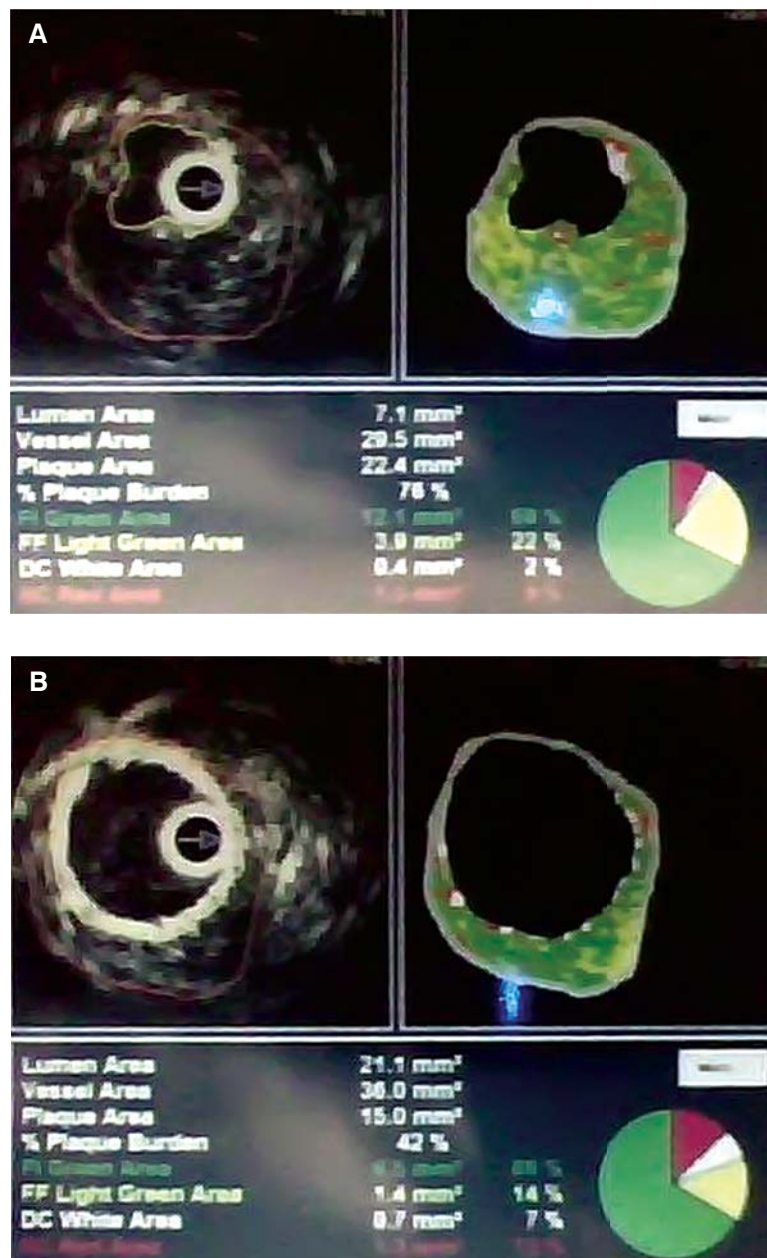


Figure 2. Case 1. Volcano image from degenerative saphenous vein graft before (A) and after (B) stent deployment.

sis (Figure 1B). Predilation was performed with a 4.0 × 12 mm semi-compliant balloon. A 4.0 × 24 mm Inspire MGUARD (Inspire MD, Tel Aviv, Israel) stent, inflated at 16 atm for 10 seconds, was successfully deployed. A successful angiographic result with final TIMI flow 3 was achieved (Figures 1C, 2B).

The remainder of the patient’s hospital course was uneventful. He was asymptomatic and there was no elevation in post interventional CK-MB and troponin. He remained asymptomatic at 6-month follow up.

Case 2

The second patient was a 64-year-old male with a history of smoking, hypertension, and dyslipidemia, who underwent coronary artery bypass grafting in 1995. He received a LIMA graft to the LAD and first diagonal artery (sequential technique), a free RIMA graft to the first obtuse marginal branch, and an SVG to his RCA.

He was asymptomatic until 3 days before his hospital admission for new-onset angina symptoms. He

underwent coronary angiography, which revealed occlusion of the LIMA in the LAD, but with good supply to the first diagonal branch, a severe stenosis in the mid portion of the native LAD vessel, a severe stenosis in the proximal portion of the LCx, and a severe stenosis in the proximal segment of the SVG. We decided to perform a staged revascularization procedure. First we performed angioplasty to the mid LAD stenosis with excellent angiographic results. Nevertheless, the patient remained symptomatic over the following days with many anginal episodes lasting no more than 10 minutes. After this we decided to perform angioplasty to the SVG/RCA graft. First, a distal protection Filter Wire EZ (Boston Scientific, USA) system was passed across the target lesion. After predilation and intracoronary nitroglycerin and verapamil infusion, a 4.0×24 mm Inspire MGUARD (Inspire MD, Tel Aviv, Israel) stent was inflated at 18 atm (Figure 3). The final angiographic result was very good, with no residual stenosis and TIMI III flow with no signs of the no-reflow phenomenon. One day after intervention the patient had a non-significant increase in myocardial necrosis indices (TnI before $0.50 \mu\text{g}/\text{dl}$, TnI after $0.90 \mu\text{g}/\text{dl}$).

Discussion

It is now clearly established that atheroembolization is a common or even ubiquitous consequence of atherosclerotic lesion manipulation. Those emboli may cause end-organ compromise by simple plugging of medium in microcirculatory channels, promotion of local platelet adhesion/thrombosis (plaque constituent contains abundant macrophages and tissue factor), and promotion of microvascular spasm (through thromboxane release). This manifests as the “no-reflow” phenomenon and often leads to myocardial infarction.⁷⁻¹¹

No-reflow is defined as the failure to restore antegrade normal coronary flow, despite appropriate treatment of coronary obstruction.^{8,9} This complication occurs in 0.6% to 5% of PCIs.^{10,11} The incidence appears to be higher in patients undergoing PCI of SVGs, during acute myocardial infarction (MI) or during rotational atherectomy.¹² Large, thrombus-containing lesions in the setting of primary PCI for acute MI and degenerative vein grafts pose the highest risk for this complication.¹³ In SVG PCI the risk of MACE was predicted by the degree of vein graft degeneration and by quantita-

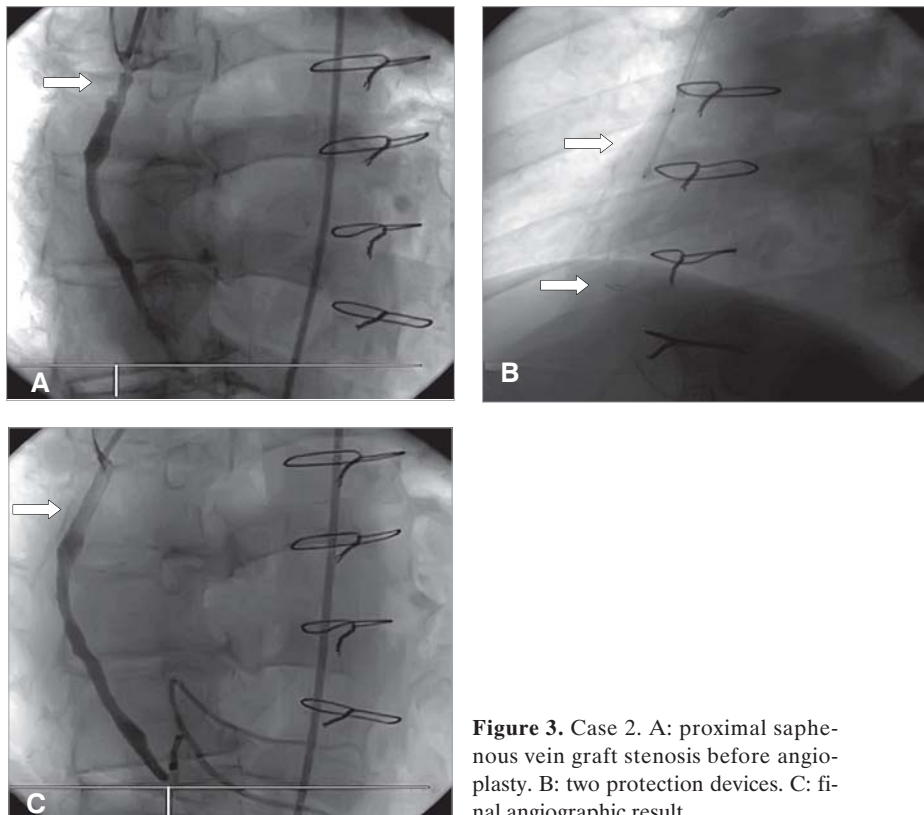


Figure 3. Case 2. A: proximal saphenous vein graft stenosis before angioplasty. B: two protection devices. C: final angiographic result.

tive coronary angiographic assessment of plaque volume.²¹

The occurrence of distal embolization and no-reflow has been associated with adverse short- and long-term outcomes. It is one of the major causes of post-PCI MI and elevation of cardiac markers, contributing to an increase in long-term mortality and morbidity with a significant financial cost.^{6,7} It has been associated with an increase in acute MI of up to 32%^{14,15,16} and a 15% higher incidence of death during the first 30 days.^{14,16} The long-term detrimental effects include increased risk of cardiac death, congestive heart failure, malignant arrhythmias and a decrease in ejection fraction.^{15,18}

Although distal administration of microcirculatory vasodilators (calcium channel blockers, sodium nitroprusside, epinephrine, adenosine) can improve the no-reflow manifestations, there is no evidence that they can protect against infarction.¹⁹ Similarly, platelet glycoprotein IIb/IIIa receptor blockers may reduce secondary platelet clumping around embolic particles, but several studies have failed to demonstrate a protective effect during SVG intervention.²⁰

Embolic protection devices, as an adjunct to SVG PCI, have been shown to reduce the occurrence of no-reflow and the other periprocedural events by approximately 40%¹⁸ and should be used, if possible, in all vein graft PCIs, independently of the clinical and angiographic parameters for distal embolization (Class IIa recommendation).²²⁻²³ There are 4 basic classes of embolic protection device, categorized according to their mechanism of operation: 1) distal occlusion, 2) distal filter, 3) proximal occlusion, and 4) local plaque trapping. In general, data suggest that the first 3 classes of embolic protection have similar efficacy in SVG settings, although specific devices may offer advantages or disadvantages in certain clinical or anatomic situations (e.g. proximal or distal lesion locations).

The first FDA-approved device for distal embolic protection was an occlusion balloon and aspiration system, the PercuSurge Guardwire. The phase I SAFE registry demonstrated the safety of this device, and the landmark SAFER (Saphenous vein graft Angioplasty Free of Emboli Randomized) trial, the first large randomized trial assessing the impact of embolic protection on clinical outcomes,²¹ demonstrated a 6.9% absolute reduction (42% relative reduction) in the primary endpoint with the use of Guardwire.

Distal filters, the second class of protection devices, avoid the procedural ischemia encountered with the Guardwire because they do not interrupt antegrade

flow. Furthermore, they allow more precise positioning of stents and balloon inflations, since contrast injections through the guiding catheter may be performed in the usual manner. Comparative trials have shown that filters are generally as effective as distal occlusion. The first filter to gain regulatory approval (in mid 2003) was the Filterwire EX (Boston Scientific, USA). It consists of a distal polyurethane filter with 80 Am pores, mounted on a 0.014 inch steerable guidewire. The system allows for free and independent rotation of guide and filter. On top of the filter and attached to it, a self-expandable, radiopaque, and elliptically shaped nitinol loop is designed to assume the profile of the vessel and to afford compatibility with different vessel sizes (from 3.5 to 5.5 mm in diameter). The collapsed filter has a crossing profile of 3.9 Fr.

The Filterwire EX was studied in the initial phase I study and then in the pivotal randomized Filterwire EX Randomized Evaluation (FIRE) trial,²⁰ which demonstrated the same relative efficacy and safety of filtering versus distal occlusion approach for SVG stenting. The also approved, second generation Filter Wire (FilterWire EZ) has several improvements to the FilterWire EX device, including a mechanism to enhance filter centering even in curved segments, and a lower profile peel-away delivery sheath.

The concept of an interventional device that traps all potentially embolic debris against the vessel wall at the treatment site has been attractive. Conventional stents liberate large amounts of debris when deployed in SVGs (and may continue to shed some debris even after the PCI has been completed and the embolic protection device is no longer in place), but it was hoped that a stent covered with microporous poly-tetrafluoroethylene (as used to treat life-threatening coronary perforations) could also serve as a form of "local filter" during SVG interventions. Early trials, however, showed no reduction in acute MACE and an increase in late occlusion with covered as opposed to bare metal stents. Novel local plaque-trapping approaches under study have shown promise in pilot human testing.^{23,24}

M-Guard (Inspire-MD, Tel Aviv, Israel), is an ultra thin, flexible polyethylene terephthalate (PET or Dacron) mesh sleeve fabricated by circular knitting. The M-Guard is anchored to the external surface of the stent. This biocompatible microfiber net (string diameter 10-22 microns) has minimal effects (<0.1 mm) on the stent's crossing profile or deliverability. During stent deployment, the net is able to stretch, creating custom designed pores of ~200 microns in diameter (pores created by stent struts are 10- to 40-fold

larger in diameter, translating into a 100- to 1600-fold larger cross sectional area).

The first experimental studies showed no significant difference between the M-Guard and the bare metal stent with regard to late loss, percent diameter stenosis and minimal luminal diameter, with 100% delivery success.²⁵ The use of the M-Guard stent has several theoretical advantages over conventional embolic protection, and atherectomy devices. The embolic protection function of the stent is deployed at the time of PCI and, as the mesh is on the stent, there remains an enduring effect after the intervention. The M-Guard stent is delivered by conventional means, meaning that delivery is rapid, with no need for specialist training. Thus, M-Guard has the theoretical potential to serve as a “built-in” and permanent embolic protection device. To date, its use in degenerated SVGs and also in acute coronary syndromes, in “thrombus rich” lesions,²⁶ is very promising.

Although guidelines mandate the use of embolic protection devices in PCI of vein grafts,²⁷ these devices are at most 50% effective and suffer from considerable shortcomings. The 30-day MACE rates in the FIRE, SAFER, and PRIDE trial protection groups were between 9.6 and 11.6%. Although the mechanisms responsible for these events are not clear, possible contributors include: a) particles released during initial lesion crossing before filter or balloon deployment, at the time of deployment of the protection device itself; b) incomplete aspiration of particles (particularly those adherent to the device itself); c) motion of the protection system during the procedure, with transient loss of apposition and escape of particles; d) embolic fragments adherent to the stented site, not freely mobile, which embolize in the early post-procedure hours; and e) other unknown factors. Novel approaches must be used in order to further reduce all of the above events, and our approach is aimed in this direction.

We believe this to be one of the first reports of a procedure carried out with two different protection devices in order to treat the same lesion of the same diseased SVG.^{28,29} The use of M-Guard permits its combination with other protection devices without time consuming or technical difficulties.

The case described here is a long way from being considered as a routine approach to all SVGs lesions, in view of the lack of long-term follow-up data for this device; however, as far as patency and restenosis rate are concerned, we sought to provide a possible solution to more complex cases of SVG stenosis, such as

old grafts with severe degeneration and a large amount of plaque volume.

References

1. Stone GW, Rogers C, Hermiller J, Randomized comparison of distal protection with a filter-based catheter, a balloon occlusion and aspiration system during percutaneous intervention of diseased saphenous vein aorto-coronary bypass grafts. *Circulation*. 2003; 108: 548-553.
2. Giugliano GR, Kuntz RE, Popma JJ, et al. Determinants of 30-day adverse events after saphenous vein graft intervention with and without a distal occlusion embolic protection device. *Am J Cardiol*. 2005; 95: 173-177.
3. Sievert H, Wahr DW, Schuler G, et al. Effectiveness and safety of the Proxis system in demonstrating retrograde coronary blood flow during proximal occlusion and in capturing embolic material. *Am J Cardiol*. 2004; 94: 1134-1139.
4. Mauri L, Rogers C, Baim DS, et al. Devices for distal protection during percutaneous coronary revascularization. *Circulation*. 2006; 113: 2651-2656.
5. Hong MK, Mehran R, Dangas G, et al. Creatine kinase-MB enzyme elevation following successful saphenous vein graft intervention is associated with late mortality. *Circulation*. 1999; 100: 2400-2405.
6. Cohen DJ, Murphy SA, Baim DS, et al. Cost-effectiveness of distal embolic protection for patients undergoing percutaneous intervention of saphenous vein bypass grafts: results from the SAFER trial. *J Am Coll Cardiol*. 2004; 44: 1801-1808.
7. Kloner RA, Ganote CE, Jennings RB. The “no-reflow” phenomenon after temporary coronary occlusion in the dog. *J Clin Invest*. 1974; 54: 1496-1508.
8. Kelly RV, Cohen MG, Stouffer GA, et al. Incidence and management of “no-reflow” following percutaneous coronary interventions. *Am J Med Sci*. 2005; 329: 78-85.
9. Piana RN, Paik GY, Moscucci M, et al. Incidence and treatment of “no-reflow” after percutaneous coronary intervention. *Circulation*. 1994; 89: 2514-2518.
10. Vallejo E, Pena-Duque MA, Norono O, et al. The no-reflow phenomenon: its incidence and clinical characteristics in a series of cases. *Arch Inst Cardiol Mex*. 1998; 68: 247-252.
11. Eeckhout E, Kern MJ. The coronary no-reflow phenomenon: a review of mechanisms and therapies. *Eur Heart J*. 2001; 22: 729-739.
12. Kotani J, Nanto S, Mintz GS, et al. Plaque gruel of atheromatous coronary lesion may contribute to the no-reflow phenomenon in patients with acute coronary syndrome. *Circulation*. 2002; 106: 1672-1677.
13. Abbo KM, Dooris M, Glazier S, et al. Features and outcome of no-reflow after percutaneous coronary intervention. *Am J Cardiol*. 1995; 75: 778-782.
14. Resnic FS, Wainstein M, Lee MK, et al. No-reflow is an independent predictor of death and myocardial infarction after percutaneous coronary intervention. *Am Heart J*. 2003; 145: 42-46.
15. Movahed MR, Balian H, Moraghebi P, et al. Reversible severe ischemic mitral regurgitation and cardiogenic shock as a complication of percutaneous coronary intervention. *J Invasive Cardiol*. 2005; 17: 104-107.
16. Lee CH, Wong HB, Tan HC, et al. Impact of reversibility of no reflow phenomenon on 30-day mortality following percutaneous

- revascularization for acute myocardial infarction—insights from a 1,328 patient registry. *J Interv Cardiol.* 2005; 18: 261-266.
17. Morishima I, Sone T, Okumura K, et al. Angiographic no-reflow phenomenon as a predictor of adverse long-term outcome in patients treated with percutaneous transluminal coronary angioplasty for first acute myocardial infarction. *J Am Coll Cardiol.* 2000; 36: 1202-1209.
 18. Baim DS, Wahr D, George B, et al. Randomized trial of a distal embolic protection device during percutaneous intervention of saphenous vein aortocoronary bypass grafts. *Circulation.* 2002; 105: 1285-1290.
 19. Resnic FS, Wainstein M, Lee MK, et al. No-reflow is an independent predictor of death and myocardial infarction after percutaneous coronary intervention. *Am Heart J.* 2003; 145: 42-46.
 20. Jonas M, Stone GW, Mehran R, et al; FilterWire EX Randomized Evaluation (FIRE) Investigators. Platelet glycoprotein IIb/IIIa receptor inhibition as adjunctive treatment during saphenous vein graft stenting: differential effects after randomization to occlusion or filter-based embolic protection. *Eur Heart J.* 2006; 27: 920-928.
 21. Giugliano GR, Kuntz RE, Popma JJ, et al. Determinants of 30-day adverse events following saphenous vein graft intervention with and without a distal occlusion embolic protection device. *Am J Cardiol.* 2005. 15; 95: 173-177.
 22. van Gaal WJ, Patrick R, Dzavik V, et al. Prediction of distal embolization during percutaneous coronary intervention in saphenous vein grafts. *Am J Cardiol.* 2007; 99: 603-606.
 23. Stefanadis C, Toutouzas K, Tsiamis E, et al. Implantation of stents covered by autologous arterial grafts in human coronary arteries: a new technique. *J Invasive Cardiol.* 2000; 12: 7-12.
 24. Stefanadis C, Toutouzas K, Tsiamis E, et al. Stents covered by autologous venous grafts: feasibility and immediate and long-term results. *Am Heart J.* 2000; 139: 437-445.
 25. Kaluski E, Groothuis A, Klapholz M, et al. Coronary stenting with M-Guard: feasibility and safety porcine trial. *J Invasive Cardiol.* 2007; 19: 326-330.
 26. Jain A, Weerackody R, Kennon S, Rothman M. Prevention of thrombus embolization during primary percutaneous intervention using a novel mesh covered stent. *Catheter Cardiovasc Interv.* 2009. 1; 74: 88-93.
 27. Silber S, Albertsson P, Fernandez-Avilès F, et al. Guidelines for percutaneous coronary interventions. *Eur Heart J.* 2005; 26: 804-847.
 28. Hamilos M, Kochiadakis G, Karalis I, et al. Combined use of aspiration catheter and distal embolisation protection device to facilitate angioplasty of a totally occluded saphenous vein graft. *Hellenic J Cardiol.* 2007; 48: 117-121.
 29. Bedogni F, Morici N, Brambilla N, et al. Percutaneous treatment of a single saphenous vein graft with two different protection devices. *J Invasive Cardiol.* 2008; 20: E180-182.