

## Case Report

## The Role of the Implantable Loop Recorder in the Investigation of Recurrent Syncope

SKEVOS K. SIDERIS<sup>1</sup>, TERESA A. MOUSIAMA<sup>1</sup>, PAVLOS N. STOUGIANNOS<sup>1</sup>, IOANNIS P. SKIADAS<sup>1</sup>, FOTINI P. LAIOU<sup>1</sup>, ILIAS K. SOTIROPOULOS<sup>1</sup>, KOSTAS A. GATZOULIS<sup>2</sup>, CHRISTODOULOS STEFANADIS<sup>2</sup>, IOANNIS E. KALLIKAZAROS<sup>1</sup>

<sup>1</sup>Cardiology Department, <sup>2</sup>1st Cardiology Department, University of Athens Medical School, Hippokraton Hospital, Athens, Greece

## Key words:

**Recurrent syncope, implantable loop recorder.**

Recurrent syncope is a common clinical problem. Patients with recurrent syncope frequently undergo extensive investigations that consume significant health care resources. Nevertheless, in a large percentage of patients syncope remains unexplained. The implantable loop recorder is a recognized diagnostic tool that can provide a definitive diagnosis and thus permit specific treatment. We present the case of a woman with recurrent syncope who was referred to our cardiology department for further investigation. Her last episode had led to a fall that caused her serious injuries. The initial routine workup was negative for cardiac, neurologic or metabolic causes of syncope. The implantable loop recorder revealed an arrhythmic origin for the recurrent syncope. The patient was managed appropriately with pacemaker implantation and has remained asymptomatic for one year.

Manuscript received:  
June 25, 2008;  
Accepted:  
November 21, 2008.

Address:  
Skevos Sideris

4, Evrou St,  
11528 Ampelokipi  
Athens, Greece  
e-mail:  
[skevos1@otenet.gr](mailto:skevos1@otenet.gr)

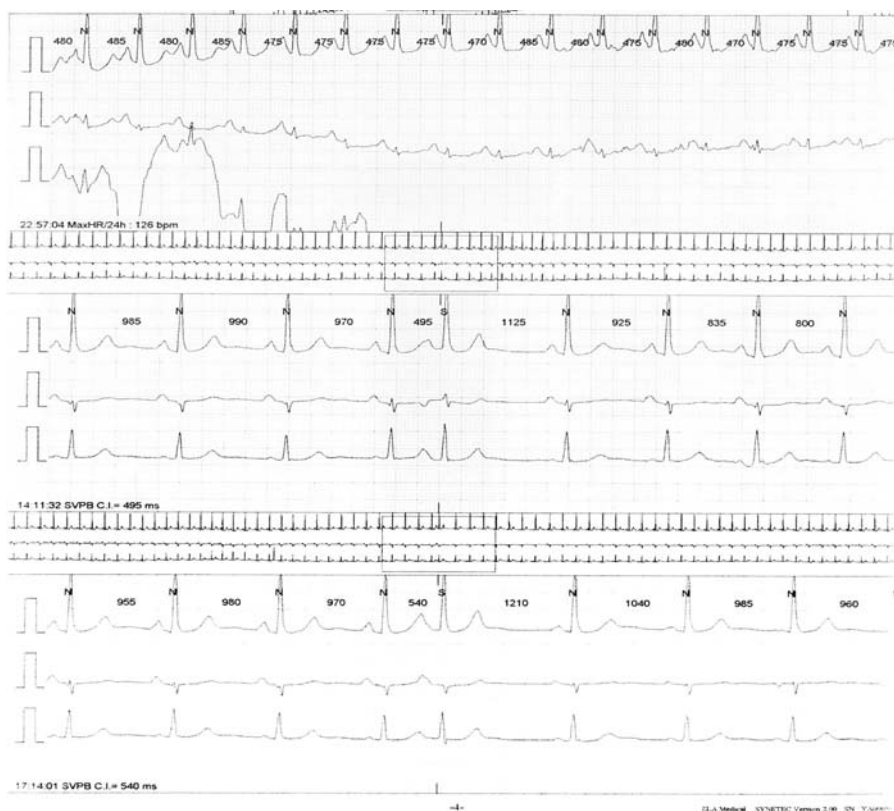**T**he implantable loop recorder (ILR) is a recognized diagnostic modality in the investigation of recurrent syncope suggesting a possible cardiac rhythm abnormality.<sup>1,2</sup> The ILR is able to sense and automatically record arrhythmic events. It is a valuable tool in the diagnostic workup of patients presenting with syncope of unknown origin, when the history, in combination with clinical examination, resting electrocardiogram (ECG), tilt-table testing and electrophysiology are inconclusive. Documenting a cardiac rhythm abnormality as the cause of recurrent syncope<sup>3</sup> allows appropriate management aimed at preventing subsequent syncopal episodes, with beneficial effects on the patient's prognosis and quality of life.<sup>4</sup>

### Case presentation

A 70-year-old woman was referred from a regional rural hospital to our cardiology department for further investigation of recur-

rent syncope in the last three years. Her last syncope caused her to fall to the ground and suffer injuries to the neck and facial cranium, presenting with periorbital bruising. Her medical history included arterial hypertension treated with angiotensin II receptor antagonists. Multiple 24-hour recordings of cardiac rhythm had been performed and documented atrial extrasystoles with no pauses or significant rhythm abnormalities that could account for syncopal episodes (Figure 1). Echocardiography showed diastolic dysfunction with left ventricular ejection fraction ~60%. The patient also underwent brain computed tomography scanning with normal findings.

Clinical examination provided no significant abnormal findings, apart from the above-described injuries to the facial cranium. Routine blood tests were within normal range. The chest X-ray at admission was also normal. The resting ECG showed sinus rhythm with a normal heart rate (Figure 2). Ultrasound examination of the



**Figure 1.** A snapshot from the 24-hour ambulatory ECG monitoring, showing rare supraventricular extrasystoles.

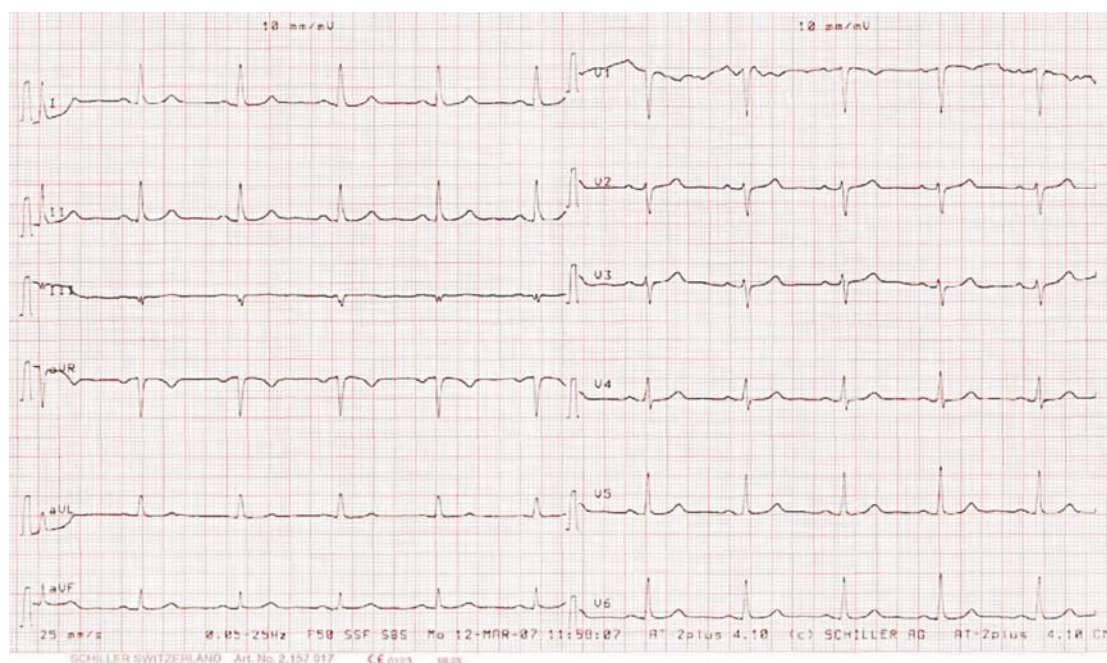
cervical arteries showed no hemodynamically significant occlusion of the carotid arteries, while the vertebral arteries were also patent and the direction of blood flow was the same as in the carotid arteries. Exercise ECG and tilt-table testing were also negative. Electrophysiology showed normal sinus and atrioventricular node function with failure to induce ventricular arrhythmia following intravenous administration of beta-adrenergic agonists.

Since the comprehensive diagnostic workup failed to reveal the origin of recurrent syncope, implantation of a loop recorder was indicated. In the first 3 months of follow up, several automatic recordings were obtained which were not related to syncope. These recordings were the result of sensing problems, which led to automatic activation of the device (Figure 3). During the same period, one patient-activated recording following a syncopal episode was obtained. This recording documented atrial fibrillation with a rapid ventricular response followed by a pause lasting more than 5 seconds (Figure 4). A permanent transvenous dual chamber pacemaker was implanted and the patient was fur-

ther treated with oral anticoagulants (acenocoumarol) and propafenone. The ILR remained in place for one year following pacemaker implantation. Atrial fibrillation episodes were not recorded and syncope did not recur during this period. Subsequently, the device was surgically removed.

## Discussion

We present the case of a female patient with recurrent syncope of unknown origin. Conventional diagnostic workup in primary and secondary health facilities had failed to reveal the underlying pathophysiologic mechanism. The unpredictable nature and the traumatic consequences of syncopal episodes called for further investigation. Patients with syncope of unknown origin have a yearly mortality rate of 6% and a yearly incidence of sudden death of 4%. Cardiogenic syncope is associated with a yearly mortality of 18-32% and a sudden death incidence of 24%.<sup>5</sup> Irrespective of the cause of syncope, underlying cardiac disease is associated with increased death risk.<sup>6</sup> In 50%



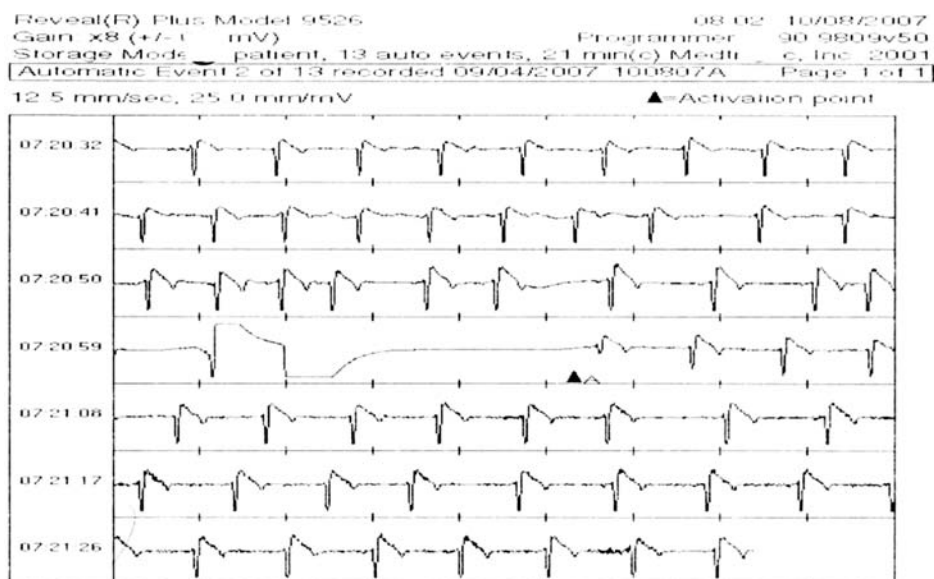
**Figure 2.** Resting ECG showing sinus rhythm with a normal heart rate.

of patients with recurrent syncope there is an arrhythmogenic cause,<sup>7-9</sup> which may be treated effectively.<sup>10</sup> Our patient was therefore referred to a tertiary health facility specializing in arrhythmias.

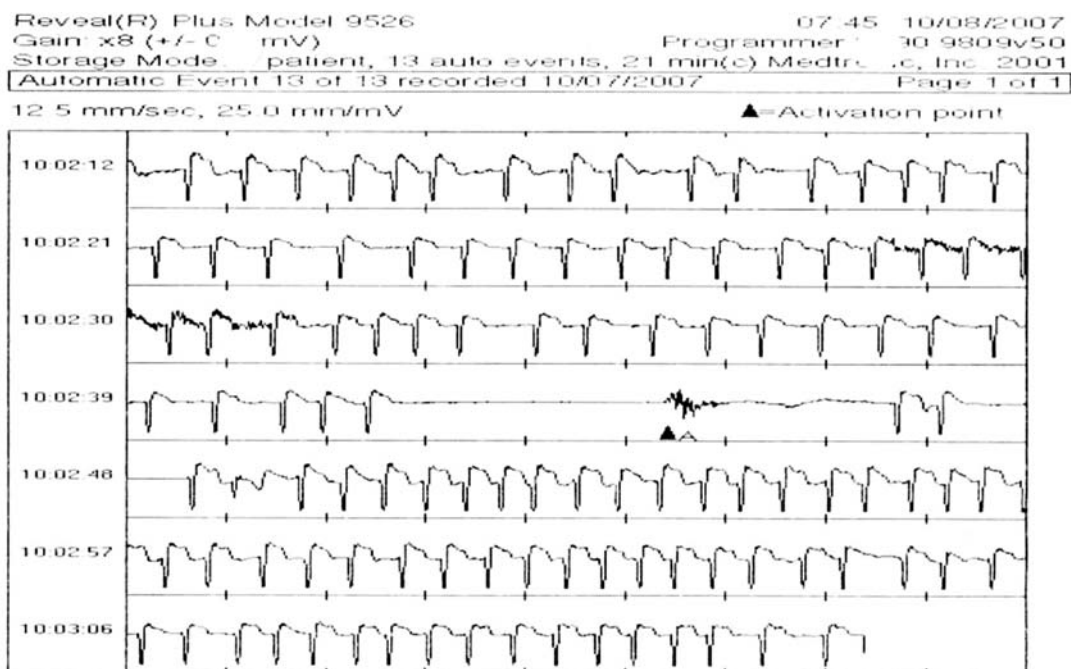
Syncope is a symptom defined as a transient, self-limited loss of consciousness, which usually causes the patient to fall to the ground. The onset of syncope is abrupt and the subsequent recovery is spontaneous,

complete and prompt. Syncope recurs in at least 50% of patients. Recurrent syncope is a frequent clinical problem. It accounts for 1-6% of hospital admissions and up to 3% of emergency department presentations. In the general population, the incidence of syncope is 3%.

The most common of the arrhythmogenic causes, according to most studies, is sick sinus syndrome.



**Figure 3.** Automatic activation of the implantable loop recorder. This is a false recording of a pause due to sensing problems (probably poor contact between the device and the heart).



**Figure 4.** Activation of the device by the patient following a syncopal episode. Atrial fibrillation with a rapid ventricular response was recorded, followed by a pause lasting more than 5 s.

Quite often, however, extensive arrhythmologic studies fail to establish a diagnosis. Ambulatory electrocardiographic monitoring is non-diagnostic in 90% of patients.<sup>11</sup> Electrophysiology reveals arrhythmia probably accounting for syncope in 12-40% of the cases.<sup>12</sup> A negative electrophysiologic study does not rule out severe arrhythmia as the cause of syncopal episodes. Tilt-table testing has a low diagnostic value (30-40%); nevertheless, the patient's history often provides evidence suggesting a neurocardiogenic origin of syncope.

Failure to document the cause of recurrent syncope despite comprehensive invasive and noninvasive investigation creates therapeutic dilemmas and affects not only the quality of life, but also the patient's prognosis. Our patient had already suffered three syncopal events. All were associated with physical injury. The sudden and unexpected nature of syncope caused her great concern about the outcome of this condition. She worried that this would happen again and that it might be fatal. Her concerns were absolutely justified.

Recent advances in loop recorder technology allow long-term electrocardiographic monitoring of patients with recurrent syncope of unknown origin. According to current guidelines,<sup>13</sup> implantation of an

ILR is indicated in patients with syncope of unknown origin after a conventional diagnostic workup with clinical or ECG features suggestive of an arrhythmogenic cause, or a history of recurrent syncope with injury. An ILR may also be indicated in the initial phase of the workup, instead of conventional investigations, in patients with preserved cardiac function who have clinical or ECG features suggesting an arrhythmic syncope, as well as in the assessment of the contribution of bradycardia before embarking on cardiac pacing in patients with suspected or certain neurally-mediated syncope presenting with frequent or traumatic syncopal episodes.

The ILR is placed subcutaneously in the upper left part of the thorax and allows continuous ECG monitoring using a solid-state loop memory, which can store up to 24 months. The device can be activated either by the patient or automatically and stores ECG recordings 20 min before and 4 min after activation, enabling the recording of the arrhythmogenic or symptomatic episode. ILR data are entered in a computer for interrogation.

Automatic activation is an important advantage of second generation ILRs, since higher mortality rates were reported in patients who failed to activate the device following a syncopal episode.<sup>14</sup> Optimal



mapping of the ECG signal prior to device implantation is essential, as are adjustments to the sensitivity settings during follow-up visits.<sup>15</sup> In our patient, there were many inappropriate automatic recordings. Diagnosis was made in the first three months following device implantation by evaluating patient-activated ECG recording data after a syncopal episode.

A diagnostic modality that requires the recurrence of a spontaneous event involves the risk of patient injury or death. The ability to determine an accurate diagnosis and avoid a probably ineffective therapeutic intervention in the event of misdiagnosis outweighs this low risk. Taking into consideration the unpredictability and low frequency of syncope recurrences, the ILR provides the unique advantage of continuous ECG monitoring until the next recurrence and recording of heart rhythm during a syncopal episode, thus allowing the establishment or exclusion of an arrhythmic cause of syncope.

Cost issues have been addressed by several centers. The comprehensive diagnostic workup in patients with recurrent syncope consumes significant healthcare resources. In a study comparing costs, taking into account the diagnostic yield of various diagnostic modalities, diagnostic yield ranged from 3% for echocardiography to 88% for the ILR.<sup>16</sup> The ILR may reduce healthcare resource utilization by providing a diagnosis that permits definitive therapy. Optimal patient selection is the key to improving the effectiveness of every therapeutic intervention.

### Conclusion

Patients with recurrent syncope frequently undergo extensive investigations with significant implications for the utilization of healthcare resources. Recent advances in long-term ECG monitoring techniques have enhanced the diagnostic yield in patients with infrequent symptoms. The ILR permits a syncope-heart rhythm correlation in a high percentage of patients (45-80%). This investigative tool is associated with improved patient prognosis and quality of life, as well as healthcare resource savings.

### References

1. Crawford M, Bernstein S, Deedwania P, et al. ACC/AHA guidelines for ambulatory electrocardiography: Executive summary and recommendations. A report of the American College of Cardiology/American Heart Association Task Force on Practice Guidelines. *Circulation*. 1999; 100: 886-893.
2. Boersmaa L, Mont L, Sionis A. Value of the implantable loop recorder for the management of patients with unexplained syncope. *Europace*. 2004; 6: 70-76.
3. Kapoor WN, Karpf M, Wieand S, et al. A prospective evaluation and follow-up of patients with syncope. *N Engl J Med*. 1983; 309: 197-204.
4. Brignole M. Vasovagal syncope and vasovagal disease. *Hellenic J Cardiol*. 2008; 49: 61-64.
5. Kapoor WN. Diagnostic evaluation of syncope. *Am J Med*. 1991; 90: 91-106.
6. Kapoor WN, Hanusa BH. Is syncope a risk factor for poor outcomes? Comparison of patients with and without syncope. *Am J Med*. 1996; 100: 646-655.
7. Krahn AD, Klein GJ, Norris C. Final results from pilot study with an implantable loop recorder to determine the etiology of syncope in patients with negative noninvasive and invasive testing. *Am J Cardiol*. 1998; 82: 117-119.
8. Krahn AD, Klein GJ, Yee R, et al. Use of an extended monitoring strategy in patients with problematic syncope. *Circulation*. 1999; 99: 406-410.
9. Moya A, Brignole M, Menozzi C, et al. Mechanism of syncope in patients with isolated syncope and in patients with tilt-positive syncope. *Circulation*. 2001; 104: 1261-1267.
10. Styliadis IH, Mantziari AP, Gouzoumas NI, et al. Indications for permanent pacing and pacing mode prescription from 1989 to 2006. Experience of a single academic centre in Northern Greece. *Hellenic J Cardiol*. 2008; 49: 155-162.
11. Seidl K, Rameken M, Breunung S, et al. Diagnostic assessment of recurrent unexplained syncope with a new subcutaneously implantable loop recorder. *Europace*. 2000; 2: 256-262.
12. Sarasin FP, Junod AF, Carballo D, et al. Role of echocardiography in the evaluation of syncope: a prospective study. *Heart*. 2002; 88: 363-367.
13. The Task Force on Syncope, European Society of Cardiology. Guidelines on Management (Diagnosis and Treatment) of Syncope – Update 2004. *Europace*. 2004; 6: 467-537.
14. Nierop P, van Mechelen R, van Elsacker A, et al. Heart rhythm during syncope and presyncope: Results of implantable loop recorders. *Pacing Clin Electrophysiol*. 2000; 23: 1532-1538.
15. Ng E, Stafford PJ, Ng GA. Arrhythmia detection by patient and auto-activation in implantable loop recorders. *J Interv Card Electrophysiol*. 2004; 10: 147-152.
16. Krahn AD, Klein GJ, Yee R, et al. The high cost of syncope: cost implications of a new insertable loop recorder in the investigation of recurrent syncope. *Am Heart J*. 1999; 37: 870-877.

