

## Review Article

# Study of Atheromatous Plaque Using Intravascular Ultrasound

ELIAS A. SANIDAS<sup>1</sup>, MANOLIS VAVURANAKIS<sup>1</sup>, THEODOROS G. PAPAIOANNOU<sup>1</sup>, STÉPHANE CARLIER<sup>2</sup>, GEORGE SYROS<sup>2</sup>, GEORGE DANGAS<sup>2</sup>, CHRISTODOULOS STEFANADIS<sup>1</sup>

<sup>1</sup>1st Department of Cardiology, Hippokration Hospital, Medical School, National & Kapodistrian University of Athens, Greece; <sup>2</sup>New York Presbyterian Hospital/Columbia University Medical Centre, New York, USA

## Key words:

**Atherosclerosis, vulnerable plaque, vasa vasorum, neovascularisation, imaging.**

Manuscript received:  
February 1, 2008;  
Accepted:  
May 28, 2008.

## Address:

Manolis Vavuranakis

1st Dept. of Cardiology,  
Hippokration Hospital,  
114 Vas. Sophias Ave.  
115 28 Athens, Greece  
e-mail:  
[vavouran@otenet.gr](mailto:vavouran@otenet.gr)

**T**he increasing incidence of metabolic risk factors in the modern world makes it reasonable to predict that atheromatous cardiovascular disease will become the primary cause of death worldwide by 2020.<sup>1</sup> An understanding of the factors that influence the natural history of atherosclerosis and its complications is essential for the future development of strategies for prevention and therapeutic intervention. The use of intravascular ultrasound for imaging atheromatous plaque is of special interest in this regard. Here we review a large number of relevant clinical and experimental studies.

## Introduction

For more than four decades, angiography has been the most common imaging method used for the detection of coronary artery disease. Its widespread clinical application has steered patients to a host of beneficial interventional medical therapies. While the number of coronary arteries affected is an predictive index for the clinical outcome of the disease,<sup>2</sup> coronary angiography does not provide adequate prognostic information concerning future ischaemic events.

More specifically, previous studies have reported that coronary angiography performed after an acute myocardial infarction

reveals culprit lesions of only mild or moderate degree in more than half the patients.<sup>3</sup> Such conclusions have given rise to the notion that acute ischaemic syndromes are the result of how 'vulnerable' an atherosclerotic plaque is to undergoing rupture, and are less dependent on the degree of luminal stenosis.<sup>4</sup>

It is well known that the rupture of coronary atherosclerotic plaques and the consequent thrombosis are the main cause of acute coronary episodes. The basic mechanisms that lurk behind the break up of atherosclerotic plaque are the rupture of the fibrous cap that covers the lipid core and the exposure and erosion of the surface of the endothelium.<sup>5</sup>

The factors that determine the instability and the probability of rupture of an atheromatous plaque are mainly the progressive accumulation of lipids and the weakening of the fibrous cap. At the same time, equal importance is assigned to the role of inflammation and the accumulation of macrophages, in combination with collagen dissolution and inadequate epithelisation.

Coronary angiography provides a two-dimensional image of the arterial lumen, but it does not visualise the arterial wall on which the largest part of the plaque is located. In addition, angiography detects intraluminal stenoses that are expressed as a per-

centage of the diameter of the lumen in a reference section that is apparently healthy, but in which there may really be atheromatous plaque. Consequently, angiography often underestimates the degree of intraluminal stenosis and does not gauge the size of the plaque itself.<sup>6</sup>

Despite this limitation, quantitative coronary angiography has been adopted by various investigators as a way of evaluating the effect of treatment on the rate of progression of obstructive disease.<sup>7</sup> Thus, the inability of angiography to give us a precise quantitative determination of the atheroma burden limits its usefulness in research into those factors that affect the natural history of atherosclerosis.

### Intravascular ultrasound

Intravascular ultrasound (IVUS) provides real-time, high-resolution images of the coronary arteries. As a diagnostic imaging tool, it provides a precise depiction of the morphology of atheromatous plaque.

The function of IVUS is based on the following general principles:

1. Conversion of electrical energy into sound waves via piezoelectric crystals;
2. Transmission and detection of sound waves reflected by tissues using a transducer;
3. Conversion of sound waves into electrical energy;
4. Amplification and processing of the electrical energy and conversion to an image;
5. Projection of that image on the device's computer screen, from where it can be analysed or stored.

Recently, new developments in the post-processing of the IVUS raw signal (radiofrequency signal) have offered improved methods for the determination of the composition of atherosclerotic plaque.

IVUS allows the evaluation of the severity of stenoses, calculation of the vessel's diameter, as well as the precise determination of the boundaries of atheromatous plaque.<sup>8</sup> The contribution of IVUS to the assessment of intermediate regions in the main artery is also invaluable.<sup>9,10</sup> For these reasons, IVUS was a major factor in the design and the guidance of percutaneous procedures and to the recognition of their possible complications.<sup>11-13</sup>

### Advantages and limitations of IVUS

Nowadays, we obtain high-definition images of the lumen and the entire arterial wall using high-frequency catheters (30-40 MHz and recently 45 MHz). IVUS

should be preceded by the administration of anticoagulants and intravenous nitrates in order to avoid vasospasm. Clinical studies have shown that IVUS can be performed with absolute safety and has a low incidence of side effects (mainly local vasospasm), of the order of 1%.<sup>14,15</sup>

Despite the usefulness of ultrasound imaging for our understanding of the structure and function of the coronary arteries, some significant limitations must be noted. IVUS entails an invasive procedure. In consequence, the conclusions of clinical studies that used IVUS can only be applied to the patient with coronary artery disease who is undergoing an invasive examination. Conventional imaging with IVUS offers only a limited characterisation of the composition of atheromatous plaque. A significant increase in image resolution will be needed before regional changes in plaque composition can be evaluated precisely. Unfortunately, conventional IVUS with grey-scale imaging is unable to detect the characteristic histomorphological features that are associated with the rupture of vulnerable plaques, as follows: a large, and lipid-rich necrotic core; a thin and inflamed fibrous cap, rich in macrophages, that covers the necrotic core; and neovascularisation (vasculogenesis with microvessels).<sup>5,16-19</sup>

Although Yamagishi et al proposed that large, eccentric plaques with a superficial echogenic region on IVUS show an elevated risk of future rupture,<sup>20</sup> Prati et al reported that agreement between two independent observers as to the imaging of an echogenic region was only 0.68, while sensitivity for the detection of a histologically confirmed lipid pool was only 65%.<sup>21</sup>

Also, conventional IVUS cannot evaluate the characteristic histomorphological features of atheromatous plaques that are correlated with their rupture, and it has significant limitations in discriminating, for example, between fibrous and lipid plaques.<sup>22,23</sup> Thus, attention has focused more on the composition of atheromatous plaque and the connection between it and the probability of rupture.

### *From grey-scale IVUS imaging to processing of the radiofrequency signal*

Conventional IVUS imaging provides only a crude discrimination between lipids, fibrous tissue, and calcification. Processing the IVUS radiofrequency signal is a new method for a more precise characterisation of the composition of atheromatous plaque. Recent technological developments in the analysis of the IVUS radiofrequency signal (radiofrequency backscatter with

IVUS) allow a quantitative determination of the components of atheromatous plaque.<sup>24</sup>

A conventional IVUS grey-scale image is formed from a codification of the degree of echogenicity of the radiofrequency signal that is reflected by the tissues. Signals with low echogenicity are coded as dark grey or black, while highly echogenic signals are coded as light grey or white. All the information about frequency and phase is lost during this process.

A spectroscopic analysis is essential for recording all the different forms of ultrasound signal. This additional information can be calculated from the radiofrequency signal using tools such as the Fourier transform or autoregressive modelling.<sup>25</sup> The spectrum must first be normalised and then analysed to derive various parameters.<sup>26</sup> The combination of these parameters in an attempt to present an ultrasound tissue classification was first described in the context of examinations of the eye and abdominal organs.<sup>27</sup> A number of investigators seized upon this idea for the tissue classification of plaque using IVUS. It thus became possible to distinguish between different densities of fibrous tissue, as well as between lipid and other types of plaque, by applying this special analysis.

Using the classification of atheromatous plaques based on the criteria of the American Heart Association, Stahr et al compared IVUS radiofrequency analysis with histology in 32 atheromatous coronary arteries.<sup>28</sup> The more complex and complicated lesions gave more high-powered signals at all frequencies, compared with the early or intermediate lesions. Discrimination using this method had a sensitivity of 93% and a specificity of 79%. In contrast, in the analysis made with conventional IVUS this discrimination was very difficult: the best sensitivity in the diagnosis of early and intermediate lesions applied only to the 'soft' plaques and was 63%, with sensitivity 73%.

Early reports have described a reduction in the lipid components and an increase in fibrous tissue after statin therapy.<sup>29</sup> In similar cases, computerised tomography<sup>30</sup> and magnetic resonance imaging<sup>31</sup> only provide a partial analysis of the composition of atheromatous plaque. The increase in signal resolution required for the visualisation of the coronary arteries would provide an ideal opportunity to evaluate the change in plaque composition *in vitro* and using non-invasive techniques.

### **Alternative methods of imaging via IVUS**

Kawasaki et al first described a tissue classification scheme based only on the analysis of the integrated

backscatter (IB) signal, using a simple surface scanner on carotid samples.<sup>32</sup> This methodology was taken further by the integrated, rotating, 40 MHz IVUS catheter from Boston Scientific (Fremont CA, USA). IB-IVUS was applied to 18 samples of coronary artery and the results were compared with the corresponding histological findings. The resulting IB-IVUS values were divided into 5 categories so that coded colour maps could be constructed: thrombus; intimal hyperplasia or lipid core; fibrous tissue; mixed lesions; and calcification. The initial comparisons between angiography and IB-IVUS showed that the angioscopically coloured surface of the plaque reflected the thickness of the fibrous cap more than the size of the lipid core.<sup>33</sup> More recent comparisons of IVUS, IB-IVUS, and optical coherence tomography with histopathology showed that the sensitivity of IB-IVUS in the classification of calcification, fibrous tissue, and lipids was 100%, 94% and 84%, while specificity was 99%, 84% and 97%, respectively. An IB-IVUS system is available for clinical use in Japan (YD Co., Ltd., Tokyo).

Palpography is an alternative method of processing the radiofrequency signal for the determination of the elastic properties of plaques that are susceptible to rupture.<sup>34</sup> This method evaluates the local mechanical properties of the tissue using the distortion caused by intraluminal pressure. Of course, the clinical significance of this technique still remains to be investigated.<sup>35,36</sup>

Yet another method, which uses spectroscopic analysis of the raw radiofrequency signal obtained by conventional IVUS, is that of virtual histology. Essentially, this is a special piece of software that 'converts' the black and white signal of IVUS into a colour picture, marking the components of atherosclerotic plaque with different colours and so providing the opportunity for an *in vivo* evaluation of its morphology.<sup>37</sup>

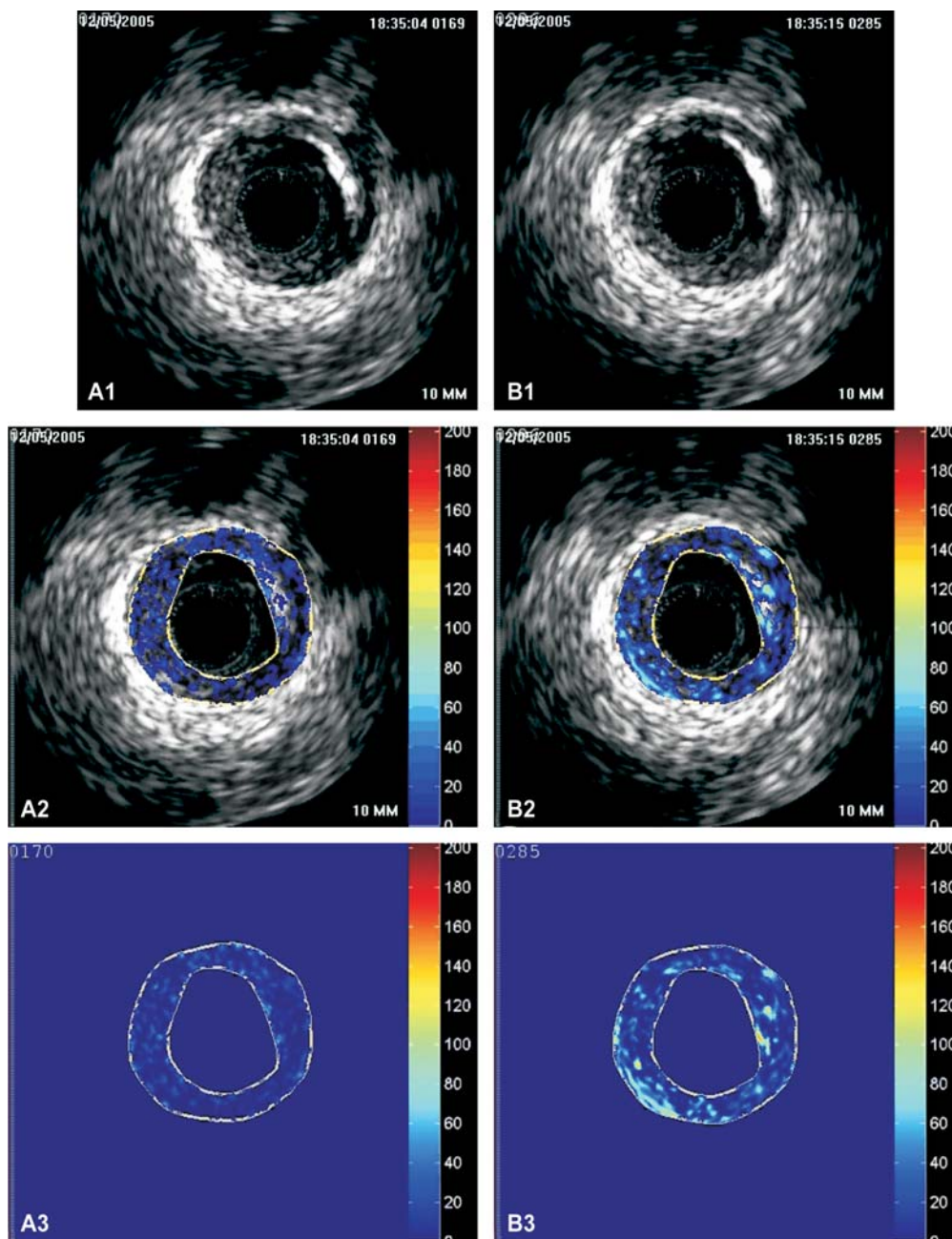
A recently reviewed comparison of palpography and virtual histology IVUS showed that the mean value of strain was greater in those IVUS cross sections in which the necrotic core was in contact with the lumen.<sup>38</sup>

### **The Greek experience**

From January 2005 to January 2006 we studied 30 patients who were admitted to the 1st Department of Cardiology, Hippokraton Hospital, Athens, suffering from acute coronary syndromes. The aim of the study was the *in vivo* detection of neovascularisation in coronary atheromatous plaques using contrast-enhanced IVUS (microbubbles).

All recorded video loops were analysed digitally using special image analysis software (ACES™ - Analysis of Contrast-Enhanced Sequences, CBL, Houston TX, USA), in order to evaluate quantitatively and qualitatively the density of neovascularity.<sup>39</sup> In all patients, the infusion of contrast microbubbles caused an increase in the echogenicity of selected regions on the IVUS images that included atheromatous plaques,

though to a different degree in each case (Figure 1). This method was able to record qualitatively and quantitatively the flow (presence) of microbubbles in human atheromatous plaques, mainly within the microvessels and neovascularity, using software specially developed for this purpose.<sup>40</sup> Further developments and improvements in this technique, supported by more clinical studies, could establish it in the future as an important



**Figure 1.** Analysis of an image obtained by intravascular ultrasound (IVUS) using the ACES™ system, before (A) and after (B) the infusion of contrast microbubbles. 1) Initial IVUS image; 2) IVUS image from the region of the plaque under analysis; 3) result of processing without the original image.

new method for the evaluation of vulnerable atherosclerotic plaque via the quantitative and qualitative analysis of neovascularisation.

### Studies of atheromatous plaque using IVUS

A number of recent studies have shown the value of IVUS in the evaluation of the composition and development of atheromatous plaque. Various investigators studied non-significant coronary artery stenosis over the long term (6-18 months). It is important to note the difference between limited observational studies and randomised, placebo-controlled trials, taking into account the statistical methods, the sample sizes, and the reproducibility of the measurements.

Ishikawa et al<sup>41</sup> studied 40 patients using three-dimensional volumetric IVUS, which detected a significant reduction in atheroma burden (from  $50 \pm 31$  to  $40 \pm 27$  mm<sup>3</sup>,  $p < 0.0001$ ) after 6 months' hypolipidaemic therapy (pravastatin 12-20 mg). The changes in the volume of the atheroma burden were negatively correlated with the increase in high-density lipoprotein (HDL) cholesterol, but were not correlated with changes in total or low-density lipoprotein (LDL) cholesterol. In 40 male patients with hypercholesterolaemia and ischaemic heart disease, Jensen et al<sup>42</sup> showed using three-dimensional IVUS that the atheroma burden was reduced significantly by 6.3% ( $p = 0.002$ ) after 12 months' therapy with simvastatin (40-80 mg, titrated to achieve an LDL cholesterol level  $< 120$  mg/dL). Although the reported changes in mean volume were extremely significant, these studies were methodologically inadequate because they lacked a control group. The changes observed could also have been due to a variety of other causes, apart from the statin therapy.

One study that must be mentioned was that of von Birgelen et al, who used IVUS to investigate the development of mild atheromatous plaques in the main coronary arteries of 60 patients. Over a follow-up period of  $18.3 \pm 9.4$  months, the development of the atheromatous plaques was correlated positively with LDL cholesterol levels and negatively with HDL cholesterol levels. The analysis predicted no annual increase in plaque size when LDL cholesterol was below the limit of 75 mg/dL.<sup>43</sup> The investigators also made a comparative evaluation of the development of atheromatous plaque and the reduction in lumen size in the same group of patients, using 3 established risk scores for primary prevention (PROCAM, SCORE, Framingham). The results showed a positive linear correlation between the estimated risk of clinical events, as given by

all 3 risk scores, and the probability of atheromatous plaque development as measured by IVUS.<sup>44,45</sup>

### Randomised trials

In the GAIN study (German Atorvastatin IVUS Investigators)<sup>46</sup> the researchers compared hypolipidaemic therapy with atorvastatin ( $n = 48$ , target LDL cholesterol  $< 100$  mg/dL) with a common regimen that included other hypolipidaemic drugs ( $n = 51$ ). Within a 12-month period, the plaque volumes of mild coronary lesions did not change significantly (change  $2.5 \pm 24.9\%$  with atorvastatin vs.  $11.8 \pm 31.0\%$  with usual treatment,  $p = 0.138$ ). However, a significant difference was recorded in the echogenicity of the plaque, an indirect index of plaque composition (change in echogenicity  $42.2 \pm 97.8\%$  for patients randomised to atorvastatin, versus  $10.1 \pm 68.5\%$  for those on usual treatment,  $p = 0.021$ ).

The ESTABLISH study included 70 patients with an acute coronary syndrome.<sup>47</sup> After percutaneous coronary intervention and IVUS in a non-culprit lesion, the patients were randomised to intensive hypolipidaemic therapy ( $n = 35$ , atorvastatin) or a control group ( $n = 35$ ). The atheroma burden, which was measured again after six months' follow up, was significantly lower in the patients taking statins ( $13.1 \pm 12.8\%$  decrease versus  $8.7 \pm 14.9\%$  increase,  $p < 0.0001$ ). Furthermore, the percentage change in plaque volume was positively correlated with LDL cholesterol levels ( $r = 0.456$ ), even in the patients who had low LDL cholesterol before the start of treatment.

The REVERSAL study (Reversal of Atherosclerosis with Aggressive Lipid Lowering) was a double-blind, randomised, multi-centre study in which the results of two different statins (atorvastatin and pravastatin) were compared over 18 months' administration. The percentage change in atheroma burden seen via IVUS showed a significantly lower rate of plaque development in the group receiving intensive atorvastatin therapy ( $p = 0.02$ ). The occurrence of coronary artery disease – which was the primary endpoint – was significant in the pravastatin group (2.7%,  $p = 0.001$ ), compared to the baseline value before the start of therapy. Significant progression of atheromatous disease was not seen in the atorvastatin group (0.4%,  $p = 0.98$ ), compared with the baseline value.<sup>48</sup>

In the CAMELOT study, Nissen et al compared the results of amlodipine and enalapril versus placebo, with regard to the development of atheromatous plaque studied by IVUS over 24 months, in a sub-study of 274 patients with coronary artery disease.<sup>49</sup>

The amlodipine group showed a trend towards less disease progression compared with placebo ( $p=0.12$ ), with significantly less progression in the subgroup with above average systolic blood pressure ( $p=0.02$ ). In comparison with the baseline values, IVUS showed progression of atheromatous disease in the placebo group ( $p<0.001$ ), an increasing trend in the enalapril group, and no significant change in the amlodipine group ( $p=0.31$ ).

## Conclusions

During the last two decades there have been many important developments with respect to coronary angiography and IVUS. However, with the standard approach using coronary angiography and IVUS, the morphological evaluation of atheromatous plaque is limited, prohibiting the precise determination of which plaques are susceptible to rupture, thus causing an acute coronary syndrome. New developments, based on processing of the IVUS radiofrequency signal, offer new possibilities for the plaque classification and tissue identification.

Current large, multi-centre studies will determine whether these new parameters become established for the detection of vulnerable plaque and the classification, with high precision, of changes in their composition that occur as the result of new therapies. Perhaps of paramount importance is the early diagnosis of a plaque that is susceptible to rupture, as the first step towards targeting therapy to high-risk patients, with a view to preventing the occurrence of an acute coronary syndrome.

## References

- Murray CJ, Lopez AD. Global mortality, disability, and the contribution of risk factors: Global Burden of Disease Study. *Lancet*. 1997; 349: 1436-1442.
- Ringqvist I, Fisher LD, Mock M, et al. Prognostic value of angiographic indices of coronary artery disease from the Coronary Artery Surgery Study (CASS). *J Clin Invest*. 1983; 71: 1854-1866.
- Ambrose JA, Tannenbaum MA, Alexopoulos D, et al. Angiographic progression of coronary artery disease and the development of myocardial infarction. *J Am Coll Cardiol*. 1988; 12: 56-62.
- Schroeder AP, Falk E. Vulnerable and dangerous coronary plaques. *Atherosclerosis*. 1995; 118 (Suppl.): S141-149.
- Schwartz SM, Virmani R, Rosenfeld ME. The good smooth muscle cells in atherosclerosis. *Curr Atheroscler Rep*. 2000; 2: 422-429.
- Topol EJ, Nissen SE. Our preoccupation with coronary luminal findings in ischemic heart disease. *Circulation*. 1995; 92: 2333-2342.
- Ballantyne CM. Clinical trial endpoints: angiograms, events, and plaque instability. *Am J Cardiol*. 1998; 82: 5M-11M.
- Niessen S. Application of intravascular ultrasound to characterize coronary artery disease and assess the progression or regression of atherosclerosis. *Am J Cardiol*. 2002; 89 (Suppl.): 24B-31B.
- Sano K, Mintz GS, Carlier SG, et al. Assessing intermediate left main coronary lesions using intravascular ultrasound. *Am Heart J*. 2007; 154: 983-988.
- Lazaros G, Tsiamis E, Metallinos G, Stefanadis C. Ulcerated atheromatous plaque of the left main coronary artery in a patient with a recent extensive anterior myocardial infarction. *Hellenic J Cardiol*. 2007; 48: 108-109.
- Nakamura S, Colombo A, Gaglione A, et al. Intracoronary ultrasound observations during stent implantation. *Circulation*. 1994; 89: 2026-2034.
- Regar E, Klauss V, Werner F, et al. Quantitative changes in reference segments during IVUS-guided stent implantation: impact on the criteria for optimal stent expansion. *Catheter Cardiovasc Interv*. 1999; 47: 434-440.
- Colombo A, Hall P, Nakamura S, et al. Intracoronary stenting without anticoagulation accomplished with intravascular ultrasound guidance. *Circulation*. 1995; 9: 1676-1688.
- Guedes A, Keller PF, L'Allier PL, Lesperance J, Gregoire J, Tardif JC. Long-term safety of intravascular ultrasound in nontransplant, nonintervened, atherosclerotic coronary arteries. *J Am Coll Cardiol*. 2005; 45: 559-564.
- Ramasubbu K, Schoenhagen P, Balgith MA, et al. Repeated intravascular ultrasound imaging in cardiac transplant recipients does not accelerate transplant coronary artery disease. *J Am Coll Cardiol*. 2003; 41: 1739-1743.
- Falk E. Plaque rupture with severe pre-existing stenosis precipitating coronary thrombosis. Characteristics of coronary atherosclerotic plaques underlying fatal occlusive thrombi. *Br Heart J*. 1983; 50: 127-134.
- Burke AP, Farb A, Malcom GT, Liang YH, Smialek J, Virmani R. Coronary risk factors and plaque morphology in men with coronary disease who died suddenly. *N Engl J Med*. 1997; 336: 1276-1282.
- Toutouzas K, Stefanadis C. Advances in vulnerable plaque detection and treatment: how far have we gone? *Hellenic J Cardiol*. 2006; 47: 129-131.
- Stefanadis C, Toutouzas K, Stefanadi E, Kolodgie F, Virmani R, Kipshidze N. First experimental application of bevacizumab-eluting PC coated stent for inhibition of vasa vasorum of atherosclerotic plaque: angiographic results in a rabbit atheromatic model. *Hellenic J Cardiol*. 2006; 47: 7-10.
- Yamagishi M, Terashima M, Awano K, et al. Morphology of vulnerable coronary plaque: insights from follow-up of patients examined by intravascular ultrasound before an acute coronary syndrome. *J Am Coll Cardiol*. 2000; 35: 106-111.
- Prati F, Arbustini E, Labellarte A, et al. Correlation between high frequency intravascular ultrasound and histomorphology in human coronary arteries. *Heart*. 2001; 85: 567-570.
- Hiro T, Leung CY, De Guzman S, et al. Are soft echoes really soft? Intravascular ultrasound assessment of mechanical properties in human atherosclerotic tissue. *Am Heart J*. 1997; 133: 1-7.
- Erbel R, Ge J, Gorge G, et al. Intravascular ultrasound classification of atherosclerotic lesions according to American

- Heart Association recommendation. *Coron Artery Dis.* 1999; 10: 489-499.
24. Nair A, Kuban BD, Tuzcu EM, Schoenhagen P, Nissen SE, Vince DG. Coronary plaque classification with intravascular ultrasound radiofrequency data analysis. *Circulation.* 2002; 106: 2200-2206.
  25. Nair A, Kuban BD, Obuchowski N, Vince DG. Assessing spectral algorithms to predict atherosclerotic plaque composition with normalized and raw intravascular ultrasound data. *Ultrasound Med Biol.* 2001; 27: 1319-1331.
  26. Nair A, Calvetti D, Vince DG. Regularized autoregressive analysis of intravascular ultrasound backscatter: improvement in spatial accuracy of tissue maps. *IEEE Trans Ultrason Ferroelectr Freq Control.* 2004; 51: 420-431.
  27. Coleman DJ, Lizzi FL. Computerized ultrasonic tissue characterization of ocular tumors. *Am J Ophthalmol.* 1983; 96: 165-175.
  28. Stahr PM, Hofflinghaus T, Voigtlander T, et al. Discrimination of early/intermediate and advanced/complicated coronary plaque types by radiofrequency intravascular ultrasound analysis. *Am J Cardiol.* 2002; 90: 19-23.
  29. Kawasaki M, Sano K, Okubo M, et al. Volumetric quantitative analysis of tissue characteristics of coronary plaques after statin therapy using three-dimensional integrated backscatter intravascular ultrasound. *J Am Coll Cardiol.* 2005; 45: 1946-1953.
  30. Leber AW, Becker A, Knez A, et al. Accuracy of 64-slice computed tomography to classify and quantify plaque volumes in the proximal coronary system: a comparative study using intravascular ultrasound. *J Am Coll Cardiol.* 2006; 47: 672-677.
  31. Worthley SG, Helft G, Fuster V, et al. A novel nonobstructive intravascular MRI coil: in vivo imaging of experimental atherosclerosis. *Arterioscler Thromb Vasc Biol.* 2003; 23: 346-350.
  32. Kawasaki M, Takatsu H, Noda T, et al. Noninvasive quantitative tissue characterization and two-dimensional color-coded map of human atherosclerotic lesions using ultrasound integrated backscatter: comparison between histology and integrated backscatter images. *J Am Coll Cardiol.* 2001; 38: 486-492.
  33. Kawasaki M, Takatsu H, Noda T, et al. In vivo quantitative tissue characterization of human coronary arterial plaques by use of integrated backscatter intravascular ultrasound and comparison with angioscopic findings. *Circulation.* 2002; 105: 2487-2492.
  34. Schaar JA, Regar E, Mastik F, et al. Incidence of high-strain patterns in human coronary arteries: assessment with three-dimensional intravascular palpography and correlation with clinical presentation. *Circulation.* 2004; 109: 2716-2719.
  35. Schaar JA, de Korte CL, Mastik F, et al. Intravascular palpography for high-risk vulnerable plaque assessment. *Herz.* 2003; 28: 488-495.
  36. Schaar JA, van der Steen AFW, Mastik F, Baldewsing RA, Serruys PW. Intravascular palpography for vulnerable plaque assessment. *J Am Coll Cardiol.* 2006; 47: 86-91.
  37. Sangiorgi GM, Clementi F, Cola C, Biondi-Zoccai G. Plaque vulnerability and related coronary event prediction by intravascular ultrasound with virtual histology: "It's a long way to Tipperary"? *Catheter Cardiovasc Interv.* 2007; 70: 203-210.
  38. Rodriguez-Granillo GA, Agostoni P, Garcia-Garcia HM, de Feyter P, Serruys PW. In-vivo, cardiac-cycle related intimal displacement of coronary plaques assessed by 3-D ECG-gated intravascular ultrasound: exploring its correlate with tissue deformability identified by palpography. *Int J Cardiovasc Imaging.* 2006; 22: 147-152.
  39. Vavuranakis M, Papaioannou TG, Kakadiaris I, et al. Detection of perivascular blood flow in vivo by contrast-enhanced intracoronary ultrasonography and image analysis: an animal study. *Clin Exp Pharmacol Physiol.* 2007; 34: 1319-1323.
  40. Vavuranakis M, Kakadiaris IA, O'Malley SM, et al. A new method for assessment of plaque vulnerability based on vasa vasorum imaging, by using contrast enhanced intravascular ultrasound and differential image analysis. *Int J Cardiol.* 2008; 130: 23-29.
  41. Ishikawa K, Tani S, Watanabe I, et al. Effect of pravastatin on coronary plaque volume. *Am J Cardiol.* 2003; 92: 975-977.
  42. Jensen LO, Thayssen P, Pedersen KE, Stender S, Haghfelt T. Regression of coronary atherosclerosis by simvastatin: a serial intravascular ultrasound study. *Circulation.* 2004; 110: 265-270.
  43. Von Birgelen C, Hartmann M, Mintz GS, Baumgart D, Schermund A, Erbel R. Relation between progression and regression of atherosclerotic left main coronary artery disease and serum cholesterol levels as assessed with serial long-term (> or =12 months) follow-up intravascular ultrasound. *Circulation.* 2003; 108: 2757-2762.
  44. Von Birgelen C, Hartmann M, Mintz GS, et al. Relationship between cardiovascular risk as predicted by established risk scores versus plaque progression as measured by serial intravascular ultrasound in left main coronary arteries. *Circulation.* 2004; 110: 1579-1585.
  45. Dangas G, Mintz GS, Mehran R, et al. Preintervention arterial remodeling as an independent predictor of target-lesion revascularization after nonstent coronary intervention: an analysis of 777 lesions with intravascular ultrasound imaging. *Circulation.* 1999; 99: 3149-3154.
  46. Schartl M, Bocksch W, Koschyk DH, et al. Use of intravascular ultrasound to compare effects of different strategies of lipid-lowering therapy on plaque volume and composition in patients with coronary artery disease. *Circulation.* 2001; 104: 387-392.
  47. Okazaki S, Yokoyama T, Miyauchi K, et al. Early statin treatment in patients with acute coronary syndrome: demonstration of the beneficial effect on atherosclerotic lesions by serial volumetric intravascular ultrasound analysis during half a year after coronary event: the ESTABLISH Study. *Circulation.* 2004; 110: 1061-1068.
  48. Nissen SE, Tuzcu EM, Schoenhagen P, et al. Effect of intensive compared with moderate lipid-lowering therapy on progression of coronary atherosclerosis: a randomized controlled trial. *JAMA.* 2004; 291: 1071-1080.
  49. Nissen SE, Tuzcu EM, Libby P, et al. Effect of antihypertensive agents on cardiovascular events in patients with coronary disease and normal blood pressure: the CAMELOT study: a randomized controlled trial. *JAMA.* 2004; 292: 2217-2225.