

## Case Report

## Synchronous Left Ventricular Myxoma and Malignant Fibrous Histiocytoma: Simultaneous Surgical Management

NIKOLAOS BARBETAKIS<sup>1</sup>, THEOCHARIS XENIKAKIS<sup>2</sup>, ANDREAS EFSTATHIOU<sup>3</sup>,  
GEORGE SAMANIDIS<sup>1</sup>, CHRISTODOULOS TSILIKAS<sup>1</sup>, IOANNIS FESSATIDIS<sup>3</sup>

Cardiothoracic Surgery Departments: <sup>1</sup>Theagenio Cancer Hospital, Thessaloniki, <sup>2</sup>University of Crete, Heraklion, <sup>3</sup>Geniki Kliniki, Thessaloniki, Greece

Key words:

**Myxoma,  
histiocytoma,  
synchronous tumours.**

The occurrence of synchronous but unrelated cardiac and soft tissue tumours is extremely rare. Here we describe the case of a 62-year-old man who had a left ventricular myxoma and an unrelated synchronous malignant fibrous histiocytoma. The patient first underwent successful resection of the soft tissue tumour and in the same session emergency resection of the cardiac mass under cardiopulmonary bypass. One year after this combined operation, the patient is well, with no recurrence of either tumour.

Manuscript received:  
March 20, 2008;  
Accepted:  
June 24, 2008.

Address:  
Theocharis Xenikakis

Cardiosurgery Dept.  
Heraklion University  
Hospital  
71110 Voutes,  
Heraklion  
Crete, Greece  
e-mail:  
[tgxenikakis@yahoo.gr](mailto:tgxenikakis@yahoo.gr)

**M**yxomas account for 50% of all primary cardiac tumours.<sup>1</sup> Although the number of asymptomatic intracardiac tumours being detected has increased along with the widespread use of echocardiographic examinations, left ventricular myxomas are still rare and are often diagnosed following a history of syncope episodes caused by left ventricular outflow tract obstruction, or systemic embolisation resulting in cerebral or myocardial infarction.

Malignant fibrous histiocytoma, described by O'Brien and Stout in 1964, is the most common soft tissue sarcoma of late adult life. The occurrence of synchronous but unrelated cardiac and soft tissue tumours is extremely rare. Here we describe the case of a 62-year-old man who had a left ventricular myxoma and an unrelated synchronous malignant fibrous histiocytoma of the thigh and underwent a combined successful resection.

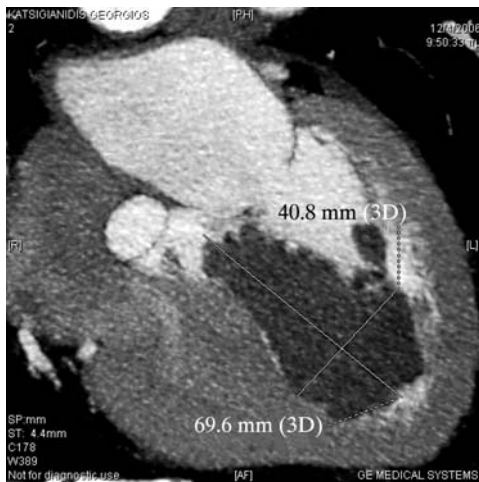
### Case presentation

A 62-year-old man was admitted to our hospital with an enlarged, painless soft tissue

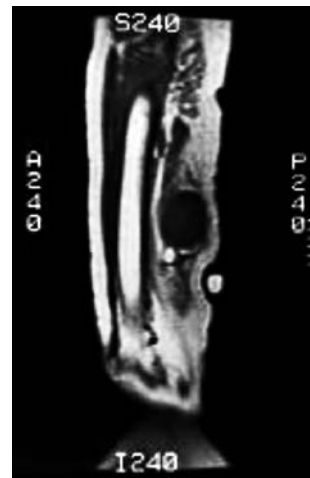
mass in the right thigh and a 2-month history of exertional faintness. On admission the patient appeared to be well-nourished and healthy. On physical examination, he was found to have a harsh systolic murmur in the third and fourth intercostal spaces and left sternal edge. Transthoracic echocardiography demonstrated a large mass in the left ventricular cavity, extending into the outflow tract with a systolic prolapse through the aortic valve. Computed tomography (CT) of the chest revealed a cardiac tumour (69.6 × 40.8 mm) within the left ventricle (Figure 1).

For preoperative staging of the thigh tumour, the patient underwent CT scans of the abdomen, brain, and a bone scan. T1-weighted magnetic resonance imaging of the thigh, obtained following intravenous gadolinium administration, revealed an inhomogeneous enhancement of the soft tissue mass (Figure 2). A preoperative biopsy was taken and confirmed the presence of a classic storiform-pleomorphic malignant fibrous histiocytoma (Figure 3).

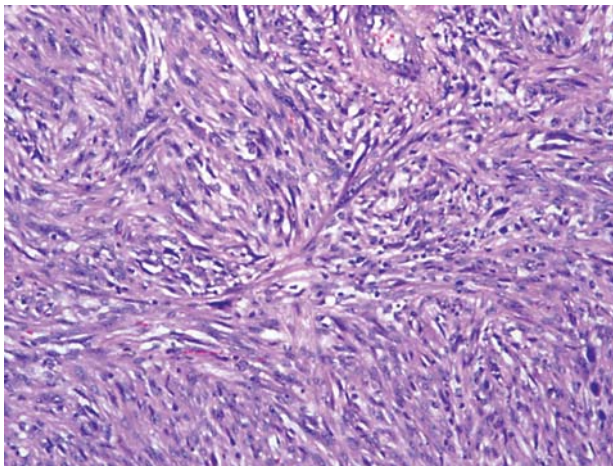
In view of the risk of a complete obstruction of the left ventricular outflow tract the patient was immediately taken for a



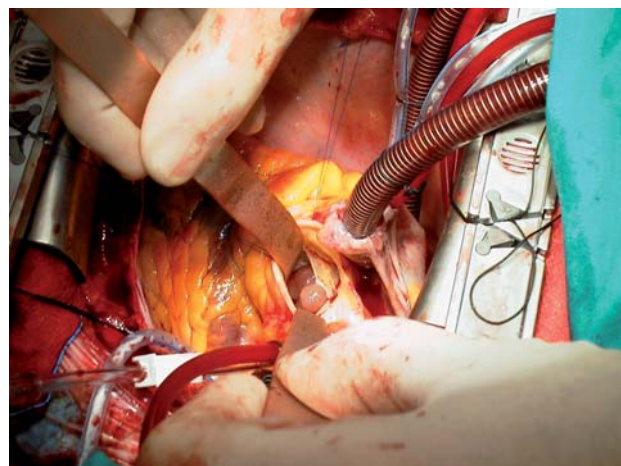
**Figure 1.** Computed tomography of the chest demonstrated a large mass in the left ventricular cavity, extending into the outflow tract.



**Figure 2.** Magnetic resonance imaging showing inhomogeneous enhancement of the soft tissue mass in the thigh.



**Figure 3.** Preoperative biopsy confirmed the presence of a classic storiform-pleomorphic malignant fibrous histiocytoma.



**Figure 4.** A huge, fragile, jelly-like myxoma became visible in the left ventricular cavity through an oblique aortotomy.

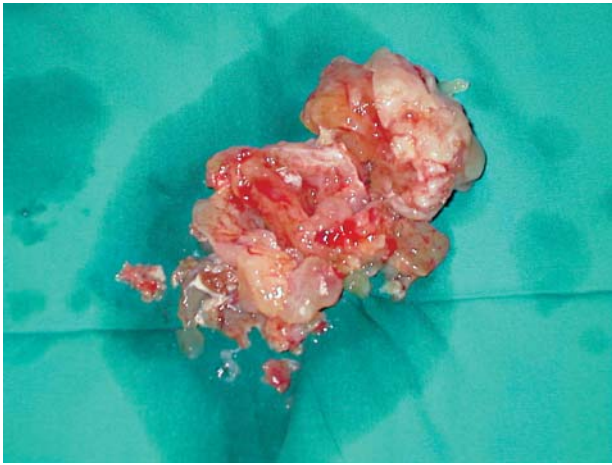
combined excision of both tumours. Initially the soft tissue tumour was excised by means of a compartmentectomy with margins free of tumour invasion. The second step was to remove the cardiac tumour. After median sternotomy and full heparinisation, cardiopulmonary bypass was instituted through bicaval and aortic cannulation. The heart was arrested, and through an oblique aortotomy a huge, fragile, jelly-like myxoma became visible in the left ventricular cavity (Figure 4).

Sufficient tissue was resected at the base of the tumour stalk to achieve complete resection of the mass with minimal likelihood of recurrence (Figure 5). Histological examination demonstrated the typical features of a myxoma and there was no evidence of invasion in

the cross section of the resected myocardium. The patient had an uneventful postoperative course and no evidence of recurrence has been seen for either tumour 12 months later.

### Discussion

Left ventricular myxomas are extremely rare, accounting for 2.5-4% of all cases.<sup>2</sup> To our knowledge, there are no previously published papers that describe the synchronous occurrence of a left ventricular myxoma with a malignant fibrous histiocytoma of the thigh. There is no established association between cardiac myxomas and soft tissue tumours. Of interest, however,



**Figure 5.** The resected left ventricular myxoma.

is the fact that, regardless of the type of cancer, the incidence of second and third neoplasms in cancer patients is higher than can be accounted for by chance alone.<sup>3</sup>

Malignant fibrous histiocytoma, first described by O'Brien and Stout in 1964, is the best known soft tissue tumour. Surgery is the cornerstone of treatment and its goal is to eradicate all disease in the affected area. For extremity sarcomas, surgical options fall into two categories: limb-sparing and amputation. Several studies have demonstrated no difference in patient survival with amputation versus limb-salvage. Currently, at least 90% of tumours are now removed using limb-sparing surgery.<sup>4</sup> In regard to the relationship between the surgical margin and local recurrence, an adequately wide procedure for the primary tumour has prevented local recurrence. In the curative procedure the tumour is resected more than 5 cm distant from the tumour margin at the non-barrier site.<sup>4</sup> Local recurrence after a curative procedure was seen only in patients with regional lymph node metastases.<sup>4</sup>

In this case, our decision was to treat the patient in one stage. Cardiopulmonary bypass has a substantial risk of postoperative bleeding from excessive heparinisation or inadequate heparin neutralisation. Platelet

function is also impaired due to passage through the extracorporeal circuit. In addition, the effects of cardiopulmonary bypass on tumour growth and dissemination in patients with coexisting malignant disease are still unknown. Cardiopulmonary bypass causes a transient perioperative depression of immune function, which could provide a window for malignant growth and dissemination.<sup>5</sup> By performing simultaneous procedures and resecting the tumour prior to the institution of cardiopulmonary bypass we thought that we could minimise these effects.

An alternative approach would be to deal with the two comorbidities in two stages, with the cardiac tumour first on line. However, the staged procedure involves the cost and morbidity of two separate operations. Also, the unavoidable delay in malignant fibrous histiocytoma resection could allow time for tumour growth and possible dissemination.

Simultaneous urgent cardiac surgery and soft tissue malignant tumour resection was safe and not associated with increased early or late morbidity and mortality. A combined procedure, when possible, avoids the need for a second procedure with a good oncological outcome.

## References

1. Kawano H, Tayama K, Akasu K, Komesu I, Fukunaga S, Aoyagi S. Left ventricular myxoma: report of a case. *Surg Today*. 2000; 1112-1114.
2. Natale E, Minardi G, Casali G, Pulignano G, Musumeci F. Left ventricular myxoma originating from the interventricular septum and obstructing the left ventricular outflow tract. *Eur J Echocardiogr*. 2008; 9: 84-85.
3. Nuno I, Kang T, Arroyo H, Starnes V. Synchronous cardiac myxoma and colorectal cancer. *Tex Heart Inst J*. 2001; 28: 215-217.
4. Matsumoto S, Ahmed AR, Kawaguchi N, Manabe J, Matsuhita Y: Results of surgery for malignant fibrous histiocytomas of soft tissue. *Int J Clin Oncol*. 2003; 8: 104-109.
5. Toker A, Dilege S, Kalayci G. Combined left pneumonectomy and off-pump coronary artery bypass: Principles of cancer surgery. *Eur J Cardiothorac Surg*. 2001; 19: 226-228.