

Case Report

Massive Pulmonary Embolism and Ulcerative Colitis

NIKOLAOS V. KAFKAS, CHRISTOS C. DEBONERAS, DIMITRIOS K. BABALIS

Cardiology Department, KAT General Hospital, Athens, Greece

Key words:

Pulmonary embolism, inflammatory bowel disease.

We describe the case of a patient with ulcerative colitis who suffered a pulmonary embolism that caused shock. Despite the high risk of haemorrhagic complications given the underlying disease, thrombolytic treatment was administered with a good result. Deep vein thrombosis in the lower limbs and pulmonary embolism are the most common thromboembolic phenomena in patients with inflammatory bowel disease. The inflammatory and thrombotic processes are connected, creating a vicious circle. Inflammatory bowel disease predisposes to thromboembolic episodes, while thrombosis, if not the initial cause, is at least implicated in maintaining the inflammatory process in ulcerative colitis and Crohn's disease.

Manuscript received:

April 10, 2008;

Accepted:

June 24, 2008.

Address:

Nikolaos V. Kafkas

18 Mar. Antypas St.
14121 Heraklio Attikis
Greece
e-mail:
kafkasncard@yahoo.gr

Thromboembolic complications of inflammatory bowel disease (IBD), of ulcerative colitis, and of Crohn's disease were first described in 1936.¹ Deep vein thrombosis of the lower limbs and pulmonary embolism are the most common thromboembolic phenomena seen in patients with IBD.² However, cases have been reported of thrombosis in other veins and arteries, particularly venous thromboses,³ as well as cases of thrombophlebitis migrans.⁴ On the other hand, it has been suggested that thrombosis and ischaemia are involved in the pathogenesis of both ulcerative colitis and Crohn's disease. The inflammatory and thrombotic processes are connected, creating a vicious circle whose pathophysiological mechanism is unclear. IBD predisposes to thromboembolic episodes, while thrombosis, if not the initial cause, is at least implicated in maintaining the inflammatory process in IBD.⁵⁻⁷

Case presentation

A man aged 43 years came to our department because of dyspnoea on effort that had progressively worsened over three days. He

had a history of ulcerative colitis, diagnosed by colonoscopy and biopsy of the end section of the large bowel four years previously. For two months the patient had been under treatment with prednisolone and mesalazine in daily dosages of 5 mg and 750 mg, respectively, with periodic remission of the disease.

The clinical examination on admission showed a rhythmic, rapid, and narrow arterial pulse; blood pressure was 90/70 mmHg and heart rate was 135/min. The patient exhibited tachypnoea (22 breaths/min) and diaphoresis. Peripheral pulses were equally palpable at all sites. The lower limbs showed no oedema and the skin had a normal temperature, without rubor or cyanosis. Auscultation of the lungs revealed a small reduction in the respiratory murmur bilaterally. On cardiac auscultation the heart sounds were distinct, with audible third and fourth sounds and an accentuated pulmonary second sound. In a 45° reclining position there was an increase in the pulse amplitude in the internal jugular. The hypochondrial organs were not palpable.

The ECG (Figure 1) showed sinus rhythm at a rate of 135/min. Chest X-ray in the

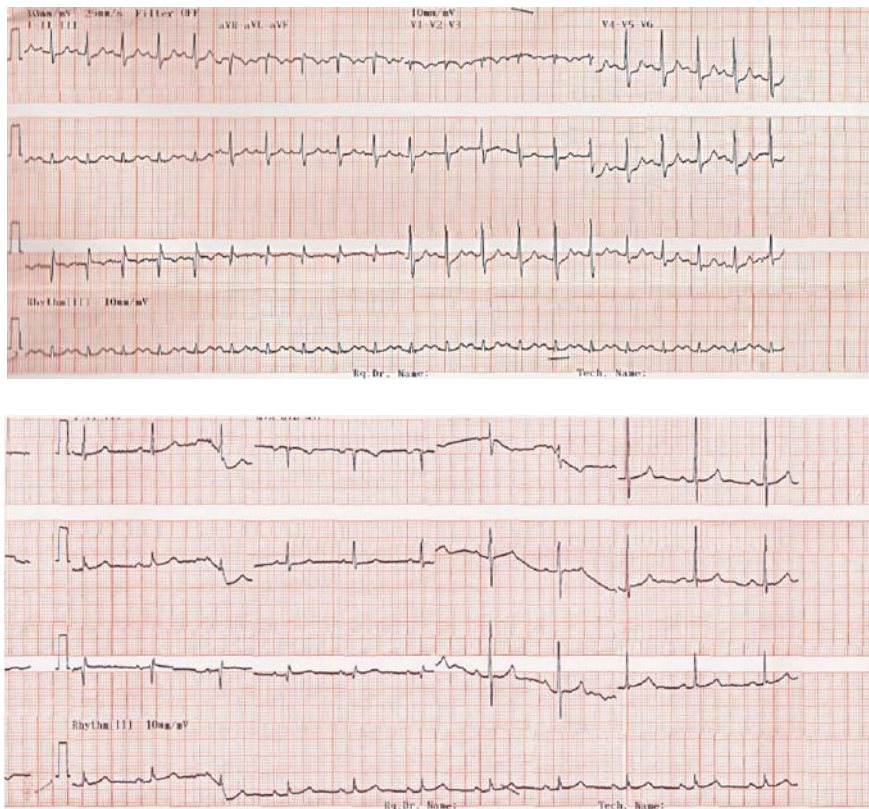


Figure 1. ECG on admission (upper) and after thrombolysis (lower).

postero-anterior projection showed normal cardiac dimensions and protrusion of the left pulmonary artery conus. Blood gases showed hypoxaemia and hypocapnia. On the transthoracic echocardiogram (Figure 2) the right ventricle was enlarged and had a significant degree of hypokinesia of its free wall, with a concomi-

tant change in its triangular structure; systolic pulmonary artery pressure, estimated from the tricuspid valve regurgitation, was 60 mmHg.

The patient's history, clinical and other examinations were strongly suggestive of pulmonary embolism, so a computed tomographic examination with intra-

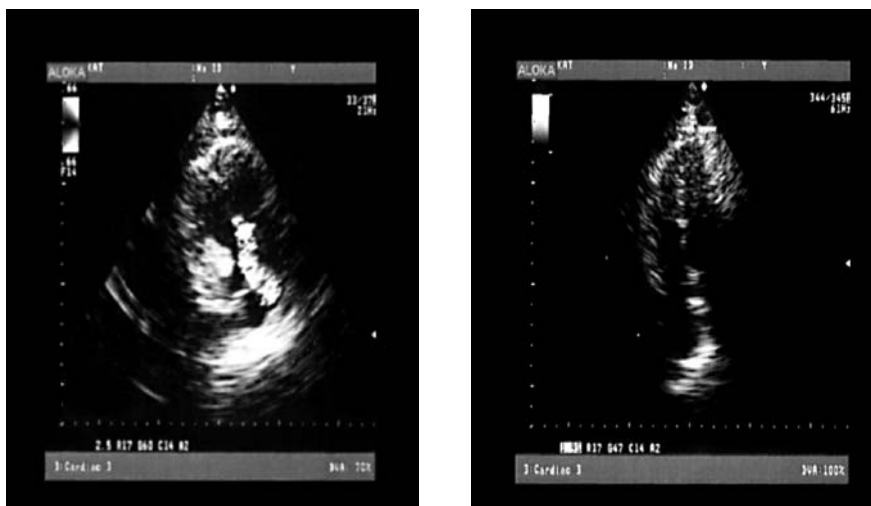


Figure 2. Echocardiogram on admission (left) and after thrombolysis (right). The first image shows hypokinesia of the right ventricular free wall and tricuspid valve regurgitation, which are both improved after therapy.

venous administration of contrast medium was scheduled (Figure 3). This revealed the presence of filling defects in the main branches of the pulmonary arteries bilaterally, in segmental and lobular branches, but no pleuritic fluid accumulation or swollen lymph glands. An ultrasound examination of the lower limb vasculature found deep vein thrombosis of the right sural veins.

The laboratory tests on admission showed: Ht: 42%, Hb: 13.8 g/dl, WBC: 8600 /mm³ (Poly: 65%, Lymph: 28%, Mon: 5%), PLT: 287000 /mm³, ESR: 31 mm/h, BNP: 325 pg/ml, CPK: 56 U/L, troponin-I: 0.03 ng/ml, fibrinogen: 0.85 g/l, D-dimer: 5.0 mg/l, CRP: 0.924 mg/dl. Other values were normal.

Given the diagnosis and the patient's haemodynamic instability, thrombolysis with alteplase was initiated (100 mg over 2 hrs), as well as anticoagulation therapy with intravenous standard heparin (aiming at a partial thromboplastin time of 2-2.5 times the control value), while at the same time prednisolone was continued at the same low dosage the patient had been taking for months. The ECG, echocardiogram, and computed tomography image after thrombolysis are shown in Figures 1-3. Computed tomography of the chest showed a clear reduction in filling defects in the main branches of the pulmonary artery, resulting in a reduction in the haemodynamic load of the right ventricle and correspondingly in heart rate. The patient responded to treatment without presenting any complications and after his improvement was discharged in good general condition, taking coumarin anticoagulants according to the guidelines for the treatment and prevention of pulmonary embolism.

Discussion

The literature reports three cases of thrombolysis in patients with IBD who had deep vein thrombosis and/or massive pulmonary embolism;⁸⁻¹⁰ in one case a transfusion was required because of massive haemorrhage.¹⁰

Hypercoagulability is rare, but has been demonstrated in patients with ulcerative colitis and Crohn's disease, where it leads to thromboembolic complications (deep vein thrombosis, pulmonary embolism) with a mortality rate of around 25%.¹¹ The incidence of thromboembolic episodes varies from study to study.¹²⁻¹⁴ In clinical studies the rate ranges from 1-8%, whereas in *post mortem* studies it is 41%.¹⁵ This difference may be due to the fact that *post mortem* studies can detect subclinical thromboembolic episodes. In a study by the Mayo clinic of 7199 patients with IBD, 92 (1.3%) had thromboembolic episodes, of which 66 (0.9%) were deep vein thrombosis or pulmonary embolism.¹¹ Two recent studies confirmed the increased incidence of thromboembolic episodes in patients with IBD, finding that these patients had a threefold risk of deep vein thrombosis or pulmonary embolism compared to the general population.^{12,16} Bernstein et al calculated the incidence of deep vein thrombosis or pulmonary embolism as 40/10,000 person-years for patients with Crohn's disease and 50/10,000 person-years for patients with ulcerative colitis.¹⁶ The same study found that the greatest relative increase in thromboembolic episodes was observed in patients under 40 years old. Miehsler et al made a comparison between patients with IBD and those with other inflammatory dis-

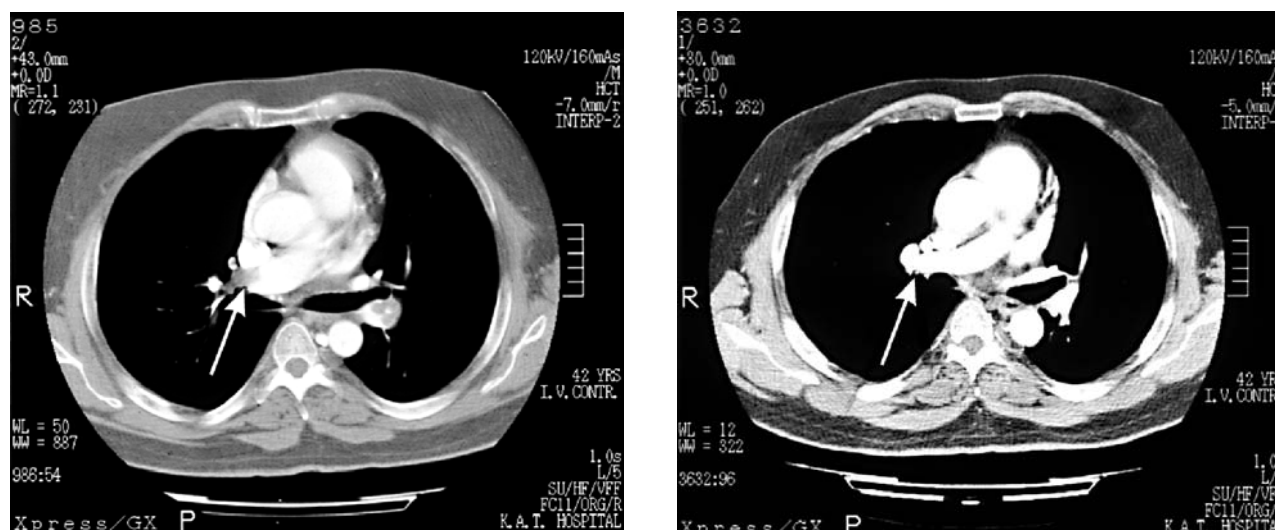


Figure 3. Computed tomography of the chest on admission (left) and after thrombolysis (right).

eases (rheumatoid arthritis, coeliac disease) and found that the latter groups had fewer thromboembolic episodes.¹²

Active IBD (versus inactive) may be a risk factor for thromboembolism, since active disease is associated with increased coagulability.^{14,17} However, one third of thromboembolic complications occur in patients with non-active disease.¹⁴ Our patient was in the active phase of IBD.

The disturbances that lead to thrombosis are the result of inherited or acquired anomalies. Many of these disturbances are connected with IBD and in at least one third of IBD patients who suffer a thromboembolic complication a prothrombotic anomaly is found.¹⁷ Moreover, one study of 116 patients with IBD found that they did not have just one prothrombotic anomaly, but a combination of acquired and inherited abnormalities.¹⁸ It should be noted that these patients often show other factors that predispose to thrombosis, such as sweating, immobility, and a need for surgical intervention. The disturbances of the haemostatic mechanism that are seen in patients with IBD are shown in Table 1. Many of these disturbances are related to whether the disease is active or not and have many causes.¹⁵ For example, hyperhomocysteinaemia predisposes to thrombosis and patients with IBD have a higher incidence of hyperhomocysteinaemia than do healthy volunteers.¹⁹ Hyperhomocysteinaemia can be due to a variety of causes, such as a deficiency of vitamin B12 or B6 (usual in patients with IBD),²⁰ and treatment with sulphasalazine or methotrexate.^{21,22}

Also important is the role of disorders of the endothelium and the reduction in its anticoagulant action that is seen in these patients. It has not yet been fully determined whether such disorders are the cause or the result of the inflammatory process.¹⁵

Cytokines play a primary role in the pathogenesis of IBD and have a significant effect on the coagulation cascade. They may contribute to the prothrombotic state in these patients.²³ Tissue necrotic factor reduces protein C and elevates tissue factor and von Willebrand factor. Interleukin-1 elevates tissue factor and reduces proteins C and S. Interleukin-6 promotes thrombocytosis.^{23,24}

The interaction between inflammation and haemostasis affects not only the coagulation mechanism but also platelet function, where increased activation is seen.¹³ Spontaneous platelet aggregation *in vitro* is observed in 30% of patients with IBD, but not at all in healthy volunteers. In addition, collagen, arachidonic acid, and adenosine diphosphate cause more exag-

Table 1. Disturbances of the haemostatic mechanism in patients with inflammatory bowel disease.

Coagulation disturbances:	
• Fibrinogen	↑
• Factor V	↑
• Factor VIII	↑
• Factor IX	↑
• Factor XIII	↓
• Protein S	↓
• Antithrombin III	↓
• Tissue factor	↑
• Thrombomodulin	↓
• Urokinase type plasminogen activator	↑
Fibrinolysis abnormalities:	
• Plasminogen activator inhibitors	↑
Platelet disorders:	
• Thrombocytosis	
• Increased platelet activation and aggregation	
• Platelet-leukocyte aggregates	↑
Endothelial disorders:	
• von Willebrand factor	↑
• Endothelial antibodies	↑
Possible dietary factors:	
• Homocysteine	↑
• Lipoprotein alpha	↑

gerated platelet activation in patients with active IBD than in healthy controls. An index of platelet activation is CD40 ligand factor, which is elevated in patients with IBD. Factor CD40L has prothrombotic properties and plays a role in thrombus stabilisation; elevated levels of CD40L are a risk factor for vascular episodes.²⁶

Studies have shown that platelets and leukocytes are more strongly activated when linked together than when separate. Platelet-leukocyte aggregates are elevated in patients with unstable coronary syndromes,²⁷ systemic *lupus erythematosus*, and rheumatoid arthritis.²⁸ Finally, patients with IBD have been found to have a larger number of platelet-leukocyte aggregates,²⁹ which probably contribute to thromboembolic phenomena via an increase in thrombus creation in their systemic circulation and the increased production of tissue factor.

The therapeutic management of these patients is difficult because of the spontaneous haemorrhages they can exhibit. Massive haemorrhage is seen in 3% of patients with ulcerative colitis and requires emergency colectomy. Haemorrhage persists in 12% even after surgery.³⁰

The glucosaminoglycans are known to have anti-inflammatory properties and they facilitate the action of growth factors that are essential for mucosal regenera-

tion and repair.³¹ For that reason, heparin has been suggested for the treatment of ulcerative colitis, but its role is controversial. Two main studies addressed this matter; the first³² showed a benefit from unfractionated heparin, whereas the second not only failed to show a benefit but found an increase in haemorrhage.³³ The difference between the studies was that in the first the patients were taking mesalazine, as was our patient, while in the second they were not. Low molecular weight heparins do not appear to have a place in the treatment armamentarium for ulcerative colitis.³⁴ In general, preventive heparin administration is recommended in patients with IBD who are admitted to hospital and remain in a reclining posture for a prolonged period, so that good hydration and rapid mobilisation are essential.³⁵

Thrombolytic agents have been used in patients with active ulcerative colitis and massive pulmonary embolism¹⁰ or deep vein thrombosis.^{8,9} In general, thrombolysis is a life saver to patients who are in cardiogenic shock because of pulmonary embolism, and the contraindications for thrombolytic agents become relative under such circumstances.³⁶ Even patients with pulmonary embolism, normal blood pressure, but right ventricular dysfunction, benefit from thrombolysis.^{37,38} Thrombolysis facilitates right ventricular function by breaking up anatomical obstructions, prevents the release of serotonin and other neurohormonal factors that exacerbate pulmonary hypertension, and dissolves thrombi in the lower limbs, reducing the probability of recurrence of pulmonary embolism.

The use of coumarin anticoagulants requires great care in active IBD, because of the risk of causing large haemorrhage.⁹ On the other hand, the co-administration of sulphasalazine or azathioprine increases resistance to coumarin anticoagulants,³⁹ while the use of glucocorticoids reduces the organism's fibrinolytic action and predisposes to thrombosis.

In conclusion, proinflammatory and prothrombotic conditions often coexist. Thrombosis and inflammation are associated to a significant degree, creating a vicious circle whose pathophysiological mechanism has not yet been fully elucidated.⁴⁰ The treatment of patients with active ulcerative colitis and massive pulmonary embolism poses a challenge to the treating physician. In massive pulmonary embolism the significance of contraindications to thrombolysis or other therapeutic interventions is relative and must be weighed against the extreme urgency of the indication.

References

1. Bargen J, Barker N. Extensive arterial and venous thrombosis complicating chronic ulcerative colitis. *Arch Intern Med.* 1936; 58: 17-31.
2. Jackson LM, O'Gorman PJ, O'Connell J, Cronin CC, Cotter KP, Shanahan F. Thrombosis in inflammatory bowel disease: clinical setting, procoagulant profile and factor V Leiden. *Q J Med.* 1997; 90: 183-188.
3. Jain S, Bhatt P, Muralikrishna K, Malhotra P, Kumari S, Varma S. Extensive arterial and venous thrombosis in a patient with ulcerative colitis-A case report. *General Medicine.* 2005; 7: 10.
4. Elliott HL. Thrombophlebitis migrans: a further systemic complication of ulcerative colitis. *Postgrad Med J.* 1980; 56: 207-208.
5. Hatoum OA, Binion DG, Otterson MF, et al. Acquired microvascular dysfunction in inflammatory bowel disease: loss of nitric oxide-mediated vasodilation. *Gastroenterology.* 2003; 125: 58-69.
6. Crespo I, Murphy J, Wong RK. Superior mesenteric venous thrombosis masquerading as Crohn's disease. *Am J Gastroenterol.* 1994; 89: 116-118.
7. Dhillon AP, Anthony A, Sim R, et al. Mucosal capillary thrombi in rectal biopsies. *Histopathology.* 1992; 21: 127-133.
8. Pogliani EM, Bozzan A, Radaelli F. Thrombolytic therapy for venous thrombosis in patients with gastrointestinal diseases. *Pharmatherapeutica.* 1982; 3: 268-273.
9. Van Vanwoert JH, Thomson RC, Cangemi JR, Metzger PP, Blackshear JL, Fleming CR. Streptokinase therapy for extensive venous thrombosis in a patient with severe ulcerative colitis. *Mayo Clinic Proc.* 1990; 65: 1144-1149.
10. Elikowski W, Malec M, Lawandowska M. Massive pulmonary embolism in a patient with ulcerative colitis and hyperhomocysteinaemia-a case report. *Kardio Pol.* 2006; 64: 405-409.
11. Talbot RW, Heppell J, Dozois RR, Beart RW. Vascular complications of inflammatory bowel disease. *Mayo Clin Proc.* 1986; 61: 140-145.
12. Miehsler W, Reinisch W, Valic E, et al. Is inflammatory bowel disease an independent and disease specific risk factor for thromboembolism? *Gut.* 2004; 53: 542-548.
13. Webberley MJ, Hart MT, Melikian V. Thromboembolism in inflammatory bowel disease: role of platelets. *Gut.* 1993; 34: 247-251.
14. Novotny DA, Rubin RJ, Slezak FA, et al. Arterial thromboembolic complications of inflammatory bowel disease: report of three cases. *Dis Colon Rectum.* 1992; 35: 193-196.
15. Irving P, Pasi J, Rampton D. Thrombosis and inflammatory bowel disease. *Clin Gastroenterol Hepatol.* 2005; 3: 617-628.
16. Bernstein C, Blanchard J, Houston D, Wajda A. The incidence of deep venous thrombosis and pulmonary embolism among patients with inflammatory bowel disease: A population-based cohort study. *Thromb Haemost.* 2001; 85: 430-434.
17. Solem CA, Loftus EV, Tremaine WJ, et al. Venous thromboembolism in inflammatory bowel disease. *Am J Gastroenterol.* 2004; 99: 97-101.
18. Magro F, Dinis-Ribeiro M, Araujo FM, et al. High prevalence of combined thrombophilic abnormalities in patients with inflammatory bowel disease. *Eur J Gastroenterol Hepatol.* 2003; 15: 1157-1163.
19. Cattaneo M, Vecchi M, Zighetti M, et al. High prevalence of hyperhomocysteinemia in patients with inflammatory bowel

- disease: a pathogenic link with thromboembolic complications? *Thromb Haemost.* 1998; 80: 542-545.
20. Saibeni S, Cattaneo M, Vecchi M, et al. Low vitamin B(6) plasma levels, a risk factor for thrombosis in inflammatory bowel disease: role of inflammation and correlation with acute phase reactants. *Am J Gastroenterol.* 2003; 98: 112-117.
 21. Haagsma CJ, Blom HJ, Van Riel PLCM, et al. Influence of sulphasalazine, methotrexate and the combination of both on plasma homocysteine concentrations in patients with rheumatoid arthritis. *Ann Rheum Dis.* 1999; 58: 79-84.
 22. Welch GN, Loscalzo J. Homocysteine and atherothrombosis. *N Engl J Med.* 1998; 338: 1042-1050.
 23. Joseph L, Fink LM, Hauer-Jensen M. Cytokines in coagulation and thrombosis: a preclinical and clinical review. *Blood Coagul Fibrinolysis.* 2002; 13: 105-116.
 24. Schafer AI. Thrombocytosis. *N Engl J Med.* 2004; 350: 1211-1219.
 25. Danese S, De la Motte C, Sturm A, et al. Platelets trigger a CD40-dependent inflammatory response in the microvasculature of inflammatory bowel disease patients. *Gastroenterology.* 2003; 124: 1249-1264.
 26. Schonbeck U, Varo N, Libby P, et al. Soluble CD40L and cardiovascular risk in women. *Circulation.* 2001; 104: 2266-2268.
 27. Furman MI, Barnard MR, Krueger LA, et al. Circulating monocyte-platelet aggregates are an early marker of acute myocardial infarction. *J Am Coll Card.* 2001; 38: 1002-1006.
 28. Joseph JE, Harrison P, Mackie JM, et al. Increased circulating platelet-leucocyte complexes and platelet activation in patients with antiphospholipid syndrome, systemic lupus erythematosus and rheumatoid arthritis. *Br J Haematol.* 2001; 115: 451-459.
 29. Irving PM, Macey MG, Webb L, et al. Formation of platelet-leucocyte aggregates in inflammatory bowel disease. *Inflamm Bowel Dis.* 2004; 10: 361-372.
 30. Robert JH, Sachar DB, Aufses AH, Greenstein AJ. Management of severe hemorrhage in ulcerative colitis. *Am J Surg.* 1990; 159: 550-555.
 31. Papa A, Danese A, Gasbarrini A, et al. Review article: potential therapeutic applications and mechanisms of action of heparin in inflammatory bowel disease. *Aliment Pharmacol Ther.* 2000; 14: 1403-1409.
 32. Ang YS, Mahmud N, White B, et al. Randomized comparison of unfractionated heparin with corticosteroids in severe active inflammatory bowel disease. *Aliment Pharmacol Ther.* 2000; 14: 1015-1022.
 33. Panes J, Esteve M, Cabre E, et al. Comparison of heparin and steroids in the treatment of moderate and severe ulcerative colitis. *Gastroenterology.* 2000; 119: 903-908.
 34. Bloom S, Kiilerich S, Lassen MR, et al. Low molecular weight heparin (tinzaparin) vs placebo in the treatment of mild to moderately active ulcerative colitis. *Aliment Pharmacol Ther.* 2004; 19: 871-878.
 35. Carter MJ, Lobo AJ, Travis SP. Guidelines for the management of inflammatory bowel disease in adults. *Gut.* 2004; 53 (Suppl 5): V1-V16.
 36. Task Force on Pulmonary Embolism of the European Society of Cardiology. Guidelines on diagnosis, management of acute pulmonary embolism. *Eur Heart J.* 2000; 21: 1301-1336.
 37. N. Kucher, CM Luder, T. Dornhofer, S. Windecker, B. Meier, OM Hess. Novel management strategy for patients with suspected pulmonary embolism. *Eur Heart J.* 2003; 24: 366-376.
 38. Kostadima E, Zakynthinos E. Pulmonary embolism: pathophysiology, diagnosis, treatment. *Hellenic J Cardiol.* 2007; 48: 94-107.
 39. Teefy AM, Martin JE, Kovacs MJ. Warfarin resistance due to sulfasalazine. *Ann Pharmacother.* 2001; 35: 506.
 40. Freeman HJ. Venous thromboembolism with inflammatory bowel disease. *World J Gastroenterology.* 2008; 14: 991-993.