

Case Report

Triple Valve Endocarditis as an Unusual Complication of Bacterial Meningitis

MARINA KONTOGIORGI¹, IOANNIS KOUKIS², MIHALIS ARGIRIOU², NIKOLAOS THEAKOS², VICTOR PANAGIOTAKOPOULOS², KONSTANTINOS KANAKAKIS², ANTONIA DIMAKOPOULOU³, CHRISTOS CHARITOS²

¹Intensive Care Unit, ²Cardiac Surgery Department, ³Anaesthesiology Department, "Evangelismos" General Hospital, Athens, Greece

Key words:

Drug abuser, meningitis, valve endocarditis.

We report a case of *Staphylococcus aureus* endocarditis with late onset in a 39-year-old male drug abuser, who presented with bacterial meningitis. Despite resolution of the meningitis as the result of appropriate antimicrobial chemotherapy he developed triple valve endocarditis. Some striking features of this case and a comparison with other reported cases of this uncommon presentation of infective endocarditis are discussed.

Manuscript received:
October 2, 2007;
Accepted:
March 11, 2008.

Address:
Michalis Argiriou

41, Aetideon St.
155 61 Holargos
Athens, Greece
e-mail:
mihalisargiriou@ath.forthnet.gr

Neurological complications continue to occur in approximately 20 to 40 percent of all patients with infective endocarditis (IE) and represent a major factor associated with an increased mortality rate.¹ Dissemination of infected emboli into cerebral or meningeal vessels can lead to meningitis or brain abscesses.² Not only did the case we report below have an atypical presentation – meningitis – but also infective endocarditis developed 12 days later, when resolution of meningitis was achieved. The atypical presentation highlights the difficulties in both the early diagnosis and the management of patients with IE.

Case presentation

A 39-year-old man, a drug abuser and hepatitis C positive, was admitted elsewhere for acute fever combined with neck stiffness and headache. He had been hospitalised 20 years before for acute meningitis. Apart from the above, no other symptoms were noted.

On clinical examination, the patient

was disoriented in time and space. His Glasgow Coma Scale (GCS) score was 14. No other findings were noted. The blood count showed leucocytosis and laboratory tests revealed low potassium and extremely elevated C-reactive protein (173 mg/dL). Immediately after his admission the patient was put on a four-drug empiric antibiotic regimen, with ceftriaxone, ampicillin/sulbactam, ciprofloxacin and clindamycin. However, he sustained further impairment of his neurological condition and developed high fever. His renal function remained normal. The cerebral computed tomography scan did not disclose any lesion. Based on the laboratory findings for cerebrospinal fluid (CSF) and the positive CSF culture for *Staphylococcus aureus*, bacterial meningitis was diagnosed. One day later, two blood cultures were found positive for *Staphylococcus aureus*. Transthoracic echocardiography was negative for endocardial lesions.

On the fifth hospital day the patient was intubated because of the deterioration of his mental status (GCS: 5/15) and he was admitted to the intensive care unit. Under

mechanical ventilation and appropriate antibiotic treatment his general condition improved and he was extubated 3 days later.

Twelve days after the beginning of symptoms, an aortic valve murmur was noted on clinical examination. The transthoracic ultrasound revealed vegetation at the aortic root. During the next 19 days the patient's mental state gradually improved but his cardiac function deteriorated, leading to heart failure (New York Heart Association [NYHA] class IV) and bilateral pleural effusions. Two more blood cultures were positive for *Staphylococcus aureus*. Ultrasound revealed the presence of vegetations on the ventricular surface of the aortic leaflets, enlargement of the left atrium and left ventricle (ejection fraction 45%), and enlargement of the right chambers. The aortic valve showed insufficiency (4+/4), as did the mitral (3+/4) and tricuspid (3+/4) valves. The systolic pulmonary artery pressure was 56 mmHg. Therefore, the patient was transferred to the cardiac surgical department for further evaluation and surgical treatment.

The patient underwent median sternotomy with total cardiopulmonary bypass. The mitral valve was degenerated and insufficient with vegetation oriented on the anterior leaflet (Figure 1). The aortic valve was

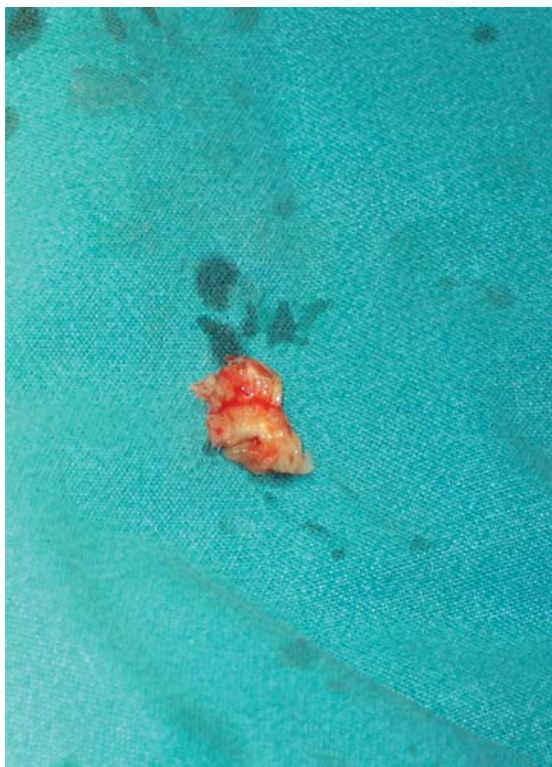

Figure 1. Vegetation on a section of the anterior mitral valve leaflet.

also degenerated with multiple vegetations on the right coronary and on the non-coronary leaflets (Figure 2). Under the non-coronary leaflet an abscess had formed. Finally, the tricuspid valve was also insufficient. The anterior leaflet of the mitral valve was removed but the posterior remained intact with subsequent preservation of the subvalvular apparatus. A 27 mm mechanical valve was installed. The aortic valve leaflets were removed and the abscess was debrided. Then the ventricular wall was sutured between Teflon felts, reinstalling the aortic ring. A mechanical bi-leaflet 19 mm valve was installed in the aortic position. Finally, the right atrium was opened and the tricuspid valve inspected. Its insufficiency was corrected with use of a 32 mm ring (Figure 3).

The patient was easily weaned from cardiopulmonary bypass and was transferred to the intensive care unit with rhythm control using a VVI pacemaker (90 /min) and catecholamine support. His general condition gradually improved. After 8 days, he was transmitted to a ward for further monitoring.

Discussion

This case is presented because of its rarity. There have

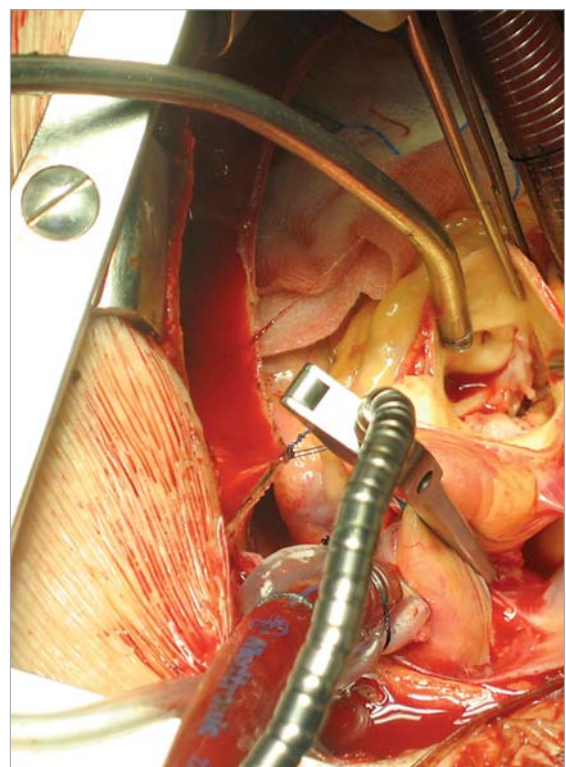


Figure 2. Aortic valve endocarditis.

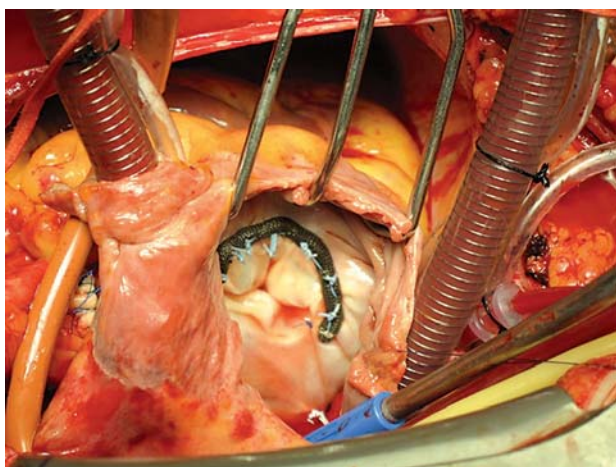


Figure 3. Tricuspid valvuloplasty.

not been any reported cases of staphylococcal meningitis complicated by subacute left-sided endocarditis of the aortic and mitral valves in a drug abuser.

Staphylococcal meningitis can be a complication of endocarditis, sinusitis and chronic purulent otitis media. It can also complicate peripheral infection sites, such as septic vein thrombosis and psoas muscle abscess, or even trauma such as cranio-cerebral injury and central nervous system (CNS) operations: i.e. foreign body use, ventriculoperitoneal shunts and intraspinal or intrathecal drug injections. In drug abusers, more than 30% of CNS infections are due to *Staphylococcus* species. In these patients, endocarditis comprises 8% of all acute infections, precedes meningitis, and always affects the right heart structures.¹

In the case presented, meningitis was the primary disease and endocarditis followed as a complication, as described above. The primary clinical signs and symptoms consisted of acute fever, neck stiffness, headache and mental disorders, all characteristic of bacterial meningitis. At presentation and during the next ten days there were no signs or symptoms of chronic endocarditis, such as murmurs, clubbing, hepatosplenomegaly or peripheral embolic disease. The murmur at auscultation developed ten days after the onset of the acute febrile disease. The isolation of the pathogen in CNS fluid and blood cultures happened at the same time. In fact the CNS fluid isolation preceded by a day.

The clinical response to treatment is worthy of notice. The symptoms of meningitis, especially the mental status of the patient, steadily improved from day to day, whereas his cardiac function worsened and led to NYHA IV heart failure. The endocarditis led to heart failure and rest dyspnoea over a period of 15 days; thus, it can be characterised as acute or subacute.

The site of endocardial infection is also uncommon. In drug abusers, the pathogens that cause endocarditis are usually sited in the right heart chambers and mostly affect the tricuspid valve.^{3,6} Damage to the right sided valves from injected particulate matter in the setting of injected bacterial loads is thought to be important, while subtle anomalies of immune function may also have a role in pathogenesis.⁵ Vegetations are then created on or under valve leaflets. Septic material from these vegetations can cause pulmonary infarction, pulmonary abscesses, bilateral pneumothorax, pleural effusion, empyema, or rarely, obstruction of the pulmonary arterial circulation due to pulmonary embolism. The valve dysfunction caused by leaflet destruction can lead to right atrioventricular enlargement and subsequent right heart failure.⁴ None of the above clinical manifestations were noted in the patient described here. On the contrary, the patient acutely developed left heart failure with profound dyspnoea. This was confirmed by cardiac ultrasound and during surgery. The aortic and mitral valves were affected, whereas the tricuspid regurgitation was merely the result of left heart failure.

There can be no sufficient explanation why the *Staphylococcus* affected and nearly destroyed the leaflets of the left heart valves only. The bacterium which caused the meningitis and was also isolated in blood cultures left the lungs intact, without affecting or infecting the pulmonary circulation. It also seems that the right heart failure was a direct result of the left heart valve regurgitation and was not due to vegetation or even destruction of the tricuspid valve leaflets. The only mechanism to explain the above adequately would be a patent *fossa ovalis*, combined with subclinical former left heart valve pathology.⁵ However these were not found in our patient.

Therefore, the two clinical manifestations can be connected with meningitis as the primary disease and left heart endocarditis as secondary complication of the subsequently developed bacteraemia. However, the hypothesis of simultaneous attack by *Staphylococcus* on both the meninges and left heart valves, due to an original bacteraemia caused by intravenous drug use cannot be overlooked.

References

1. Mylonakis E, Calderwood SB. Infective endocarditis in adults. *N Engl J Med*. 2001; 18: 1318-1330.
2. Hoen B, Alla F, Selton-Suty C, et al. Changing profile of infective endocarditis: results of a 1-year survey in France. *JAMA*. 2002; 1: 75-81.

3. Filippatos G, Argyriou M, Peppas C, Kranidis A, Kardaras F. Tricuspid valve endocarditis in a young cocaine user. *Minerva Cardioangiol.* 2002; 50: 399-400.
4. Heiro M, Nikoskelainen J, Engblom E, Kotilainen E, Martila R, Kotilainen P. Neurologic manifestations of infective endocarditis: a 17-year experience in a teaching hospital in Finland. *Arch Intern Med.* 2000; 18: 2781-2787.
5. Weisse AB, Heller DR, Schimenti RJ, Montgomery RL, Kapila R: The febrile parenteral drug user: A prospective study in 121 patients. *Am J Med.* 1993; 3: 274-280.
6. Parthenakis FI, Patrianakos AP, Anagnostopoulos SK, Kafarakis PK, Lyrarakis GM, Vardas PE. Bacterial endocarditis of the mitral valve with dual location. *Hellenic J Cardiol.* 2006; 47: 366-367.