

Case Report

High Power Radiofrequency Ablation of Incessant Atrioventricular Re-Entrant Tachycardia in a Patient with a Para-Hisian Accessory Pathway

ATHANASIOS A. KOTSAKIS, PANAGIOTIS N. MARGOS, ALEXANDROS S. STEFANIDIS,
DAMIANOS N. KOUVARAKOS, EVANGELOS G. PAPASTERIADIS

1st Department of Cardiology, "St. Panteleimon" General Hospital of Nikaia, Piraeus, Greece

Key words:

Para-Hisian accessory pathway, incessant supraventricular tachycardia, radiofrequency ablation.

Radiofrequency ablation is the interventional therapy of choice for the definitive cure of patients with tachycardias facilitated by accessory pathways. Ablation of an accessory pathway at sites close to the His bundle is inevitably associated with an increased risk of causing complete atrioventricular block. Here we describe the case of a patient with pre-excitation syndrome and episodes of supraventricular tachycardia, in whom an electrophysiological study identified an accessory pathway so close to the His bundle that discrete sites between the pathway and the His bundle were extremely difficult to find. After a first, unsuccessful attempt at ablation the patient developed incessant supraventricular tachycardia. The accessory pathway was successfully ablated in a second session using high power radiofrequency current, although this entailed a great increase in the risk of causing complete atrioventricular block.

Manuscript received:
March 27, 2007;
Accepted:
August 2, 2007.

Address:

Athanasios Kotsakis

*1st Department of
Cardiology
"St. Panteleimon"
General Hospital of
Nikaia,
3 D. Mantouvalou St
184 54 Nikaia
Piraeus, Greece
e-mail:
thanasisk@kmp.forthnet.gr*

Accessory atrioventricular (AV) pathways allow antegrade, retrograde or bidirectional conduction of an electrical stimulus between atria and ventricles. The existence of an accessory pathway facilitates the occurrence of episodes of AV re-entrant tachycardias, most commonly orthodromic AV re-entrant tachycardia (antegrade conduction via AV node and retrograde conduction via pathway) and more rarely antidromic AV re-entrant tachycardia (antegrade conduction via pathway and retrograde conduction via AV node).¹ Antegrade pathway conduction in sinus rhythm is associated with a typical ECG pattern (delta -wave, pre-excitation syndrome, Wolff- Parkinson-White syndrome).²

Ablation of accessory pathways with radiofrequency (RF) current is an extremely effective therapeutic method that has been dramatically improved over the last 15 years and has provided a definitive

cure to a large population of patients with paroxysmal supraventricular tachycardia, who used to be frequent visitors to hospital emergency rooms.^{3,4} Apart from the improvement in quality of life that ablation offers, it also aims at primary prevention of sudden cardiac death in the case of pathways that are capable of antegrade conduction and have a short refractory period. In such cases, the occurrence of paroxysmal atrial fibrillation poses the danger of ventricular fibrillation due to rapid (pre)excitation of the ventricles via the accessory pathway.⁵

A rather small percentage of accessory pathways are located in regions close to the AV node and the His bundle. These are the anteroseptal, midseptal, and para-Hisian pathways, the ablation of which entails an elevated risk of causing complete AV block.⁶⁻⁹

Here we present the clinically interesting case of a patient with pre-excitation

syndrome due to the existence of a para-Hisian accessory pathway, in whom the first, unsuccessful attempt at ablation caused a clinical deterioration, since it led to the appearance of incessant supraventricular tachycardia. A second ablation procedure was successful only after extremely high-energy RF current was used, a very risky action given the specific location of the pathway in close proximity to the His bundle.

Case description

A 33-year-old man presented to the emergency room of our hospital reporting tachycardia with sudden onset and termination, lasting about one hour. The admission ECG (Figure 1) showed sinus rhythm with pre-excitation, compatible with the presence of an anteroseptal accessory pathway, while the usual laboratory tests and echocardiographic examination gave results with normal values.

After giving written consent, the patient underwent an electrophysiological study (EPS) with insertion of recording electrodes in the right ventricular apex, high right atrium, coronary sinus, and the His bundle region. As shown in Figure 2, the His catheter recorded electrical activity from an accessory pathway, establishing that the pathway was very close to the His bundle, as well as a His-like wave (H'). The EPS showed that the pathway was capable of bidirectional conduction and had a short antegrade refractory period (220 ms), with inducible orthodromic AV re-entrant tachycardia having a right bundle branch

block configuration (Figure 3), as well as a self-terminating episode of atrial fibrillation with rapid ventricular response (Figure 4). From the interpretation of Figures 2 and 3, the H' wave was attributed initially to the electrical activity of the accessory pathway.

The subsequent mapping made it clear that the pathway was in the immediate vicinity of the His bundle. The patient was informed of both the need for ablation of the pathway (risk of sudden death during an episode of paroxysmal atrial fibrillation) and the extremely high risk of causing complete AV block during the procedure, which would necessitate the implantation of a permanent pacemaker. Pulses of low power RF current (5 W) were then delivered, with a progressive increase in 5 W increments up to 40 W, at sites where continuous activity (between A and V) of the accessory pathway was recorded with an absent or a barely visible H' wave. During RF energy delivery, achieving temperatures up to 55°C, only transient disappearance of the pre-excitation was seen. After multiple attempts with a maximum power of 40 W, the frequent appearance of a transient junctional rhythm led to the decision to terminate the procedure, since it was seen as a warning of complete AV block. A new study of the properties of the accessory pathway before completion of the procedure showed an increase in the antegrade refractory period to 320 ms.

During the next three days of hospitalisation, the patient's clinical condition deteriorated dramatically, since he developed incessant tachycardia (orthodromic AV re-entrant tachycardia alternating with

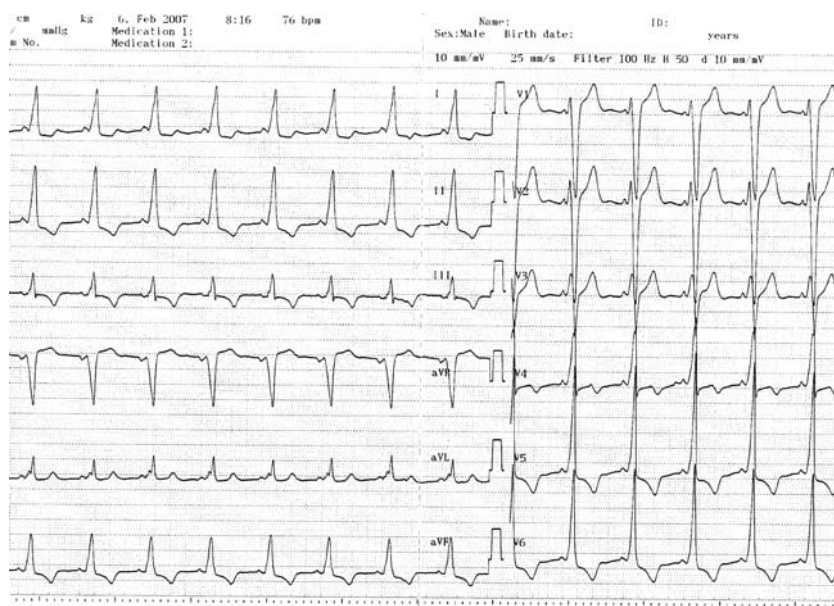


Figure 1. Twelve-lead ECG showing sinus rhythm with a pre-excitation pattern compatible with the existence of a right anteroseptal accessory pathway.

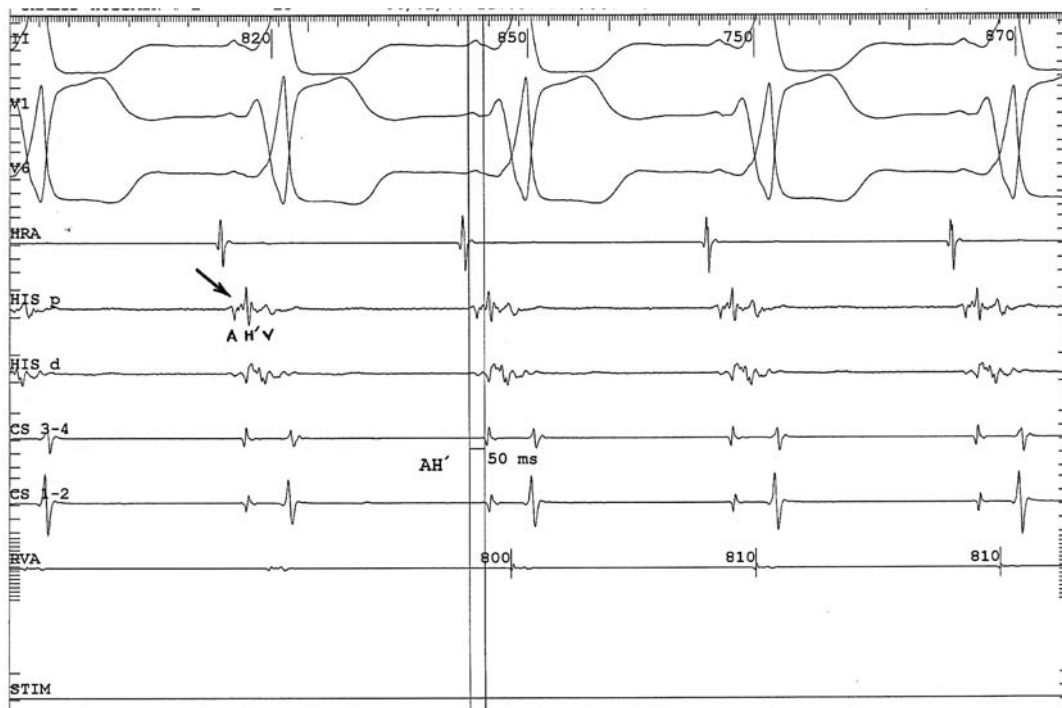


Figure 2. Basic electrophysiological recordings during sinus rhythm. The His electrode records continuous electrical activity from an accessory pathway between the atrial (A) and ventricular (V) electrograms (arrow), as well as a consistent spike of electrical activity in the form of a His-like (H') wave, the H' appearing almost simultaneously with the delta-wave on the surface ECG, and an AH' interval of 50 ms (H' appearing before the expected position of the His wave). The AH' duration remained stable throughout the study and was independent of the prematurity of the atrial stimulation. Moving the His electrode to all sites around the original one revealed no other wave with a His depolarisation morphology, while displacing it away from the original site gradually eliminated the potentials recorded between A and V.

accelerated junctional rhythm). The arrhythmia was refractory to adenosine and procainamide IV and had only a transient response to verapamil IV (Figure 5). This development was attributed to the ablation attempt, which had caused a widening of the induction zone of the orthodromic AV re-entrant tachycardia via the increase in the pathway's antegrade refractory period, as well as the appearance of the accelerated junctional rhythm, which acted as a trigger for the orthodromic AV re-entrant tachycardia. The patient experienced orthopnoea necessitating the administration of intravenous diuretics, while a new echocardiographic examination during tachycardia showed a global reduction in left ventricular systolic function (ejection fraction 35%).

Given the above adverse consequences, ablation of the pathway became mandatory and the patient underwent a second EPS followed by an ablation attempt, initially using the same RF energy application strategy as before, again without a therapeutic result.

Ablation of the pathway was finally accomplished with delivery of RF current at a level of 60 W, achieving a temperature rise to 65°C, at a fluoroscopic site almost tangential to that of the His catheter (Figure 6) and with clear recording of the H' wave by the ablation catheter. Therefore, the origin of the H' wave was definitively attributed to the electrical activity of the accessory pathway, while the recording of a low-amplitude true His potential (H) by the His electrode was only possible after successful ablation and elimination of the pre-excitation (Figure 7).

The patient was discharged from hospital two days post ablation in good general condition, without recurrence of the pre-excitation on his ECG (Figure 8). On his first follow up visit a month later the patient remained free of symptoms, in sinus rhythm, and without episodes of tachycardia on 24-hour Holter monitoring. Echocardiographic examination showed satisfactory left ventricular systolic function (ejection fraction 55%).

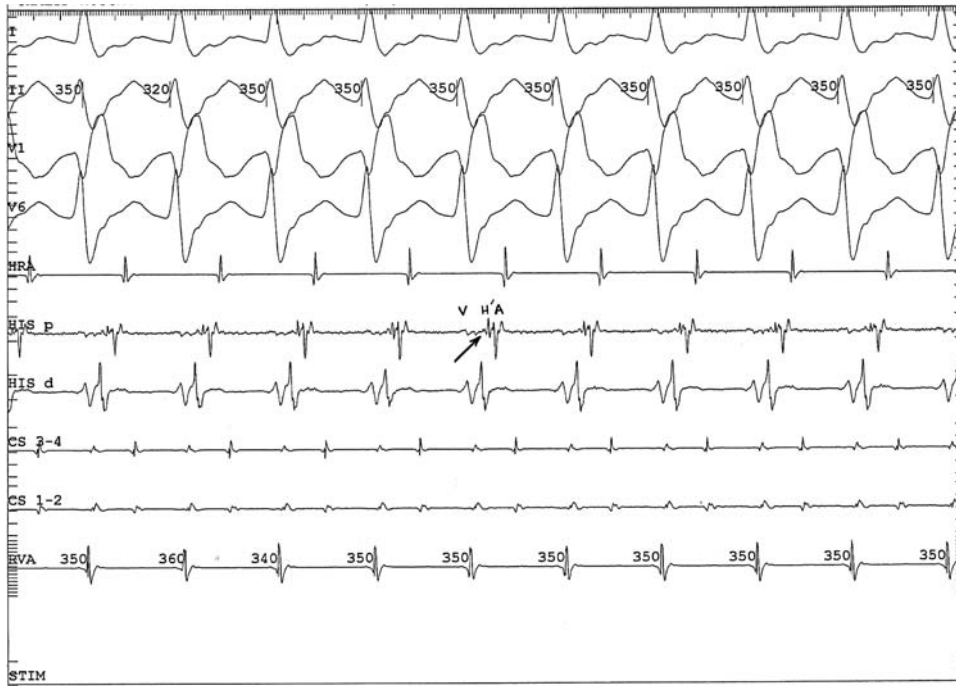
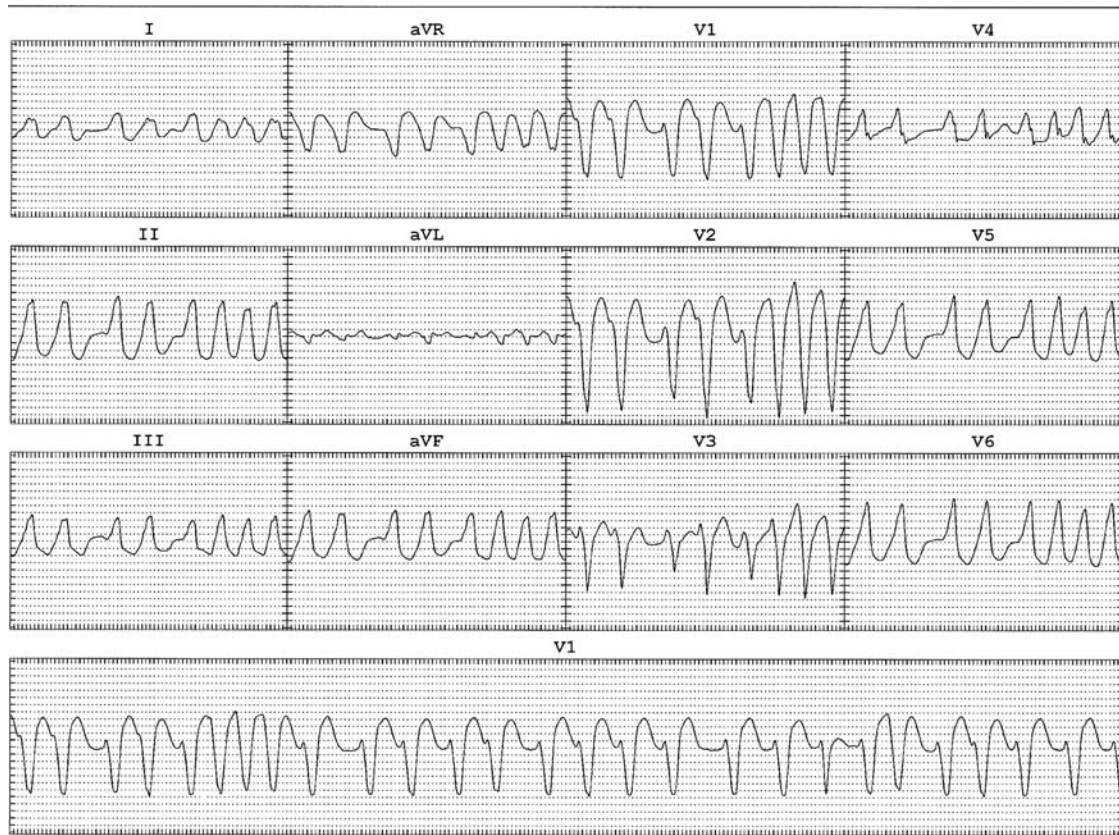

Figure 3. Electrophysiological recordings during orthodromic AV re-entrant tachycardia with a right bundle branch block configuration. The timing of the appearance of the H' wave after the V and slightly before the A wave (arrow) is compatible with it originating from the accessory pathway. Painstaking attempts to record a true His potential at the expected site during the tachycardia (before the QRS) met with no success. Retrograde ventriculoatrial conduction during the orthodromic AV re-entrant tachycardia shows early atrial depolarisation at the His catheter, a picture compatible with a location of the accessory pathway close to the His bundle.



eral Hospital of Nikea

Figure 4. Twelve-lead ECG during an episode of atrial fibrillation induced in the laboratory, showing the presence of pre-excitation in all the QRS complexes.

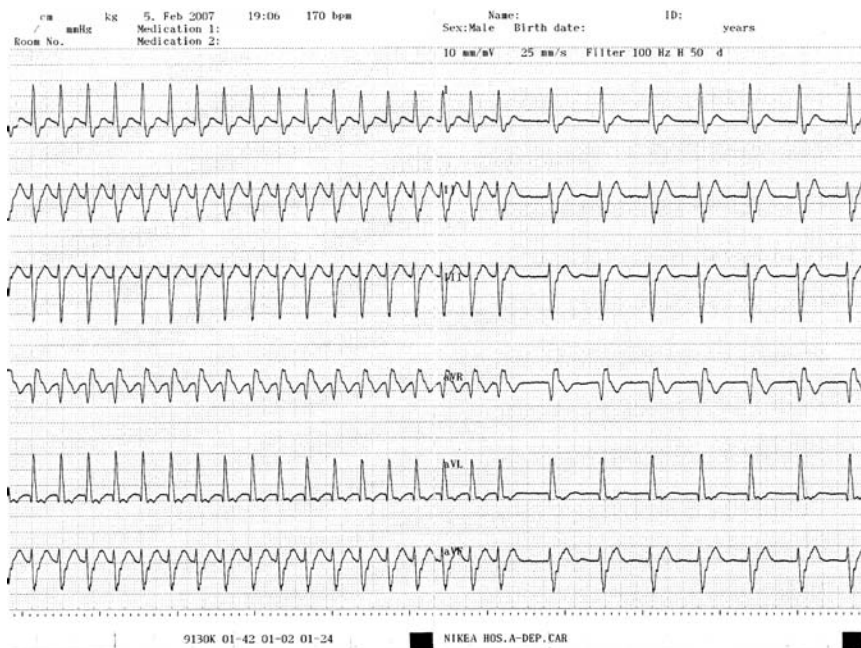

Figure 5. Incessant tachycardia (orthodromic atrioventricular re-entrant tachycardia occasionally alternating with accelerated junctional rhythm immediately after intravenous verapamil administration) between the two ablation procedures. Both rhythms show right bundle branch block.

Discussion

Ablation of accessory pathways is the treatment of choice in patients who exhibit episodes of supraventricular tachycardias, while it is also indicated in the case of asymptomatic patients with an ECG pattern of Wolff-Parkinson-White syndrome when an EPS shows the pathway to have a relatively short ante-

grade refractory period.⁵ Success rates of 95-99% have been reported for pathway ablation, with a relapse rate of 5-10%.^{3,4,10-12} The procedure is quite safe, with a low incidence of complications. One noteworthy complication, however, is the risk of causing complete AV block leading to the need for permanent pacemaker implantation.

Based on previous reports, the risk of causing complete AV block during an ablation procedure is rather high, reaching 36% in the case of pathways that are located close to the AV node and the His bundle.^{6,7,9,12-15} These are the anteroseptal and mid-septal right accessory pathways, according to the standard classification, while a specific subgroup includes the so-called para-Hisian pathways, which are in close proximity to the AV conduction system.⁶⁻⁹ Para-Hisian pathways make up 1.4% of the total accessory pathways reported and may be identified by the simultaneous recording of potentials from the accessory pathway and from the His bundle by the same electrode.⁶

The precise classification of pathways in the above locations using only the surface ECG is not possible, despite the existence of dedicated algorithms, since the proposed criteria are not absolutely specific for the sites to which they refer.^{6,16-18} Pinpointing the site of an accessory pathway, and hence its successful ablation, can be achieved only during an EPS using specific criteria related to the intracavity recordings from the mapping-ablation catheter. The

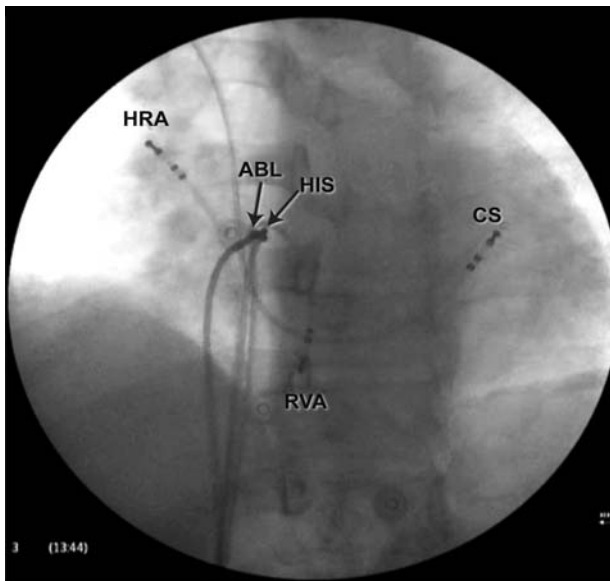


Figure 6. Fluoroscopic image during the successful delivery of RF current (left anterior oblique projection). Note the almost tangential position of the ablation catheter (ABL) in relation to the His bundle electrode (HIS). CS – coronary sinus; HRA – high right atrium; RVA – right ventricular apex.

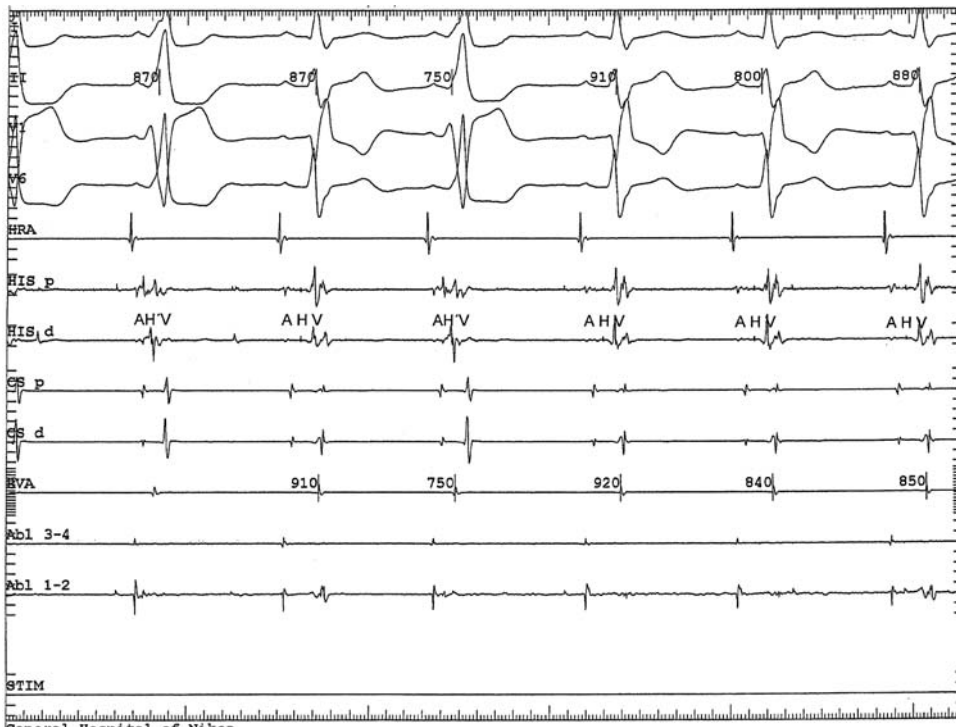


Figure 7. Electrophysiological recordings during the successful delivery of RF current. The H' wave is recorded only in the beats that have pre-excitation, whereas the H wave appears on recordings from the His electrode in beats without pre-excitation, thus demonstrating that the H' wave represents electrical activity in the accessory pathway and not in the His bundle. After successful ablation an H wave of greater amplitude could not be recorded.

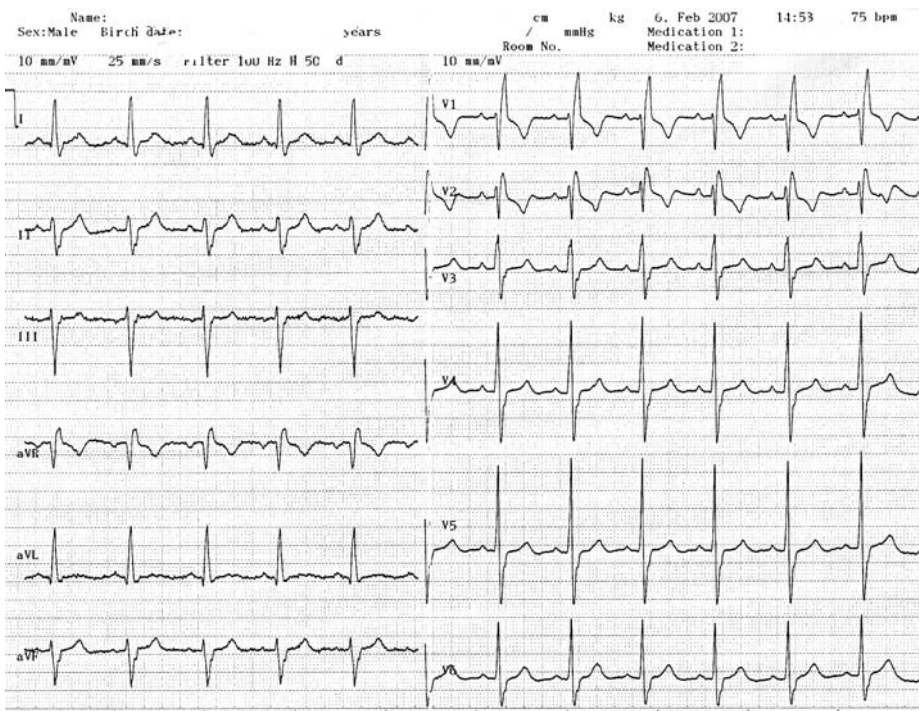


Figure 8. Twelve-lead ECG after the successful ablation, showing sinus rhythm, right bundle branch block, and no pre-excitation.

methodology used for the ablation of such pathways must include special precautions: a) the initial delivery of low power RF current (minimum 5 W, then if unsuccessful, increments of 5 W up to 20, 30, or even 40W) at sites where a characteristic intracavity electrogram is recorded for the accessory pathway with an

absent or minimal His electrogram; b) prompt interruption of the current delivery (within the first 10 s) if it has no effect; and c) immediate interruption of current delivery upon the appearance of junctional beats, which warn of the risk of complete AV block. A less commonly used technique, which appears to be effec-

tive and particularly safe, is that of cryoablation, which allows a preview of the final result through the creation of reversible lesions (ice mapping), thus avoiding the risk of permanent complete AV block.¹⁹⁻²¹

Some published reports have given rather low success rates for ablation of pathways located in close proximity to the conduction system (71-92%), despite the delivery of RF current to sites where accessory pathway potentials are recorded.^{13,22} The high failure rates compared with those for all accessory pathways can be attributed to both the delivery of low power RF current and the anatomical and electrophysiological peculiarities of the pathways in question.^{7,13} In the case reported here, the temperature of 55°C achieved during the first procedure probably contributed to its failure, since a higher mean temperature has been reported during successful ablation of accessory pathways.²³

The development of incessant tachycardia and the concomitant haemodynamic deterioration of the patient after the first, unsuccessful attempt at ablation was clearly a consequence of injury to the AV perinodal tissue, leading to an accelerated junctional rhythm as well as to frequent atrial and junctional extrasystoles which triggered the onset of orthodromic AV re-entrant tachycardia. The modification of the pathway's conduction properties by the unsuccessful delivery of RF current would also have played a part. Thus, despite the fact that the increase in the pathway's antegrade refractory period from 220 to 320 ms provided the patient with relative safety in the case of paroxysmal atrial fibrillation, it also facilitated the induction of orthodromic AV re-entrant tachycardia. The patient's clinical deterioration created an urgent need for ablation of the pathway and led us to perform the second procedure, during which the delivery of unusually high power RF current (60 W, temperature 65°C) finally achieved the desired result.

The low amplitude of the His potential (H wave, which was shown to be tangential to the ablation site and was recorded only after the withdrawal of the continuous electrical activity of the pathway between A and V), as well as its commonly seen tendency to decrease during tachycardia, explains why it could not be identified prior to the successful ablation, especially during orthodromic AV re-entrant tachycardia (Figures 2, 3). These findings confirm the initial estimation of the close proximity of the accessory pathway to the normal AV conduction system and justify the classification of the pathway as para-Hisian.

In conclusion, ablation of the relatively rare ac-

cessory pathways that are located close to the normal AV conduction system requires great care, because of the high risk of causing complete AV block. The delivery of extremely high power RF current, when necessary in cases like the one reported here, can be both effective and safe, even when a prior meticulous effort to identify discrete recording sites between the accessory pathway and the normal AV conduction system has failed.

References

1. Zipes D, Jalife J: *Cardiac Electrophysiology: From Cell to Bedside*. Saunders, Philadelphia, 2004.
2. Wolff L, Parkinson J, White P, et al: Bundle branch block with short P-R interval in healthy young people prone to paroxysmal tachycardia. *Am Heart J* 1930; 5: 685.
3. Calkins H, Yong P, Miller JM, et al: Catheter ablation of accessory pathways, atrioventricular nodal reentrant tachycardia, and the atrioventricular junction: final results of a prospective, multicenter clinical trial. The Atakr Multicenter Investigators Group. *Circulation* 1999; 99: 262-270.
4. Dagues N, Clague JR, Kottcamp H, et al: Radiofrequency catheter ablation of accessory pathways. Outcome and use of antiarrhythmic drugs during follow-up. *Eur Heart J* 1999; 20: 1826-1832.
5. Pappone C, Santinelli V, Rosanio S, et al: Usefulness of invasive electrophysiologic testing to stratify the risk of arrhythmic events in asymptomatic patients with Wolff-Parkinson-White pattern: results from a large prospective long-term follow-up study. *J Am Coll Cardiol* 2003; 41: 239-244.
6. Haissaguerre M, Marcus F, Poquet F, et al: Electrocardiographic characteristics and catheter ablation of parahisian accessory pathways. *Circulation* 1994; 90:1124-1128.
7. Lin JL, Huang SK, Lai LP, et al: Radiofrequency catheter ablation of septal accessory pathways within the triangle of Koch: importance of energy titration testing other than the local electrogram characteristics for identifying the successful target site. *Pacing Clin Electrophysiol* 1998; 21:1909-1917.
8. Tai CT, Chen SA, Chiang CE, et al: Electrocardiographic and electrophysiologic characteristics of anteroseptal, mid-septal, and para-Hisian accessory pathways. Implication for radiofrequency catheter ablation. *Chest* 1996;109:730-740.
9. Gatzoulis K, Apostolopoulos T, Kosteas X, et al: Paraseptal accessory connections in the proximity of the atrioventricular node and the His bundle. Additional observations in relation to the ablation technique in a high risk area. *Europace* 2004; 6: 1-9.
10. Kay GN, Epstein AE, Dailey SM, et al: Role of radiofrequency ablation in the management of supraventricular arrhythmias: experience in 760 consecutive patients. *J Cardiovasc Electrophysiol* 1993; 4: 371-389.
11. Calkins H, Prystowsky E, Berger RD, et al: Recurrence of conduction following radiofrequency catheter ablation procedures: relationship to ablation target and electrode temperature. The Atakr Multicenter Investigators Group. *J Cardiovasc Electrophysiol* 1996; 7: 704-712.
12. Jackman WM, Xunzhang W, Friday K I, et al. Catheter ablation of accessory atrioventricular pathways (Wolff-Parkinson-White syndrome) by radiofrequency current. *N Engl J Med* 1991; 324: 1605-1611.

13. Yeh SJ, Wang CC, Wen MS, et al: Characteristics and radiofrequency ablation therapy of intermediate septal accessory pathway. *Am J Cardiol* 1994; 73: 50-56.
14. Calkins H, Sousa J, El-Atassi R, et al: Diagnosis and cure of the Wolff-Parkinson-White syndrome or paroxysmal supraventricular tachycardias during a single electrophysiologic test. *N Engl J Med* 1991; 324: 1612-1618.
15. Kuck KH, Schlüter M, Guroy S: Preservation of atrioventricular nodal conduction during radiofrequency current catheter ablation of midseptal accessory pathway. *Circulation* 1992; 86: 1743-1752.
16. Scheinman MM, Wang YS, VanHare GF, et al: Electrocardiographic and electrophysiologic characteristics of anterior, midseptal and right anterior free wall accessory pathways. *J Am Coll Cardiol* 1992; 20: 1220-1229.
17. Fitzpatrick AP, Gonzales RP, Lesh MD, et al: New algorithm for the localization of accessory atrioventricular connections using a baseline electrocardiogram. *J Am Coll Cardiol* 1994; 23: 107-116.
18. Iturralde P, Araya-Gomez V, Colin L, et al: A new ECG algorithm for the localization of accessory pathways using only the polarity of the QRS complex. *J Electrocardiol* 1996; 29:289-299.
19. Lee AW, Crawford FA Jr, Gillette PC, et al: Cryoablation of septal pathways in patients with supraventricular tachyarrhythmias. *Ann Thorac Surg* 1989; 47: 566-568.
20. Lowe MD, Meara M, Mason J, et al: Catheter cryoablation of supraventricular arrhythmias: a painless alternative to radiofrequency energy. *Pacing Clin Electrophysiol* 2003; 26: 500-503.
21. Lanzotti ME, De Ponti R, Tritto M, et al: Successful treatment of anteroseptal accessory pathways by transvenous cryomapping and cryoablation. *Ital Heart J* 2002; 3: 128-132.
22. Xie B, Heald SC, Bashir Y, et al: Radiofrequency catheter ablation of septal accessory atrioventricular pathways. *Br Heart J* 1994; 72: 281-284.
23. Choi YS, Nam GB, Kim HS, et al: Temperature-guided radiofrequency catheter ablation of accessory pathway. *Korean J Intern Med* 1997; 12: 216-224.