

## Case Report

## Unusual Initial Presentation of Primary Systemic (AL) Amyloidosis with Severe Cardiomyopathy and Fatal Outcome

ELENA VEZALI<sup>1</sup>, IOANNIS ELEFSINIOTIS<sup>1</sup>, COSTAS TSIOUFIS<sup>2</sup>, IOANNIS KALLIKAZAROS<sup>2</sup>

<sup>1</sup>Department of Internal Medicine, <sup>2</sup>Department of Cardiology, Hippokraton Hospital, Athens, Greece

Key words:  
AL amyloidosis,  
cardiac  
involvement,  
hyperlipidaemia.

Primary (AL) amyloidosis is the most common form of systemic amyloidosis seen in current clinical practice. The symptoms of the disease are usually vague, special features are seen in fewer than one fifth of patients, and the combination of organs and systems involved provides a clue for the diagnosis. We describe a patient in whom asymptomatic hepatomegaly, cardiomegaly, hyperlipidaemia and elevated serum alkaline phosphatase level were found during routine examination; the final diagnosis was primary systemic AL amyloidosis with severe cardiomyopathy, resulting in a fatal outcome within eight months from the diagnosis.

**A**myloidosis is a unique metabolic storage disease that results from the deposition of insoluble fibrillar proteins in a variety of tissues. The disease usually affects multiple organs and a high level of suspicion is needed for reaching the diagnosis. We present a case of AL amyloidosis, in which the diagnosis was suspected from a combination of clinical features, laboratory findings and the echocardiographic pattern, and was then confirmed by the detection of serum and urine monoclonal component, as well as immunohistochemical staining.

### Case presentation

A 68-year-old man, a retired farmer, was referred to our hospital due to hepatomegaly, discovered by his general practitioner. Dizziness and mild fatigue were the only symptoms the patient reported. He had a three-year history of hyperlipidaemia treated by fluvastatin and a fifteen-year history of psoriasis. He never smoked and drank 10 g of alcohol weekly.

Physical examination revealed orthostatic hypotension, lateral displacement of the cardiac apex beat and a 2/6 systolic murmur, heard best at the lower left sternal border. A firm liver edge was palpable 6 cm below the costovertebral margin, but there were no signs of chronic liver disease. Abnormal laboratory data are presented in table 1. The chest radiogram (Figure 1) showed cardiomegaly and the electrocardiogram had a low voltage pattern. Significant hepatomegaly with irregular density of the liver, but without discrete lesion, was demonstrated by computer tomography (Figure 2). The transthoracic echocardiogram (Figures 3, 4) revealed a symmetrical thickening of the left (diameter of septum wall 22.4 mm and posterior wall 20 mm) and right ventricular walls (free wall 9.7 mm), interatrial septal thickening (9.3 mm), normal left ventricular internal diameter, and ejection fraction around 68%. The left atrium was enlarged (diameter 50 mm), the aortic valve was thickened and restricted in opening, but there was no significant stenosis; a small

Manuscript received:  
July 27, 2006;  
Accepted:  
October 13, 2006.

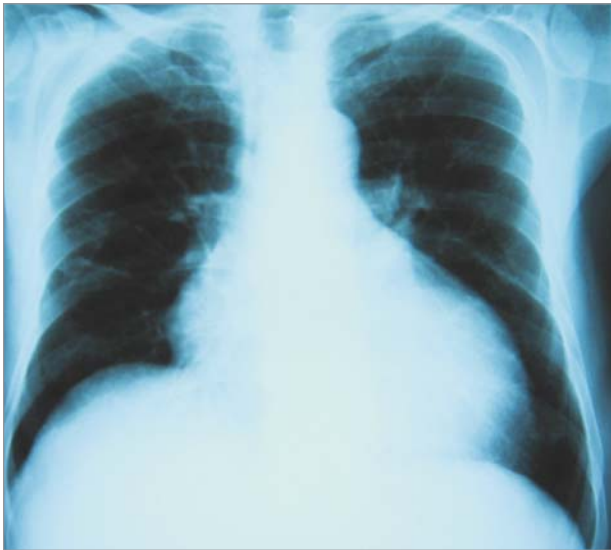Address:  
Elena V. Vezali

15 Agias Paraskevis St.  
141 23 Lykovrisi  
Athens, Greece  
e-mail:  
[avezalis@otenet.gr](mailto:avezalis@otenet.gr)

**Table 1.** Laboratory data.

Variable	Patient	Normal range (in this hospital)
Aspartate aminotransferase (IU/L)	70	10-40
Alanine aminotransferase (IU/L)	49	10-40
Gamma glutamyltransferase (IU/L)	287	10-75
Alkaline phosphatase (IU/L)	240	20-130
Total bilirubin (mg/dL)	1.6	0.1-1.0
Total cholesterol (mg/dL)	431	130-220
Triglycerides (mg/dL)	317	40-150
LDL cholesterol (mg/dL)	312	135-195
HDL cholesterol (mg/dL)	56	35-55
Serum B2-microglobulin (mg/L)	5.24	1.2-2.8
Serum protein immunoelectrophoresis	IgG kappa monoclonal protein 1560 mg/dL	Pattern without monoclonal protein
24-hour urine		
Protein (mg)	1230	30-300
Electrophoresis	Large amount of kappa Bence Jones protein	Absence of detectable monoclonal protein

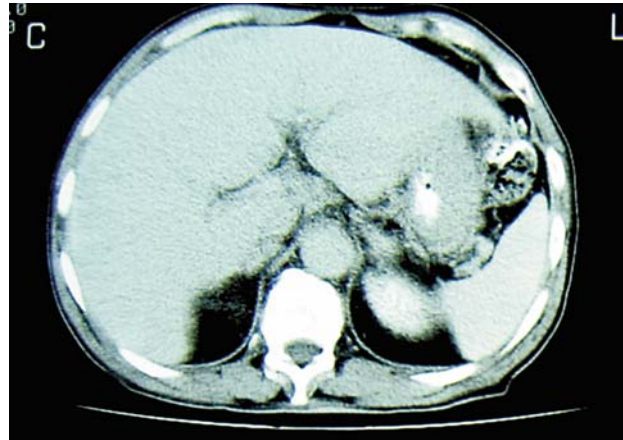HDL – high density lipoprotein; LDL – low density lipoprotein



**Figure 1.** Posterior-anterior chest radiograph revealing cardiomegaly.

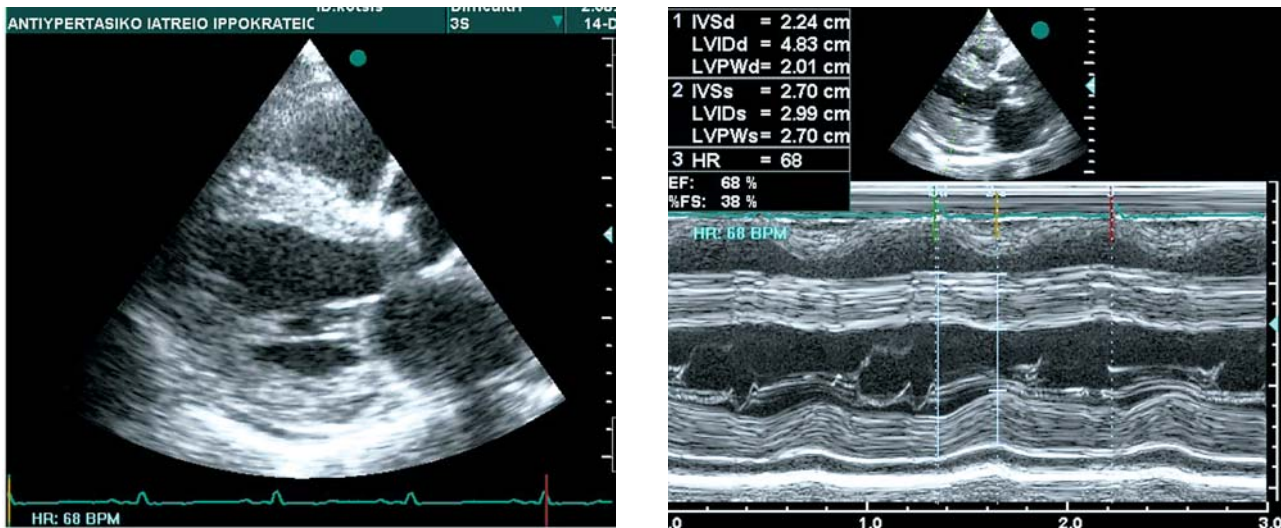
amount of pericardial effusion was present. The myocardium had a granular, sparkling appearance. Doppler evaluation of mitral flow detected a restrictive filling pattern with elevated left ventricular diastolic pressure.

Fine-needle aspiration biopsies of an abdominal

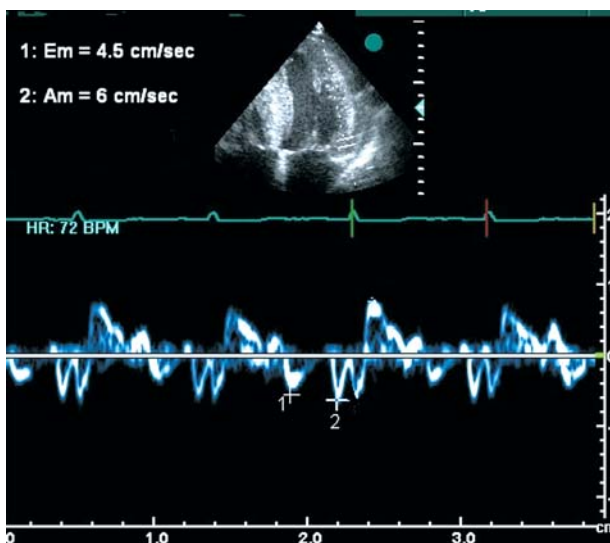


**Figure 2.** Abdominal contrast-enhanced computed tomographic scan, showing significant hepatomegaly, irregular density of the liver without focal lesion.

fat pad and the rectum, as well as a labial salivary gland biopsy, with Congo red staining for amyloid, were negative. Bone marrow aspiration showed a moderate increase of morphologically normal plasma cells (5-7%), deposits of amorphous extracellular material (positive reaction for amyloid P component), while the immunohistochemical staining for immunoglobulin light staining yielded a  $\kappa:\lambda$  ratio of 3:1 (Figure 5). Consequently, amyloid fibrils were tested for with the panel of antibodies against amyloid fibril protein, revealing a reaction against AL type  $\kappa$ .



**Figure 3.** Transthoracic echocardiogram (parasternal long-axis view) showing a granular sparkling appearance, symmetrical thickening of the left and posterior walls, thickening of the right ventricular wall and a small amount of pericardial effusion.



**Figure 4.** Tissue Doppler imaging at the lateral mitral annulus, depicting low diastolic annular velocities, consistent with impaired diastolic function.

Therapy with a four-day course of vincristine (0.4 mg/daily), adriamycin (15 mg/daily), and dexamethazone (40 mg/daily) was initiated, but was poorly tolerated by the patient and was switched to four-day courses of oral melfalan (12 mg/day) and prednisolone (60 mg/day), repeated every four weeks. Three months later the patient was hospitalised elsewhere with shortness of breath and right-sided pleural effusion (transudative fluid). Therapy with furosemid was started

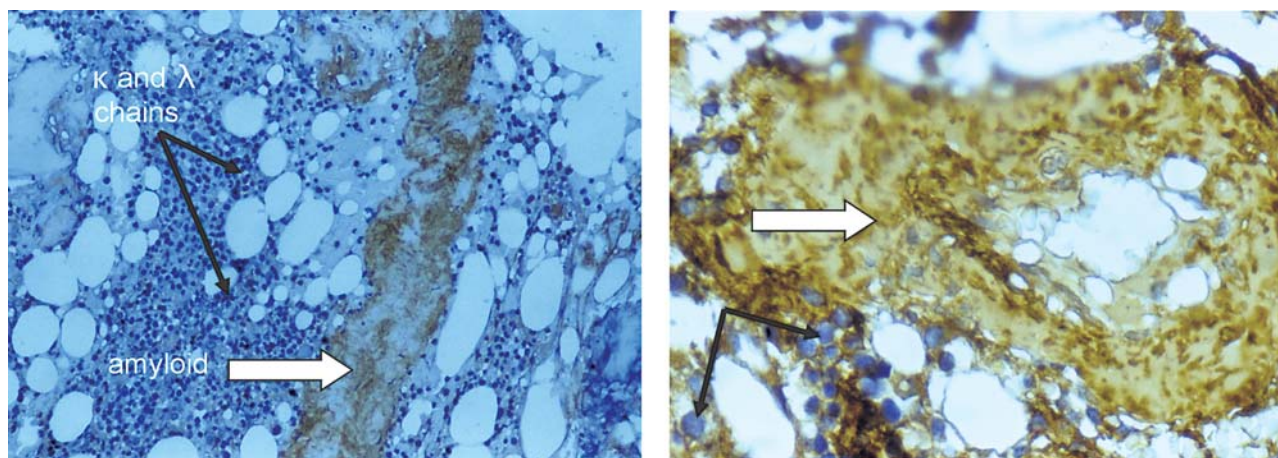
but substantially worsened the orthostatic hypotension. Six months after the diagnosis the patient suffered syncope caused by a third-degree atrioventricular block and underwent pacemaker implantation. Unfortunately, his clinical response to treatment was poor: serum and urine monoclonal component gradually elevated in parallel with the cholestatic syndrome, although the biosynthetic liver ability remained unaffected. Eight months after the initial diagnosis the patient died from refractory heart failure.

## Discussion

Amyloidosis is a group of diseases that have in common the extracellular deposition of insoluble fibrillar proteins with a characteristic  $\beta$ -pleated sheet configuration.<sup>1,2</sup> Classification of the amyloidosis is based on the type of the precursor protein involved.<sup>3</sup> In the case of AL amyloidosis it is an immunoglobulin light chain or its fragment, produced by a clone of plasma cells.

The clinical features are varied, with fatigue and weight loss being the most common, although non-specific. Cardiac involvement is the most serious complication of AL amyloidosis.<sup>4</sup> Our case demonstrates its typical features, such as hypotension, low voltage on the electrocardiogram, conduction block and congestive heart failure, reflecting the infiltrative process. Although it was not present in our patient, QS (pseudoinfarct) pattern can also be seen in amyloidosis. Patients are usually in sinus rhythm, somewhat surpris-





**Figure 5.** Bone marrow aspiration showing light deposits of amorphous extracellular material - positive reaction for amyloid P component (open arrow), and positive immunohistochemical staining for immunoglobulin light chains  $\kappa$  and  $\lambda$  (black arrows).

ingly given the extent of atrium dilatation frequently present. Echocardiographic findings of marked symmetrical thickening of the ventricular wall and ventricular septum in the absence of history of hypertension, normal ventricular cavity size, normal ejection fraction and impaired diastolic function, suggest a restrictive cardiomyopathy. A characteristic feature is the myocardial granular sparkling.<sup>5</sup> Postural hypotension in our patient was probably caused by autonomic neuropathy, but cardiac dysfunction may also have contributed.

Management of heart failure in these patients is problematic. As described in the literature, diuretics and angiotensin converting enzyme inhibitors can cause orthostatic hypotension, calcium channel blockers often worsen congestive heart failure, and  $\beta$ -blockers are best avoided due to their negative inotropism. Digoxin is contraindicated as it avidly binds to amyloid fibrils, causing toxicity.<sup>6</sup> Pacemaker implantation, as in our case, is often indicated for conduction abnormalities and symptomatic bradycardia.

The liver is commonly affected in systemic AL amyloidosis. Our patient presented with hepatomegaly, cholestasis, only mild elevation of the aminotransferases and unaffected biosynthetic liver function. These clinical features are usual,<sup>7</sup> because amyloid causes sinusoid infiltration, rather than direct hepatocyte injury.<sup>8</sup> So, in spite of the frequency of histological involvement, clinical manifestations often do not correspond with hepatic dysfunction. Severe cholestasis with jaundice has also been described,<sup>9,10</sup> but is less common.

Cases of AL amyloidosis with hyperlipidaemia

and hepatomegaly as the initial manifestation have been described in the literature. Levy et al<sup>11</sup> and Couture et al<sup>12</sup> reported two patients with hypercholesterolaemia preceding other clinical manifestations of amyloidosis, as in our case. The possible mechanism is the impairment of lipoprotein metabolism by the formation of immune complexes and liver dysfunction in the catabolism of low and very low density lipoproteins. In addition, lipid disturbances can be related to nephrotic syndrome.

Diagnosis of AL amyloidosis is based on clinical suspicion and established by tissue biopsy, usually of the organ involved. In the case of our patient the detailed evaluation, revealing the combination of organs involved (monoclonal protein in serum and urine, proteinuria with normal serum creatinine and blood urea nitrogen, restrictive cardiomyopathy, hepatomegaly with cholestasis and unimpaired liver synthetic function) provided the clue for the diagnosis. Do the negative results of the Congo red staining for amyloid in the subcutaneous abdominal fat, rectum and labial salivary gland biopsy rule out the diagnosis of systemic amyloidosis? It is reported that the tissue biopsies are positive in 50-90% of cases,<sup>13</sup> thus, the negative result on staining of tissues, as in our patient, does not necessarily eliminate amyloidosis from the diagnosis.

Despite treatment, the patient's symptoms and clinical condition did not improve. According to the literature, the median duration of survival from diagnosis of AL amyloidosis is 10.8 (0.83-1.25) years, but in patients with congestive heart failure and cholestasis it is significantly shorter: 0.75 (0.59-1.00) years. Amyloid heart disease is the commonest cause of

death. Recently, serum levels of cardiac troponin and N-terminal pro-brain natriuretic peptide, not available in our patient, were reported to be predictive markers of survival of AL amyloidosis patients.<sup>14</sup>

This report describes an asymptomatic patient with cardiomegaly and hepatomegaly and a history of hyperlipidaemia, a typical patient in cardiology outpatient departments, who was diagnosed as having primary systemic AL amyloidosis and died eight months later due to severe cardiomyopathy, despite adequate treatment and support. It provides a teaching point for cardiologists and other medical specialists who should be aware of these patients.

## References

1. Merlini G, Bellotti V: Molecular mechanisms of amyloidosis. *N Engl J Med* 2003; 349: 583-596.
2. Falk RH, Comenzo RL, Skinner M: The systemic amyloidoses. *N Engl J Med* 1997; 337: 898-909.
3. Westermark P, Benson MD, Buxbaum JN, et al: Amyloid: toward terminology classification. Report from the Nomenclature Committee of the International Society of Amyloidosis. *Amyloid* 2005; 12: 1-4.
4. Dubrey SW, Cha K, Anderson J, et al: The clinical features of immunoglobulin light chain (AL) amyloidosis with heart involvement. *QJM* 1998; 91: 141-157.
5. Ikeda S: Cardiac amyloidosis: heterogeneous pathogenic backgrounds. *Intern Med* 2004; 43: 1107-1114.
6. Khan MF, Falk RH: Amyloidosis. *Postgrad Med J* 2001; 77: 686-693.
7. Brunt EM, Tiniakos DG: Metabolic liver diseases: amyloidosis. *Clin Liver Dis* 2004; 8: 915-930.
8. Park MA, Mueller PS, Kyle RA, et al: Primary (AL) hepatic amyloidosis: clinical features and natural history in 98 patients. *Medicine (Baltimore)* 2003; 82: 291-298.
9. Goenka MK, Bhasin DK, Vasisth RK, et al: Hepatic amyloidosis presenting with severe intrahepatic cholestasis. *J Clin Gastroenterol* 1996; 23: 134-136.
10. Iwai M, Ishii Y, Mori T, et al: Cholestatic jaundice in two patients with primary amyloidosis: ultrastructural findings of the liver. *J Clin Gastroenterol* 1999; 28: 162-166.
11. Levy Y, Magill PJ, Miller NE, et al: Primary systemic amyloidosis presenting as extreme hyperlipidaemia with tendon xanthomas. *Br Med J (Clin Res Ed)* 1981; 283: 699-700.
12. Couture P, LeBlanc F, Gagnon P, et al: Hyperlipidaemia as the first biochemical manifestation of primary hepatic amyloidosis. *Am J Gastroenterol* 1997; 92: 1046-1047.
13. Gertz MA, Li CY, Shirahama T, et al: Utility of subcutaneous fat aspiration for the diagnosis of systemic amyloidosis (immunoglobulin light chain). *Arch Intern Med* 1988; 148: 929-933.
14. Dispenzieri A, Gertz MA, Kyle RA, et al: Serum cardiac troponins and N-terminal pro-brain natriuretic peptide: a staging system for primary systemic amyloidosis. *J Clin Oncol* 2004; 22: 3751-3757.