

Expert Perspective

Two-Stent Techniques for the Treatment of Coronary Bifurcations with Drug-Eluting Stents

IOANNIS IAKOVOU, ANTONIO COLOMBO

Centro Cuore Columbus and San Raffaele Hospital, Milan, Italy

Key words:
Drug-eluting stents,
bifurcations,
techniques.

Manuscript received:
February 11, 2005;
Accepted:
April 19, 2005.

Address:
Ioannis Iakovou

*Egnatia 119,
546 35 Thessaloniki,
Greece
e-mail: iako@hol.gr*

The latest advances in percutaneous coronary interventions (PCI) and the recent introduction of drug-eluting stents (DES) have led to a dramatic increase in the number of patients treated percutaneously.¹⁻⁵ Bifurcation lesions are one of the complex lesion subsets that are now being confronted more frequently.

Repeated studies have shown that bifurcation interventions, when compared to non-bifurcation procedures, have a lower rate of procedural success and a higher rate of restenosis.⁶⁻⁸ Various techniques making use of one or two stents have been developed to optimise the treatment of this subset of lesions.⁶⁻¹⁵ Paradoxically, while stenting of individual lesions has been shown to be superior to balloon angioplasty, stenting of both branches seems to offer no advantage over stenting of the main branch (MB) alone.⁸ The recent introduction of DES has resulted in a lower event rate and a reduction of MB restenosis in comparison with historical controls.¹⁶ However, side branch (SB) ostial restenosis remains a problem.

DES and bifurcations

Drug-eluting stents revolutionised the percutaneous treatment of coronary artery disease and are changing the way we treat bifurcation lesions. To date, there are only two randomised studies and some observational reports that specifically address the

issue of bifurcation lesion treatment with DES.¹⁶⁻¹⁸ The recently published sirolimus-eluting stent bifurcation study has given us an important initial direction to help us structure our approach to the optimal treatment of bifurcation lesions.¹⁶ This study was a five-centre randomised trial that involved 85 patients (86 lesions) and was designed to assess the feasibility and safety of treatment of patients with sirolimus-eluting stents (Cypher™, Cordis/ Johnson & Johnson, Warren, NJ) at true bifurcation lesions (>50% stenosis in both main vessel and ostium of side branch). Two different strategies were used in two patient groups: Group A, the elective use of two Cypher stents, and Group B, the implantation of a single Cypher stent in the MB with balloon dilatation across the stent struts for the SB. The protocol allowed the investigators to switch to double stenting if flow impairment or residual ostial stenosis >50% developed in the side branch. Twenty-two out of 43 patients randomised to group B crossed over and had two stents implanted. The total restenosis rate at 6 months was 25.7%, and it was not significantly different between the double-stenting (28.0%) and the provisional SB-stenting (18.7%) groups. In the majority of cases the restenosis occurred at the ostium of the SB and was focal. In the second randomised study (single centre, n=91) Pan et al compared stenting the MB and balloon dilatation for the SB to stenting for both branches. Similarly to the previous study, there

were no statistically significant differences between the two strategies.¹⁸

Thrombotic issues after DES implantation in bifurcations

Pathological studies have suggested that arterial branch points are foci of low shear and low flow velocity and are sites predisposed to the development of atherosclerotic plaque, thrombus, and inflammation.¹⁹⁻²¹ The two or even three layers of struts (“crush” technique) of DES apposed to the vessel wall initially raised concerns about possible increased thrombogenicity. Furthermore, delayed endothelialisation associated with DES may extend the risk of thrombosis beyond 30 days.²² In the sirolimus-eluting stent bifurcation study the rate of stent thrombosis was 3.5%. Very recently, we reported a rate of 3.6% for cumulative stent thrombosis after DES implantation in bifurcations in a prospective observational cohort study which included 2229 patients treated with both sirolimus (n=1062 patients) and paclitaxel-eluting stents (n=1167 patients, Taxus™, Boston Scientific, Natick, MA).²³ In this study, bifurcation lesion treatment was identified as an independent predictor of subacute (post-procedure to 30 days), late (>30 days), and cumulative thrombosis. However, there were no significant differences regarding the incidence of thrombosis in bifurcations treated with one versus two stents.²³

Two-stent techniques

In general, we should try not to stent the SB but, if necessary, we should have an effective strategy to stent both branches. The decision to use one or two stents – or sometimes even three (in case of a trifurcation) – should be taken as early as possible. An appropriate and timely decision will affect the result, save time and cost, and lower the risk of complications. If we take the decision to use one stent (in the MB) there is almost always the possibility of placing a second stent in the SB in case the result is not optimal or adequate. This situation is defined as “provisional stenting.”

In order to decide whether to place one stent or two we have to consider, first, whether the SB is of adequate size and length, and has an anatomical distribution suitable to be treated with a stent, and second, if the SB has a stenosis at the ostium over 50%. If the answer to both questions is “no” we will use provisional stenting in the MB; if “yes” we will place a second stent in the SB.

A number of techniques are available, with various levels of complexity and indications: the “V”, the

“simultaneous kissing stents” (SKS), “crush” and its variations (“reverse” and “step”), “T” and its variation (“modified”), “culottes”, “Y” and “skirt”. The most commonly used techniques for double stent placement are the first three and all of them will be described in detail below.

Selection of guiding catheter

The selection of the size (6, 7, or 8 F) of the guiding catheter follows the decision whether to stent the SB or not. Treatment of bifurcations frequently requires the simultaneous insertion of two balloons or two stents; therefore, some specific considerations regarding the selection of an appropriate guiding catheter are important. With currently available low profile balloons (i.e. Maverick, Boston Scientific), it is possible to insert two balloons inside a large lumen 6 F guiding catheter. If two stents are needed some limitations need to be known. The two stents can only be inserted one after the other, i.e. not simultaneously, using a 6 F guiding catheter. The standard “crush” and the “V” or SKS technique cannot be performed without the use of a guiding catheter of at least 7 F, with an internal lumen diameter of 0.081 inches (2.06 mm), in the case of the Taxus stent, or 8 F, with an internal lumen diameter of 0.088 inches (2.2 mm), in the case of the Cypher stent. A 6 F guiding catheter can be utilised if the operator performs a “provisional stenting” technique with a second stent (for the SB), which is advanced after the first stent has been placed in the MB. Techniques such as the “T”, the “reverse crush” and the “step crush” (see below for a description of each technique) can all be used with a 6 F guiding catheter. The “modified T” requires at least 7 F, and the “culottes”, “Y”, and “skirt” require at least 8 F guiding catheters.

The “V” and the “simultaneous kissing stents” technique

Description

The “V” technique involves the delivery and implantation of 2 stents together. One stent is advanced in the SB, the other in the MB, and the 2 stents touch each other forming a proximal carina (Figure 1).^{24,25} When this carina extends to a considerable length (usually 5 mm or more) into the main vessel then this technique is denoted as SKS.²⁶ The type of lesions we consider most suitable for this technique are very proximal lesions, such as bifurcation lesions located at the left main stem with a left main artery which is

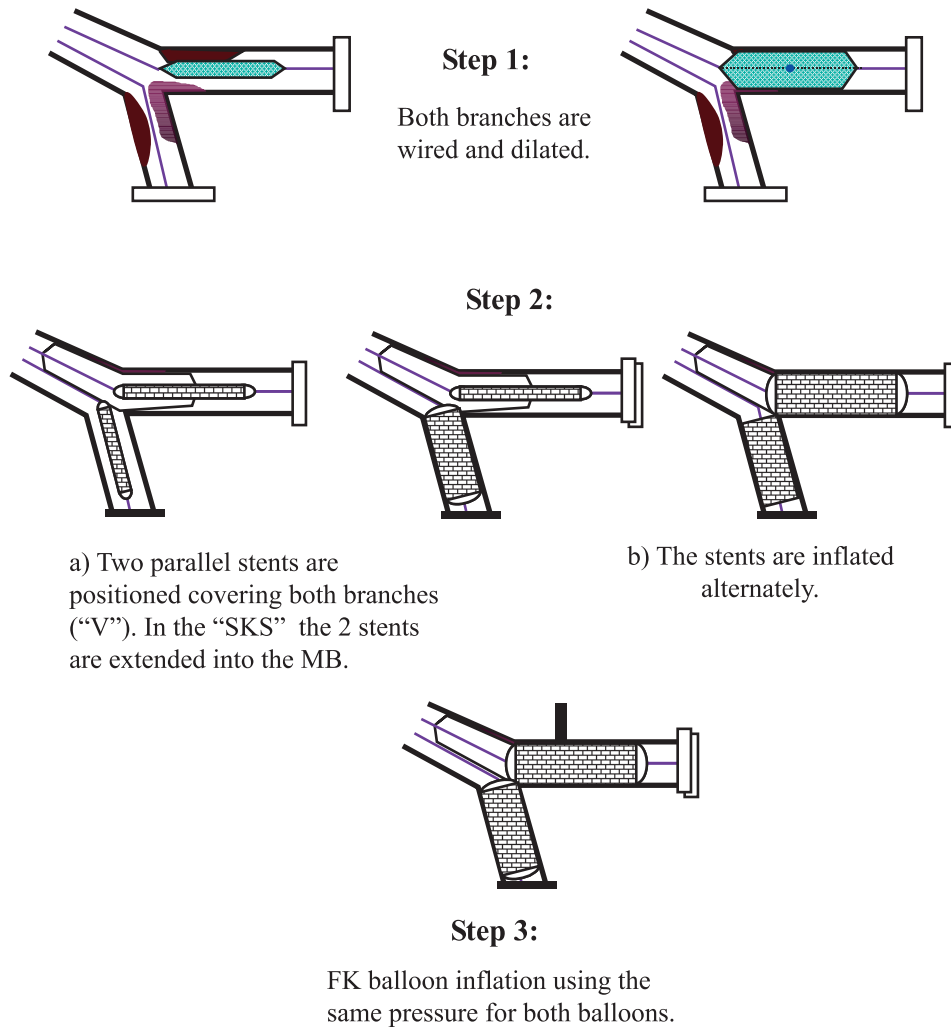


Figure 1. The “V” and “simultaneous kissing stents” (SKS) stenting technique. FK – final kissing, MB – main branch.

short or free of disease. Ideally the angle between the two branches should be less than 90°. The “V” technique is also suitable for other bifurcations provided the portion of the vessel proximal to the bifurcation is free of disease and there is no need to deploy a stent more proximally.

Advantages

The main advantage of these techniques is that the access to any of the 2 branches is never lost. In addition, when a final kissing inflation is performed there is no need to re-cross any stent.

Disadvantages

When using these techniques a metallic neocarina is created within the vessel proximal to the bifurcation. Theoretical concerns about the risk of thrombosis related to this new carina have not been confirmed in our and other operators’ experience.^{17,27} In addition, it is easy to see that the need to place a further stent proximally to the double implant can be quite problematic. There is an inevitable bias towards one of the two branches and a high likelihood of leaving a gap. If there is a need to place a stent in the proximal segment of a vessel treated with “V” stenting two options can be used: a) a stent is placed proximally leaving a small gap between the kiss-

ing stents and the proximal stent, and b) the kissing stent is converted into a “crush” with the stent in the MB overlapping the other stent (one arm of the V) in the SB. A wire then crosses the struts into the SB and a balloon is inflated toward the SB. Following wire removal from the SB, the proximal stent is then advanced towards the MB. In this case we are left with a short segment of the MB proximal to the bifurcation which has four layers of struts. Due to the complexity of this manoeuvre it is clear how important is to select lesions for the “V” technique in which there is a very low risk of performing proximal stenting.

The “crush” technique

Description

The “crush” technique¹³ was introduced at the time of DES introduction and is illustrated schematically in figure 2. Two stents are placed in the MB and the SB, the former more proximally than the latter. The stent of the SB is deployed and its balloon and wire removed. The stent subsequently deployed in the MB flattens the protruding cells of the SB stent, hence the term “crushing” or “crush”. Wire re-crossing and dilatation of the SB with a balloon of diameter at least equal to that of the

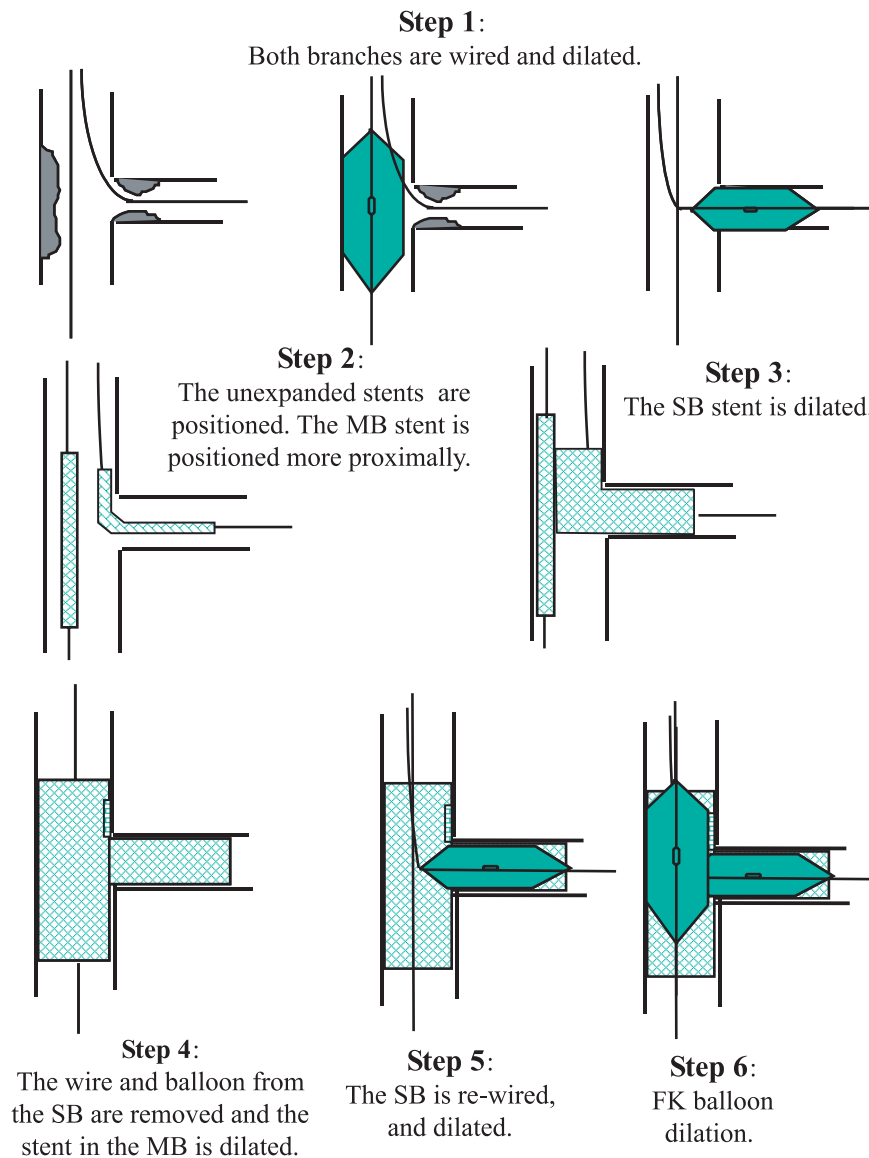


Figure 2. “Crush” technique. FK – final kissing, MB – main branch, SB – side branch.

stent,²⁸ followed by a final kissing balloon inflation, is recommended. The purpose of the final kissing balloon inflation is to allow better strut contact against the ostium of the SB and therefore better drug delivery.^{17,28} The “crush” technique can therefore be considered as a sort of simplified “culottes” technique. After the implementation of the final kissing inflation as part of the refinement of the technique, restenosis at the ostium of the SB seems to decrease. The positive aspect is that whenever restenosis occurs, this narrowing is very focal (less than 5 mm in length) and is mostly not associated with symptoms or ischaemia. An important element to keep in mind when planning to perform the “crush” technique is that the two available DES will reach different maximal openings of their cells.^{17,27} The maximal cell diameter will be 3.0 mm for the Cypher stent and 3.7 mm for the Taxus stent. These data should be kept in mind when the SB has a diameter over 3.0 mm.

Advantages

The main advantage of the “crush” technique is that the immediate patency of both branches is assured. This gain is important when the SB is functionally relevant or difficult to wire. In addition, it provides excellent coverage of the ostium of the SB, which is the main disadvantage of the simpler “T” technique (see below).

Disadvantages

The main disadvantage is that the performance of the final kissing balloon inflation makes the procedure more laborious, because of the need to re-cross multiple struts with a wire and a balloon.

The “reverse crush”

Description

The main reason for performing the “reverse crush” is to allow an opportunity for provisional SB stenting. A stent is deployed in the MB and balloon dilatation with final kissing inflation towards the SB is performed. Let us assume that the result at the ostium or at the proximal segment of the SB is suboptimal, so that the operator decides to deploy a stent at this site. A second stent is advanced into the SB and left in position without being deployed. Then, a balloon sized according to the diameter of the MB is advanced in the vessel and positioned at the level of the bifurcation with care, so that it remains inside the stent previously deployed in the MB. The stent in the SB is retracted about 2-3 mm into the

MB and deployed, the deploying balloon is removed and an angiogram is obtained to verify that a good result is present in the SB (no further distal stent in the SB is needed). If this is the case, the wire from the SB is removed and the balloon in the MB is inflated at high pressure (12 atm or more). The other steps are similar to the ones described for the “crush” technique and involve re-crossing into the SB, SB stent dilatation, and final kissing balloon inflation.

Advantages

The main advantage of the “reverse crush” technique is that the immediate patency of both branches is assured and that it can be performed using a 6 F guiding catheter.

Disadvantages

It shares the same disadvantages with the “standard crush” and is even more laborious.

The “step crush” technique

Description

The final result is basically similar to the one obtained with the “standard crush” technique, with the only difference being that each stent is advanced and deployed separately so that a 6 F guide may be used. First, a stent is advanced in the SB, protruding a few millimetres into the MB. A balloon is then advanced in the MB over the bifurcation. Then, the stent in the SB is deployed, the balloon removed, and an angiogram is performed: if the result is adequate the wire is also removed. The MB balloon is then inflated to crush the protruding SB stent and removed. Subsequently, a stent is advanced in the MB and deployed (usually at 12 atm or more). The subsequent steps are similar to the “crush” technique and involve re-crossing into the SB, performing SB stent dilatation and final kissing balloon dilatation.

Advantages

The main reason for using this technique is in order to perform the “crush” technique with a 6F guiding catheter. Operators who use the radial approach may be particularly interested in this technique.

Disadvantages

It shares the same disadvantages with the “standard crush”.

The “T” technique

Description

The classic “T” technique involves positioning a stent first at the ostium of the SB, being careful to avoid protrusion of the stent into the MB (Figure 3). Some operators leave a balloon in the MB to help to further locate the MB. Following deployment of the stent and removal of the balloon and the wire from the SB, a second stent is advanced in the MB. A wire is then re-advanced into the SB and final kissing balloon inflation is performed.

Advantages

It is less laborious than “crushing”. Unlike the “V” technique it can be used for the coverage of lesions proximal to a bifurcation.

Disadvantages

In almost all cases, this technique will lead to incomplete coverage of the ostium of the SB. At the present time in our practice the above technique has largely been abandoned, and there are now only two reasons for using it: 1) to place a stent at the ostium of an SB

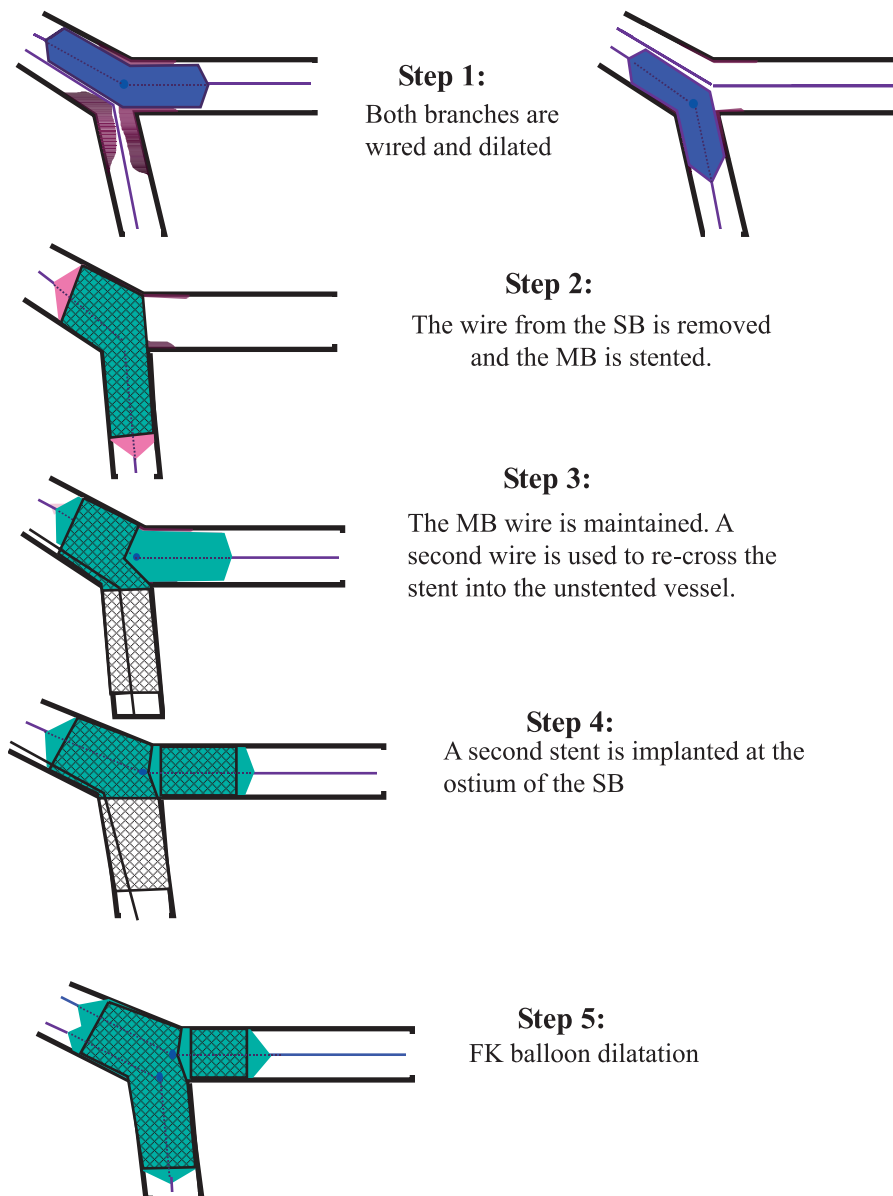


Figure 3. The “T” stenting technique (through the stent). FK – final kissing, MB – main branch, SB – side branch.

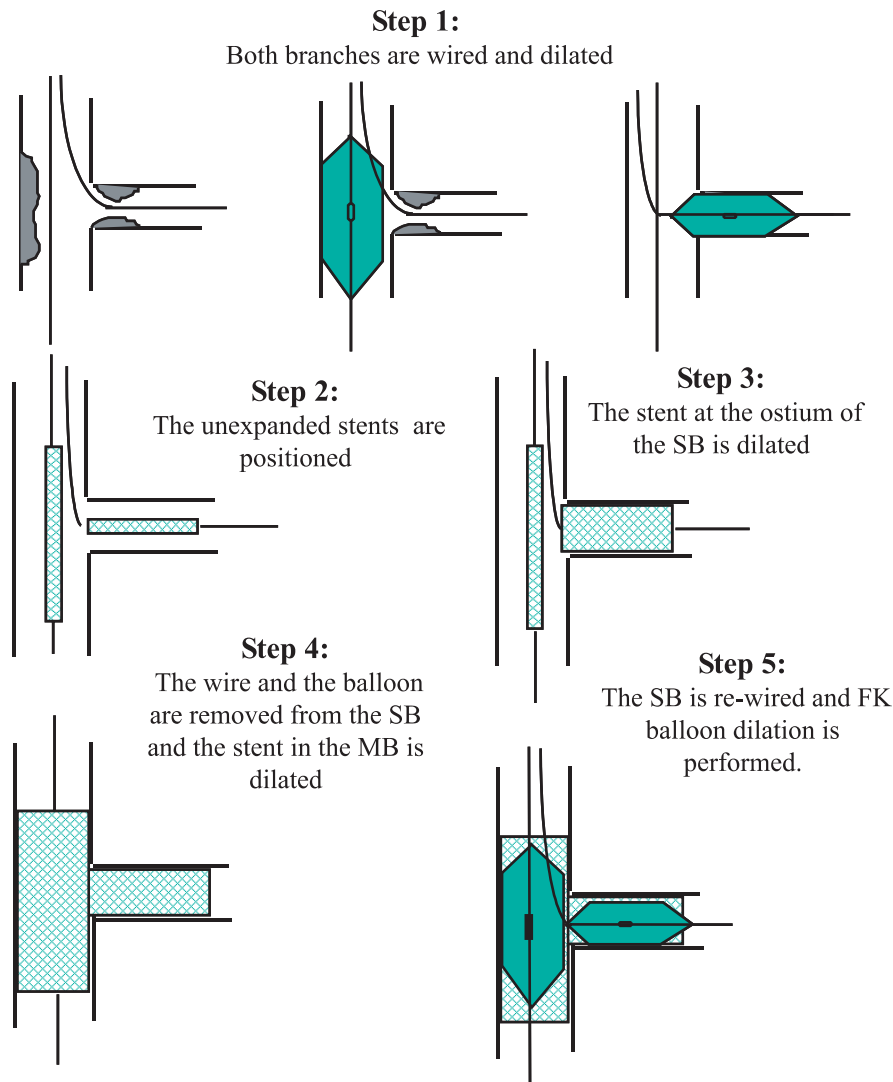


Figure 4. The modified “T” stenting technique. FK – final kissing, MB – main branch, SB – side branch.

following placement of a stent in the MB because the result at the SB ostium was evaluated as unsatisfactory (provisional SB stenting); 2) to perform stenting at the ostium of the SB when there is isolated SB ostial stenosis.

Modified “T” technique

Description

Following predilatation, the performance of this technique demands the advancing of a stent into the SB first (without deployment of the stent). Then a

second stent is advanced and positioned (without being deployed yet) across the bifurcation in the MB (Figure 4). The stent in the SB is deployed and, following verification of an adequate result, the balloon and the wire are removed from the SB. Then the stent in the MB is deployed, usually at 12 atm or more. A wire is then re-advanced into the SB and a final kissing balloon dilatation is performed (usually at 8 atm). The performance of the modified “T” technique commits always to stenting the MB and SB and almost always will leave a small gap between the 2 stents.¹²

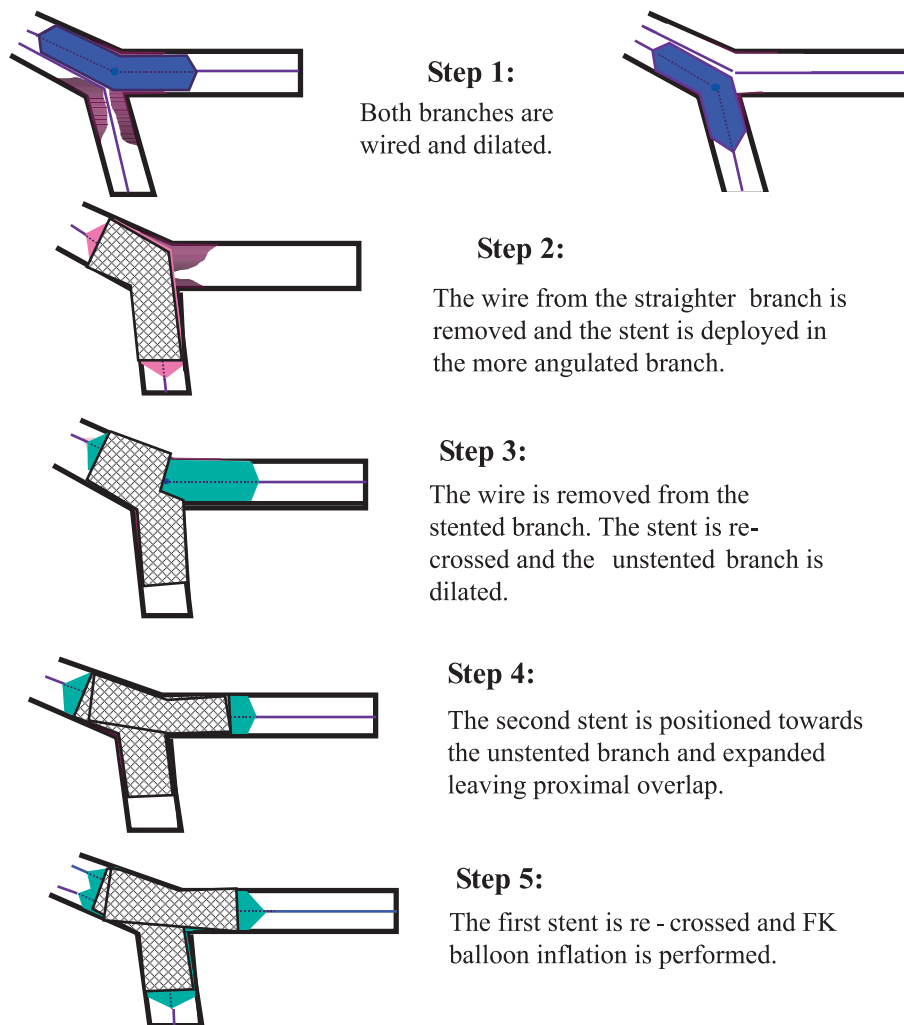


Figure 5. The “culottes” stenting technique. FK – final kissing.

Advantages

The same as the standard “T”.

Disadvantages

The same as the standard “T”, plus the need for a larger guiding catheter.

The “culottes” technique

Description

The “culottes” technique uses 2 stents and leads to full coverage of the bifurcation at the expense of an

excess of metal covering the proximal end (Figure 5).⁷ Both branches are predilated. First a stent is deployed across the most angulated branch, usually the SB. The non-stented branch is then rewired through the struts of the stent and dilated. A second stent is advanced and expanded into the non-stented branch, usually the MB. A final kissing balloon inflation is then performed.

Advantages

This technique is suitable for all angles of bifurcations and provides near perfect coverage of the SB ostium.

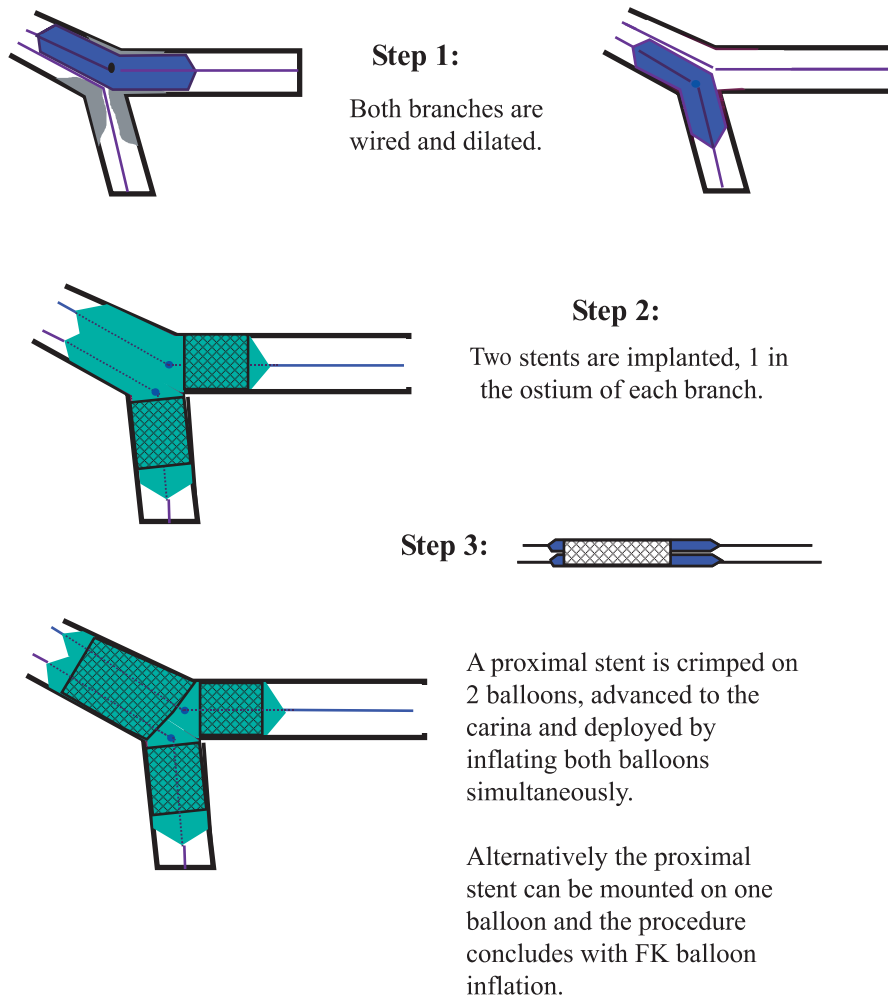


Figure 6. The “Y” stenting technique. FK – final kissing.

Disadvantages

Like “crushing”, it leads to a high concentration of metal with a double-stent layer at the carina and in the proximal part of the bifurcation. The main disadvantage of the technique is that rewiring both branches through the stent struts can be difficult and time consuming.

The “Y” and the “skirt” technique

Description

This technique has a particular historical value because it was one of the first bifurcation stenting techniques demonstrated in a live case course.²⁹ The “Y” stent te-

chnique involves an initial predilatation followed by stent deployment in each branch (Figure 6).¹¹ If the results are not adequate, a third stent may also be deployed in the MB. In order to try to bring the proximal stent effectively close to the stents already deployed it is necessary to modify the stent delivery device by placing one stent over two balloons (“skirt” technique). In that way, wire access to both branches is not lost.

Advantages

Can be used as a means of last resort for the treatment of very demanding bifurcations where there is a need to maintain wire access to both branches.

Disadvantages

The major limitation of this approach is the need to modify the delivery system of the proximal stent and to manually crimp the stent on two balloons. When using a DES, this approach may lead to alteration of the polymer. In addition to this issue, it is not always feasible to manoeuvre the proximal stent sufficiently close to the two more distal ones. For all these reasons, when there is a need to perform the “Y” technique, a more practical approach is to remove the wire from the SB and advance and deploy a proximal stent in the MB, trying to bring this stent as close as possible to the already deployed stents at the newly formed carina.

Conclusions

With the use of DES restenosis at the ostium of the SB is reduced to a single digit percentage and restenosis in the SB, when it occurs, is mostly focal. When the SB is not severely diseased, implantation of a stent in the MB and provisional stenting in the SB is the preferred strategy. Implantation of 2 stents as an initial approach is appropriate when both branches are significantly diseased (diameter stenosis >50%) and suitable for stenting. A number of techniques are available with various levels of complexity and indications: the “V”, “simultaneous kissing stents” (SKS), “crush”, “T”, “culottes”, “Y”, and “skirt”.

References

- Colombo A, Iakovou I: Ten years of advancements in interventional cardiology. *J Endovasc Ther* 2004; 11 Suppl 2: II10-II18.
- Colombo A, Iakovou I: Drug-eluting stents: the new gold standard for percutaneous coronary revascularisation. *Eur Heart J* 2004; 25: 895-897.
- Iakovou I, Ge L, Michev I, et al: Clinical and angiographic outcome after sirolimus-eluting stent implantation in aorto-ostial lesions. *J Am Coll Cardiol* 2004; 44: 967-971.
- Iakovou I, Sangiorgi GM, Stankovic G, et al: Effectiveness of sirolimus-eluting stent implantation for treatment of in-stent restenosis after brachytherapy failure. *Am J Cardiol* 2004; 94: 351-354.
- Cohen DJ, Bakhai A, Shi C, et al: Cost-effectiveness of sirolimus-eluting stents for treatment of complex coronary stenoses: results from the Sirolimus-Eluting Balloon Expandable Stent in the Treatment of Patients With De Novo Native Coronary Artery Lesions (SIRIUS) trial. *Circulation* 2004; 110: 508-514.
- Al Suwaidi J, Berger PB, Rihal CS, et al: Immediate and long-term outcome of intracoronary stent implantation for true bifurcation lesions. *J Am Coll Cardiol* 2000; 35: 929-936.
- Chevalier B, Glatt B, Royer T, Guyon P: Placement of coronary stents in bifurcation lesions by the “culotte” technique. *Am J Cardiol* 1998; 82: 943-949.
- Yamashita T, Nishida T, Adamian MG, et al: Bifurcation lesions: two stents versus one stent—immediate and follow-up results. *J Am Coll Cardiol* 2000; 35: 1145-1151.
- Pan M, Suarez de Lezo J, Medina A, et al: A stepwise strategy for the stent treatment of bifurcated coronary lesions. *Catheter Cardiovasc Interv* 2002; 55: 50-57.
- Ormiston JA, Webster MW, Ruygrok PN, Stewart JT, White HD, Scott DS: Stent deformation following simulated side-branch dilatation: a comparison of five stent designs. *Catheter Cardiovasc Interv* 1999; 47: 258-264.
- Fort S, Lazzam C, Schwartz L: Coronary ‘Y’ stenting: a technique for angioplasty of bifurcation stenoses. *Can J Cardiol* 1996; 12:678-682.
- Kobayashi Y, Colombo A, Akiyama T, Reimers B, Martini G, di Mario C: Modified “T” stenting: a technique for kissing stents in bifurcational coronary lesion. *Cathet Cardiovasc Diagn* 1998; 43: 323-326.
- Colombo A, Stankovic G, Orlic D, et al: Modified T-stenting technique with crushing for bifurcation lesions: immediate results and 30-day outcome. *Catheter Cardiovasc Interv* 2003; 60: 145-151.
- Colombo A: Bifurcational lesions and the “crush” technique: understanding why it works and why it doesn’t—a kiss is not just a kiss. *Catheter Cardiovasc Interv* 2004; 63: 337-338.
- Carrie D, Karouny E, Chouairi S, Puel J: “T”-shaped stent placement: a technique for the treatment of dissected bifurcation lesions. *Cathet Cardiovasc Diagn* 1996; 37: 311-313.
- Colombo A, Moses JW, Morice MC, et al: Randomized study to evaluate sirolimus-eluting stents implanted at coronary bifurcation lesions. *Circulation* 2004; 109: 1244-1249.
- Ge L, Airoidi F, Iakovou I, et al: Clinical and angiographic outcome following implantation of drug-eluting stents in bifurcation lesions with the crush stent technique: Importance of final kissing balloon post-dilatation. *J Am Coll Cardiol*: In press.
- Pan M, de Lezo JS, Medina A, et al: Rapamycin-eluting stents for the treatment of bifurcated coronary lesions: a randomized comparison of a simple versus complex strategy. *Am Heart J* 2004; 148: 857-864.
- Glagov S, Zarins C, Giddens DP, Ku DN: Hemodynamics and atherosclerosis. Insights and perspectives gained from studies of human arteries. *Arch Pathol Lab Med* 1988; 112: 1018-1031.
- Honda Y, Fitzgerald PJ: Stent thrombosis: an issue revisited in a changing world. *Circulation* 2003; 108: 2-5.
- Farb A, Burke AP, Kolodgie FD, Virmani R: Pathological mechanisms of fatal late coronary stent thrombosis in humans. *Circulation* 2003; 108: 1701-1706.
- Virmani R, Guagliumi G, Farb A, et al: Localized hypersensitivity and late coronary thrombosis secondary to a sirolimus-eluting stent: should we be cautious? *Circulation* 2004; 109: 701-705.
- Iakovou I, Schmidt T, Bonizzoni E, et al: Incidence, predictors, and outcome of thrombosis after successful implantation of drug-eluting stents. *JAMA*: In press.

24. Schampaert E, Fort S, Adelman AG, Schwartz L: The V-stent: a novel technique for coronary bifurcation stenting. *Cathet Cardiovasc Diagn* 1996; 39: 320-326.
25. Colombo A, Gaglione A, Nakamura S, Finci L: "Kissing" stents for bifurcational coronary lesion. *Cathet Cardiovasc Diagn* 1993; 30: 327-330.
26. Sharma SK, Choudhury A, Lee J, et al: Simultaneous kissing stents (SKS) technique for treating bifurcation lesions in medium-to-large size coronary arteries. *Am J Cardiol* 2004; 94: 913-917.
27. Ge L, Tsagalou E, Iakovou I, et al: In-hospital and 9-month outcome of treatment of coronary bifurcational lesions with sirolimus-eluting stents. *Am J Cardiol* 2005; 95: 757-760.
28. Ormiston JA, Currie E, Webster MW, et al: Drug-eluting stents for coronary bifurcations: insights into the crush technique. *Catheter Cardiovasc Interv* 2004; 63: 332-336.
29. Baim DS: Is bifurcation stenting the answer? *Cathet Cardiovasc Diagn* 1996; 37: 314-316.