

Modified David I Procedure in Patients with Marfan Syndrome and Aortic Root Aneurysm

NIKOS E. MEZILIS, NIKOS E. NIKOLOUDAKIS, PETROS S. DARDAS, DIMITRIS D. TSIKADERIS, EVANGELOS A. REPPAS, ANTONIS A. PITSIS

Thessaloniki Heart Surgery Institute, "Agios Loukas" Clinic, Thessaloniki, Greece

Key words:

**Marfan syndrome,
aortic aneurysm,
David procedure.**

Annuloaortic ectasia is a common finding in patients with Marfan syndrome and, more generally, in diseases due to mutation of the fibrillin gene, known as fibrillinopathies. In cases where the aortic dimensions exceed the critical limits the usual therapy is replacement of the aortic valve and the ascending aorta. The disadvantages of this classical treatment are the chronic anticoagulant medication and the loss of the elastic properties and the compliance of both the annulus and the aorta, because of the placement of a metallic valve prosthesis. However, when the valve leaflets are physiological or marginally distended, the aortic valve may be preserved (David and Yacoub procedures). We present two cases of young patients with Marfan syndrome and ectasia of the aortic annulus and root, who were treated with a modified David procedure using a Valsalva graft, and we analyse the postoperative haemodynamic parameters of the valve and of the aorta. The advantage of the method is the preservation of the aortic valve as well as the elastic properties of the aortic root. Another important advantage is the avoidance of systematic, postoperative anticoagulant administration, especially in this category of patients who are at high risk for aortic dissection.

Manuscript received:
January 8, 2004;
Accepted:
June 2, 2004.

Address:
Nikos E. Mezilis

*1 Alex. Svolou St.,
546 22, Thessaloniki,
Greece
e-mail:
mezilis@otenet.gr*

Annuloaortic ectasia is a common finding in patients with Marfan syndrome and, more generally, in diseases due to mutation of the fibrillin gene, known as fibrillinopathies.¹⁻⁴ It is well known that in these patients the aorta is more vulnerable to dissection, even when its size is below the critical limit.^{5,6} The aortic valve leaflets are usually overstretched at the time the patient is taken for surgery and the usual therapy is therefore the replacement of the aortic valve and the ascending aorta (Bentall procedure).^{7,8} The disadvantages of this classical treatment are the chronic anticoagulant medication (increased risk of aortic dissection) and the loss of the elastic properties and the compliance of both the annulus and the aorta, because of the placement of a metallic valve prosthesis. However, when the valve leaflets are physiological or marginally distended, the aortic valve may be preserved. There are two main surgical techniques that have been described for the preserva-

tion of the aortic valve using a tubular graft and reimplantation of the coronary artery ostia: the David reimplantation procedure and the Yacoub remodelling procedure.^{9,10}

We present two cases of young patients with fibrillinopathies and ectasia of the aortic annulus and root, who were treated with a modified David procedure using a Valsalva graft, and we analyse the postoperative haemodynamic parameters of the valve and of the aorta.

Case 1

A man aged 32 years with known Marfan syndrome and aneurysmatic dilatation of the aortic root was admitted for surgical treatment of his condition. The patient was free of symptoms but recent magnetic resonance imaging of the aorta had shown aneurysmatic dilatation of the ascending aorta that also included the annulus of the valve. The size of the aneurysm was 60 x 55 mm (Figures 1, 2). The preoperative tran-

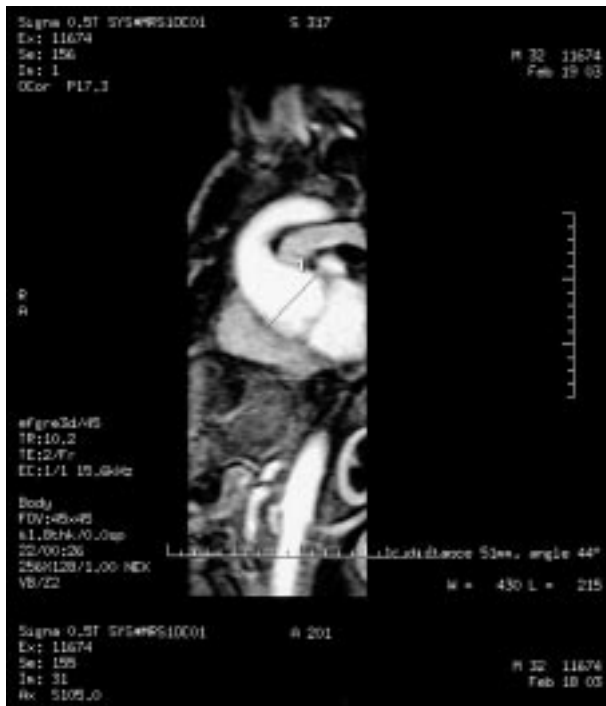

Figure 1. Magnetic resonance imaging of the ascending aorta, showing dilatation of the root and one section.

soesophageal echocardiogram confirmed the dilatation of the annulus and the overstretching of the aortic valve leaflets (Figure 3). The valvular function was slightly compromised with a small degree of regurgitation. The patient underwent a modified David procedure using a tubular Valsalva graft 30 mm in diameter. The postoperative transoesophageal echocardiogram showed a fully functioning valve. Figure 4 shows the immediately postoperative state of the valve, in which all three leaflets have good opening and no regurgitation. The size of the annulus was 36 mm and the distance of the leaflets from the aortic wall during mid-systole was 6.7 mm (Figure 5). The dimensions of the ascending aorta at the mean level of the Valsalva sinuses and at the sinotubular junction were 37.7 mm and 26.1 mm. Figure 6 shows the M-mode echocardiogram along the transverse axis at the level of the annulus. The dimensions of the annulus in mid-systole and diastole were 33.9 mm and 29.3 mm, respectively. The difference between the measurements corresponds to a 13.5% increase in size during systole.

The patient exhibited complete atrioventricular block on the 2nd postoperative day. This persisted until the 15th postoperative day and so a permanent dual-chamber pacemaker was implanted.

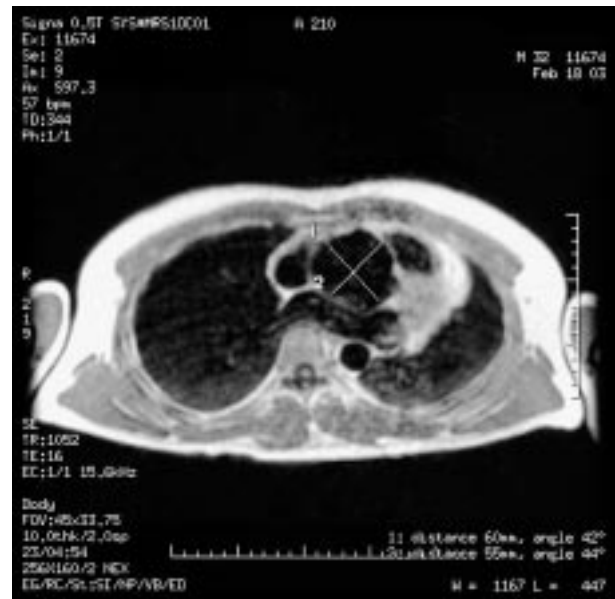

Figure 2. Magnetic resonance imaging of the aortic root on the transverse axis, showing the size of the aneurysm (60 x 55 mm).

Case 2

A man aged 35 years with severe aortic regurgitation due to an aortic root aneurysm 60 mm in diameter and a tricuspid aortic valve with physiological leaflets on preoperative transoesophageal echocardiogram was treated using a modified David procedure, using

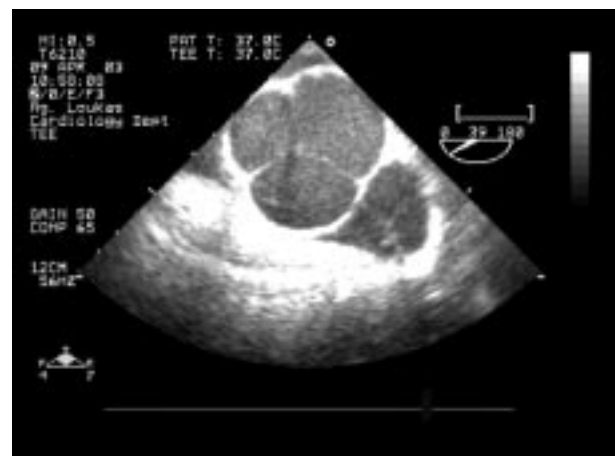

Figure 3. Transverse section of the aortic valve on the transoesophageal echocardiogram, showing the dilatation of the annulus with preserved structure of the valve leaflets (tricuspid valve).

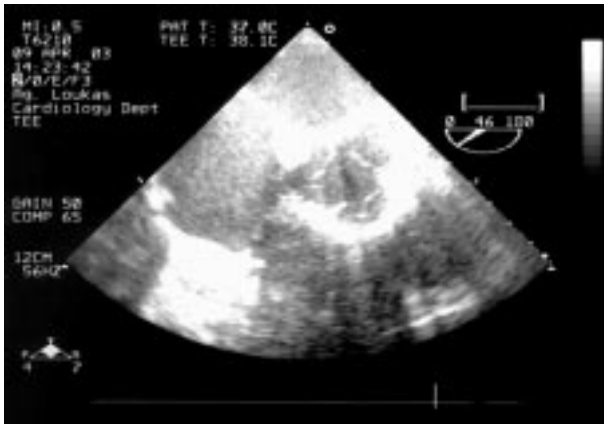

Figure 4. Postoperative transoesophageal echocardiographic image during mid-systole, showing the three leaflets of the aortic valve.

a tubular Valsalva graft 28 mm in diameter. The postoperative transoesophageal echocardiogram showed a fully functioning valve. The patient's postoperative course was smooth and he was discharged on the 7th postoperative day. He remains free of symptoms one year later. The transthoracic echocardiogram at one-year follow up showed no aortic regurgitation.

Description of surgical technique

The procedures were carried out under extracorporeal circulation and mild hypothermia (35°C). Antegrade warm blood cardioplegia rich in potassium and magnesium was used for the protection of the myocardium, according to Calafiore's protocol.¹¹ After

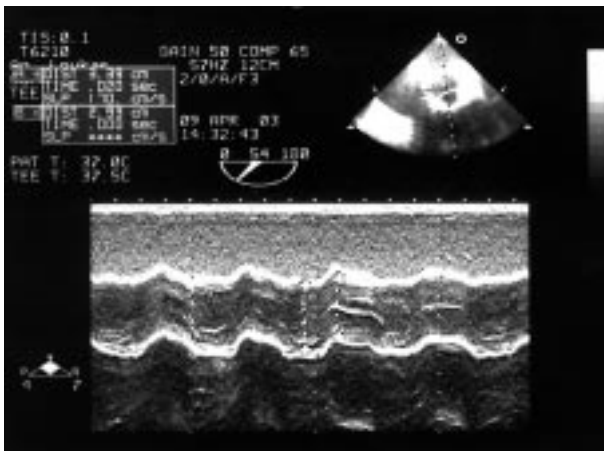


Figure 6. M-mode echocardiogram at the level of the aortic valve, showing the difference in the diameter of the annulus between diastole and systole (2.93 cm and 3.39 cm, respectively, difference 13.5%).

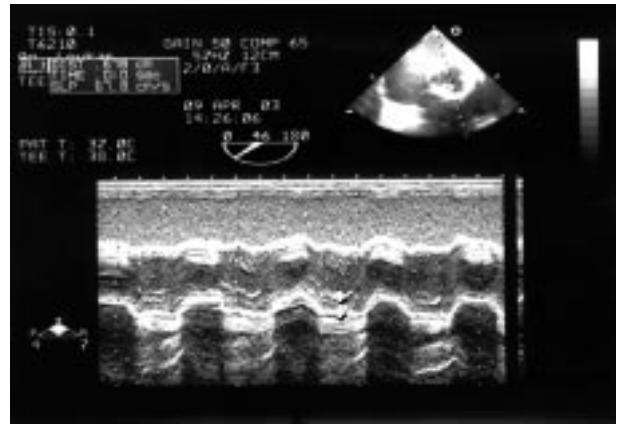


Figure 5. M-mode echocardiogram at the level of the aortic valve, showing the distance between the valve commissures and the wall of the graft during mid-systole (6.7 cm).

occlusion of the aorta, the aneurysm was opened and the aortic valve leaflets were checked and found to be physiological in both cases. The coronary artery ostia were prepared, leaving a small margin (2-3 mm) of aortic tissue around them for their later reimplantation. All the tissue of the aortic root was removed apart from 3 mm of tissue above the aortic annulus, which was used for its reimplantation. Twelve horizontal Ethibond 2/0 U stitches were placed below the aortic annulus in order to fix the graft in the inflow suture line. The choice of graft diameter was based on the diameter of the left ventricular outflow tract.

The Valsalva graft (Figure 7) differs from the classical tubular grafts in that it includes in its first portion a region that resembles the sinuses of Valsalva. The three commissures of the valve are fixed to

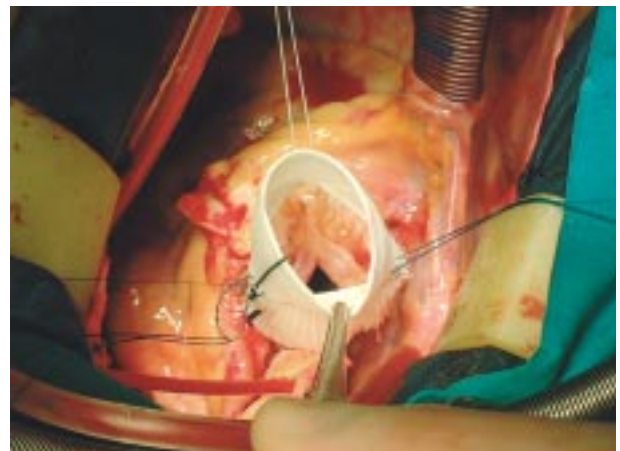


Figure 7. The Valsalva graft in which the annulus and the aortic valve leaflets can be seen.

the boundary where the graft changes from spherical to tubular in such a way as to trisect the graft. The annulus of the aortic valve is sutured to the graft using continuous polypropylene 4/0 sutures. The coronary arteries are then reimplanted using continuous polypropylene 5/0 sutures and the graft is anastomosed with the ascending aorta using continuous polypropylene 4/0 sutures.

Discussion

Marfan syndrome is a hereditary disease of the connective tissue which is due in the majority of cases to mutations in the fibrillin-1 gene and less commonly to mutations of the fibrillin-2 gene, which genes are based on chromosomes 15 and 5, respectively. So far, more than 85 mutations of the gene have been identified. It is well known that patients with Marfan syndrome, as well as those who have the traits of the syndrome but lack the genotype (Marfanoid), have a higher incidence of aortic root aneurysm compared with the general population.^{3,4} The aortic disease is usually limited to the media, while the annulus and the valve leaflets may remain physiological, at least in the initial stages. As the media degenerates, the aorta widens, leading to dilatation of the annulus that drags the valve leaflets apart, the final result being aortic regurgitation and an increased risk of aortic dissection. Because of these elevated risks it has been proposed that surgical treatment should be instigated when the aortic dimensions exceed 50 mm, as opposed to the 55 mm that is taken as the critical limit in the general population.⁵

The classical surgical treatment of the condition includes replacement of the aortic valve and ascending aorta. The disadvantages of this form of therapy are easy to understand.¹² In the majority of patients a metallic valve is implanted, leading to a need for chronic anticoagulant medication, which is undesirable in individuals at high risk for dissection. The procedure also has significant negative consequences for the physiological function of the aorta. It is well known that the elastic properties of the aorta and its annulus allow its diameter to increase and decrease during systole and diastole by as much as 10%. It should be noted that the elastic properties of the aorta in patients with Marfan syndrome are in any case pathological,³ regardless of the size of the aorta, because of the intrinsic disturbance of the wall. With the placement of a prosthetic valve, however, the elastic properties of the annulus disappear, further compromising the compliance of the organ.

Since the end of the 1980s, various techniques have been developed for preserving the valve by transplanting it to a graft that is sutured to the valve annulus (Yacoub and David procedures).^{9,10,13,14} The main surgical difference between the reimplantation of the aortic valve in the David procedure and Yacoub remodelling is that in the David procedure the prosthetic graft surrounds the aortic annulus using double lines of sutures. In the Yacoub procedure the graft is sutured on to the aortic annulus, which requires only a single line of sutures.¹⁵

The David procedure is a laborious and rather time-consuming operation. To compensate, however, it involves less haemorrhage during and after surgery, so that cardiac surgical teams prefer to use it in cases of dissection of the ascending aortic in patients with Marfan syndrome. Also, the reoperation rate as a consequence of aortic regurgitation is smaller than in Marfan patients who undergo the Yacoub procedure. Our team employs a modified David I procedure using a Valsalva graft that permits the most physiological replacement possible of the aortic root, which is characterised by the swirling currents of Leonardo da Vinci.¹⁶ These currents play an important role in the opening and closing of the aortic valve leaflets and in consequence their elimination could affect the life expectancy of the repair.

The great advantage of the method is the excellent immediate haemodynamic and echocardiographic parameters seen for both the valve and the aortic root. These include the absence of pressure gradient and the absence of regurgitation. From the M-mode echocardiogram it can be seen that the distance of the commissures from the aortic wall during mid-systole is 6.7 mm. Contact between the crescent-shaped commissures of the aortic valve and the wall of the graft is known to be responsible for thickening of the leaflets, which promotes their degeneration.¹⁷ From recent publications by David et al,⁹ it appears that the careful avoidance of contact between the commissures and the graft during systole reduces 5-year reoperation by 99% and 5-year aortic regurgitation by 90%. Also, the elastic properties of the aortic annulus were preserved in our patients, since we saw a difference in diameter between systole and diastole of 4.6 mm (13.5%).

To conclude, it must be stressed that there is no need for oral anticoagulants, which is extremely desirable in this category of patients, where the risk of aortic dissection is higher than in the general population.

References

1. Weaven WF, Edwards JE, Brandenburg RO: Idiopathic dilatation of the aorta with aortic valvular insufficiency: a possible forme fruste of Marfan's syndrome. *Mayo Clin Proc* 1959; 34: 518-522.
2. Davies MJ: Pathology of cardiac valves. Toronto: Butterworths, 1980, pp 37-61.
3. Edwards JE: Pathology of aortic incompetence. In Silver MD (ed): Cardiovascular pathology. Edinburgh: Churchill Livingstone, 1983, pp 619-631.
4. Olson LJ, Subramanian R, Edwards WD: Surgical pathology of pure aortic insufficiency: a study of 225 cases. *Mayo Clin Proc* 1984; 59: 835-841.
5. Eleftheriades JA: Thoracic aortic aneurysms: current approach to surgical timing. *ACC Current Journal Review* May/June 2002.
6. Coady MA, Rizzo JA, Hammond GL, et al: What is the appropriate size criterion for resection of thoracic aortic aneurysms? *J Thorac Cardiovasc Surg* 1997; 113: 476-491.
7. Bentall HH, DeBono A: A technique for complete replacement of ascending aorta. *Thorax* 1968; 23: 338-339.
8. Gott VL, Pyeritz RE, Magovern GL Jr, Cameron DE, McKusic VA: Surgical treatment of aneurysms of the ascending aorta in the Marfan syndrome: results of composite graft repair in 50 patients. *N Engl J Med* 1986; 314: 1070-1074.
9. David TE, Feindel CM: An aortic valve-sparing operation for patients with aortic incompetence and aneurysm of the ascending aorta. *J Thorac Cardiovasc Surg* 1992; 103: 617-622.
10. Yacoub M, Fagan A, Stassano P, Radley-Smith R: Results of valve conserving operations for aortic regurgitation [abstract]. *Circulation* 1983; 68(Suppl): III321.
11. Calafiore AM, Teodori G, Mezzetti A, et al: Intermittent antegrade warm blood cardioplegia. *Ann Thorac Surg* 1995; 59: 398-402.
12. Yacoub MH, Gehle P, Chandrasekaran V, Birks EJ, Child A, Radley-Smith R: Late results of a valve-preserving operation in patients with aneurysms of the ascending aorta and root. *J Thorac Cardiovasc Surg* 1998; 115: 1080-1090.
13. De Oliveira NC, David TE, Ivanov J, et al: Results of surgery for aortic root aneurysm in patients with Marfan syndrome. *J Thorac Cardiovasc Surg*. 2003; 125: 789-796.
14. Schafers H-J, Fries R, Langer F, Nikoloudakis N, Graeter T, Grundmann U: Valve-preserving replacement of the ascending aorta: remodeling versus reimplantation. *J Thorac Cardiovasc Surg* 1998; 116: 990-996.
15. Valve-sparing aortic root replacement in patients with the Marfan syndrome: D. Graig Miller, MD *JTCVS* April 2003 No 4.
16. Robicsek F: Leonardo da Vinci and the sinuses of Valsalva. *Ann Thorac Surg* 1991; 52: 328-335.
17. Zehr KJ: Valve preserving aortic root reconstruction [Letter]. *J Thorac Cardiovasc Surg* 2001; 121: 1220-1221.