Original Research

The Use of Rotational Atherectomy and Drug-Eluting Stents in the Treatment of Heavily Calcified Coronary Lesions

Petros Dardas, Nikolaos Mezilis, Vlasis Ninios, Dimitrios Tsikaderis, Efstratios K. Theofilogiannakos, Stelios Lampropoulos

Department of Cardiology, St. Luke's Hospital, Thessaloniki, Greece

Key words:
Heavily calcified coronary artery lesions, rotational atherectomy, drug-eluting stents.

Introduction: The treatment of calcified coronary artery lesions is a challenge for percutaneous angioplasty. Rotational atherectomy is an established technique for the effective modification of these lesions prior to conventional angioplasty and stent implantation. Drug-eluting stents (DES) have shown encouraging results in complex lesions and high-risk patients.

Methods: This retrospective study investigated the immediate and long-term prognosis after treatment with rotational atherectomy (RotA) and DES implantation in 184 patients with calcified coronary artery lesions.

Results: During follow up (mean 49 months), 7 patients died (1 from a non-cardiac cause) and the incidence of major adverse cardiac events was 14.85%. Only 4.15% of patients underwent a new angioplasty procedure.

Conclusions: The combination of RotA and DES in calcified coronary artery lesions has a very good angiographic result and a satisfactory clinical outcome.

Manuscript received:
March 3, 2011;
Accepted:
July 17, 2011.

Address:
Petros Dardas

Department of Cardiology
St. Luke's Hospital
552 36 Panorama
Thessaloniki, Greece
e-mail: pdardas@otenet.gr

The treatment of calcified coronary artery lesions (CCL) is a serious challenge in interventional cardiology. CCL have been associated with high rates of restenosis and target lesion revascularisation (TLR).[1] Balloon angioplasty and stent implantation are often infeasible in heavily calcified lesions. Lesion calcification, in combination with the geometry of the vessel, impedes the approach to the lesion with the balloon and makes successful stent deployment and implantation technically difficult. These lesions require special modification, using devices such as those used for rotational atherectomy (RotA). The rates of restenosis and TLR remain high.[2]

The use of bare-metal stents (BMS) led to a reduction in restenosis rate compared to direct balloon angioplasty, in both calcified and non-calcified lesions. Nevertheless, this approach continues to have high rates of restenosis and need for TLR.[3] DES were introduced in the market in order to reduce the rate of restenosis and reocclusion of the lesions,[4] and almost all studies have concluded that the use of DES in patients with stable coronary artery disease is associated with a significant reduction in restenosis of both calcified and non-calcified lesions.[5] However, the placement and deployment of DES in coronary vessels with a complex anatomy and geometry, and in eccentric and extremely calcified lesions, continues to be a challenge from the technical point of view.

RotA is one of the techniques that have been used for the modification of complex and calcified lesions prior to stent implantation. The first studies to examine the combination of RotA + DES in the treatment of CCL, though few in number, showed encouraging long-term results.[6] The combination of RotA + DES

in stenoses of this kind showed an additional benefit for long-term prognosis compared to DES implantation alone.[7,8]

This study was designed to assess the immediate and long-term results in patients with CCL who underwent RotA and DES implantation.

Methods

This study represents a retrospective analysis of 184 consecutive patients with CCL who underwent RotA + DES from January 2002 to May 2011 in St Luke's hospital, Thessaloniki, Greece. The characterisation of a lesion as CCL was based on quantitative angiographic criteria assessed independently by two interventional cardiologists. Five subgroups of patients were identified according to lesion morphology: 1) lesions with localised calcification, 2) diffuse-calcified lesions, 3) calcified bifurcations, 4) ostial lesions, and 5) chronic total occlusions with extensive calcification. All patients gave written informed consent. Four types of DES were used: Cypher® stent (Cordis, Miami Lakes FA, USA), Taxus® stent (Boston Scientific, Natick MA, USA), Endeavor® stent (Medronic, Minneapolis MN, USA) and Xience V® stent (Abbott Park IL, USA).

Demographic and clinical data (Table 1) were collected for all patients and all the angioplasty data were recorded (number of vessels, number of lesions; Figure 1). The pre-angioplasty data included age, sex, medication, classification of angina (Canadian Cardiovascular Society), and patients' left ventricular function. The follow-up data included any cause of death, stroke, myocardial infarction, angina reoccurrence, new diseases, cases of TLR, target vessel revascularisation (TVR), and duration of dual antiplatelet medication. Major adverse cardiac events (MACE) included death, myocardial infarction, stroke, TLR and TVR.

In all cases RotA was performed using a special Rotablator® device (Boston-Scientific, Natick MA, USA) A 0.009" Rotawire guidewire was used to pass across the lesion. In most cases a RotA technique with 2 burrs was chosen in order to reduce the incidence of the no-reflow phenomenon. The smaller burr (usually 1.25 mm) was used first, followed by a larger burr based on the size of the vessel, aiming at a burr/vessel ratio that did not exceed 0.6-0.7. During activation of the RotA device, a heparinised normal saline solution with verapamil and nitroglycerine was administered locally, with a view to preventing thrombus formation and vascular spasm and avoiding the no-reflow phenomenon. The burr was introduced through a guiding catheter using a dyna-glide technique so as to reduce friction, and the atherectomy was performed using the "pecking" technique with an initial atherectomy speed of 135-140,000 rpm. Our aim was to confine the use of the RotA device strictly to the predetermined atherectomy region. The duration of RotA application was 15-20 s, with immediate cessation if the revolutions dropped by >5000 rpm. Following successful modification of the plaque, angioplasty was performed with a low-pressure balloon so as to avoid dissection of the vessel, and a DES was implanted according to the vessel's size.

In two cases of high risk RotA in patients with previous coronary artery bypass grafting and valve operation, cardiopulmonary support with a portable extracorporeal membrane oxygenator was used during the high risk procedures and in the immediate post-procedural recovery period.[9]

Angioplasty was completed in all cases and after stent implantation another balloon dilatation was performed at high pressure. All patients were put on dual antiplatelet medication (100 mg salicylic acid and 75 mg clopidogrel daily), as well as anti-anginal and lipid-lowering drugs.

Table 1. Demographic and clinical data.

Age (years)	67.00 ± 9.20
Men (%)	70.65
Hypertension (%)	80.98
Diabetes mellitus (%)	26.23
Angina (%)	87.50
Acute myocardial infarction (%)	4.35%
Ejection fraction <40%	32

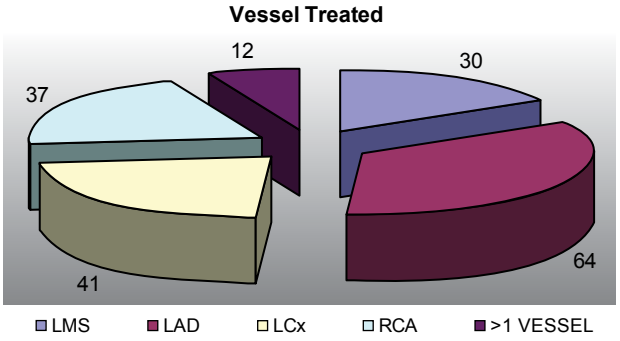

Figure 1. The target vessel treated with the combination of rotational atherectomy and drug-eluting stent. LMS – left main coronary artery; LAD – anterior descending branch; LCx – left circumflex; RCA right coronary artery.

Statistical analysis

Continuous variables are expressed as mean ± standard deviation. Correlations and comparisons between groups were made using Student's unpaired t-test. P-values <0.05 were considered statistically significant.

Results

The study population included 184 patients (130 men, 54 women, mean age 67 ± 9.2 years). Of these, 149 (80.98%) had a history of hypertension, while 49 (26.63%) were diabetics (Table 1). The indication for angioplasty was stable angina in 176 (95.65%) and infarction in 8 (4.35%) patients. The coronary vessels in which RotA + DES were used are shown in Figure 1. Effective stent deployment was achieved with high pressure (18-24 atm) balloon dilatation after stent deployment in all cases.[10] The CCL morphologies encountered (Figure 2) were: 86 (46.74%) diffusely calcified lesions, 38 (20.65%) calcified bifurcation lesions, 29 (15.76%) ostial lesions (Figure 3), 25 (13.59%) lesions with localised calcification (Figures 4 & 5), and 6 (3.26%) chronic occlusions with calcification (Figure 6). Patients with lesions in the left main coronary artery (LMS) that were treated with RotA + DES were 30 (25 with previous coronary artery bypass graft surgery). In 25 cases (83.33%) the LMS was protected, while there were 5 patients with an unprotected LMS, where there was usually a coexisting ostial lesion in the anterior descending or circumflex artery. In 179 (97.28%) patients RotA and DES were performed successfully, a rate that agrees with previous studies.[8] In 5 patients stent placement was unsuccessful, mainly because of vessel tortuosity. In these cases RotA was followed by successful balloon angioplasty.

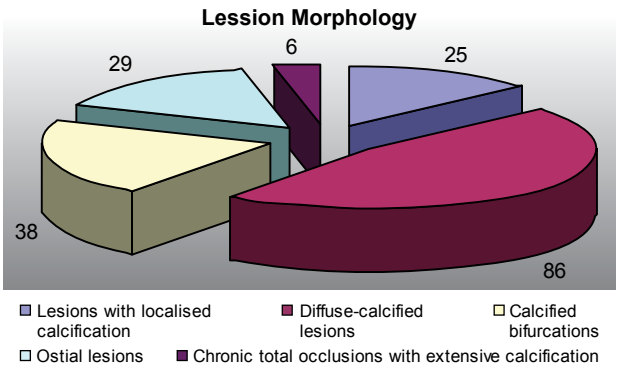

Figure 2. Morphology of target lesions treated with the combination of RotA + DES.

The patients were followed up based on clinical criteria and the mean follow-up time was 49 months (range 12-92 months). Fifty-five patients (29.89%) underwent a new coronary angiography. TVR was necessary in 3.25% and TLR in 2.80% of patients (Table 2). These patients had either diffuse calcification or ostial lesions. Seven patients died during follow up (1 from a non-cardiac cause) and the incidence of MACE was 14.85% (Table 2). None of the latter events was directly related to the angioplasty and the in-hospital mortality was zero. Twenty (10.87%) patients stopped taking clopidogrel a mean of 39 months after the angioplasty.

Discussion

The technique of RotA was invented at the start of the 1980s by David Auth and has been used during angioplasty for more than 20 years.[11] The method is most effective in the modification of calcified plaques, facilitating stent placement during angioplasty. The treatment of CCL (as opposed to non-calcified lesions) with angioplasty has been associated with a lower success rate and a higher incidence of complications.[12] The geometry and inflexibility of CCL often does not permit successful approach and correct stent deployment.[13] In addition, balloon dilatation and stent deployment in CCL carry a higher risk of dissection and rupture.

RotA devices use a rotating brass burr that pulverises a portion of the fibrous, calcified, inelastic plaque, modifies the plaque compliance, and leaves a smooth, non-endothelialised surface with intact media.[14,15] RotA is based on the principle of differential atherectomy, namely selective atherectomy of the fibrous and calcified plaque.[11] Successful RotA results in the creation of a smooth vessel lumen, suitable for the successful performance of balloon angioplasty and stenting at the site of the lesion.[16]

Nevertheless, RotA followed by balloon angioplasty without stenting does not have better results than direct balloon angioplasty, leading to high rates of restenosis and a need for TLR in up to 40% of cases.[17] Furthermore, the same discouraging results from RotA + balloon angioplasty compared to balloon angioplasty alone also apply to the prevention of restenosis in the small coronary vessels.[18] The implantation of BMS after RotA in CCL has a high success rate, with an acceptable incidence of complications and a clearly lower incidence of angiographic restenosis compared to plain angioplasty, but the re-

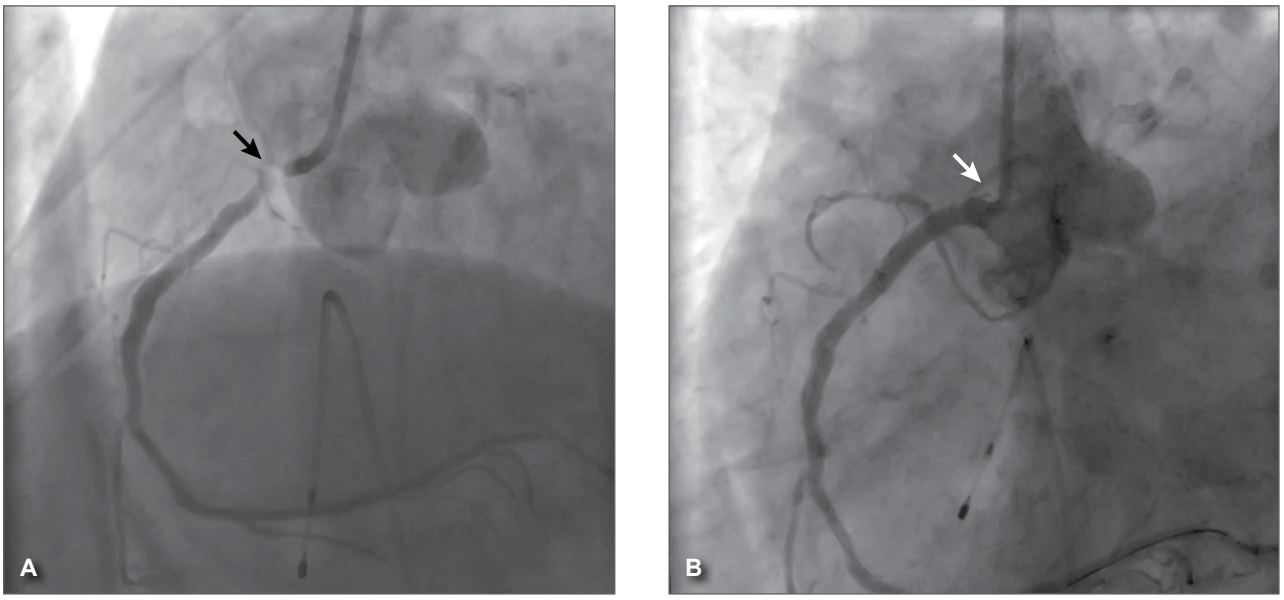

Figure 3. A. Calcified ostial lesion in the right coronary artery (black arrow). B. Restoration of vessel patency with the combination of rotational atherectomy and drug-eluting stent (white arrow).

Table 2. Percentages of major adverse cardiovascular events (MACE).

Death	3.80
Myocardial infarction	3.20
Stroke	1.80
Target vessel revascularisation	3.25
Target lesion revascularisation	2.80
Total MACE	14.85

stenosis rate and need for TLR remain high, at 22.5% according to one previous study.[19]

Compared to BMS, DES reduce neointimal hyperplasia and, according to large randomised trials, are safe and effective in the treatment of coronary lesions in patients with stable angina.[20,21] The implantation of DES in CCL has not been widely studied and presents a technical challenge because of the diffi-

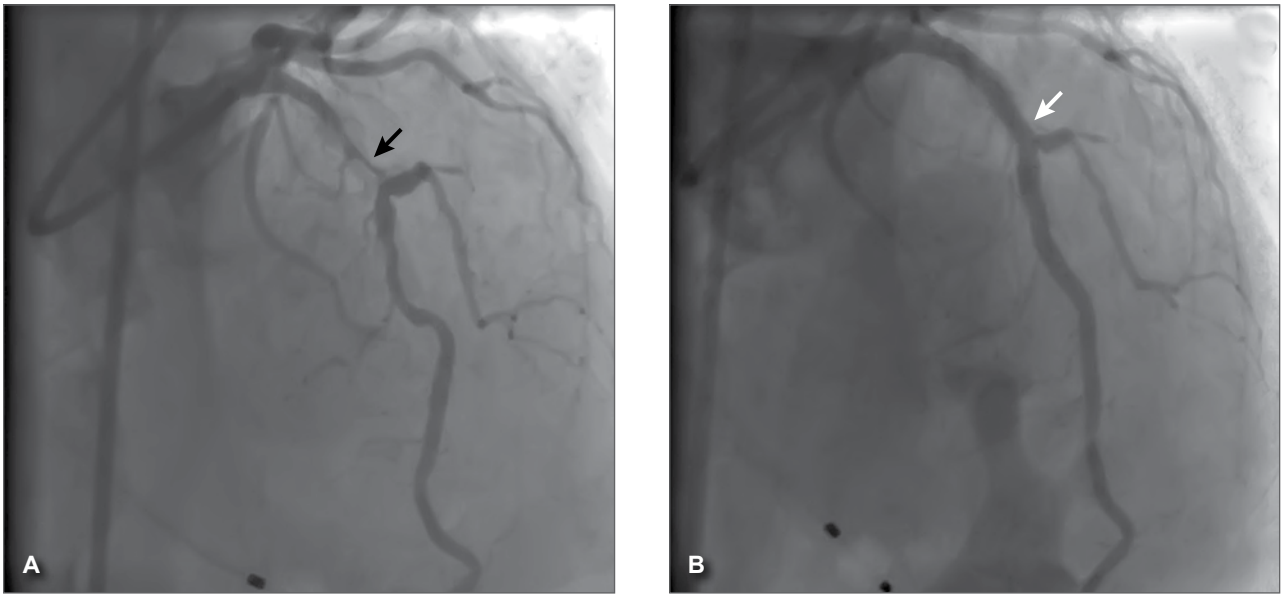

Figure 4. A. Localised calcified longitudinal lesion of the left anterior descending artery before the origin of the first diagonal branch (black arrow). B. Restoration of vessel patency with the combination of rotational atherectomy and drug-eluting stent (white arrow).

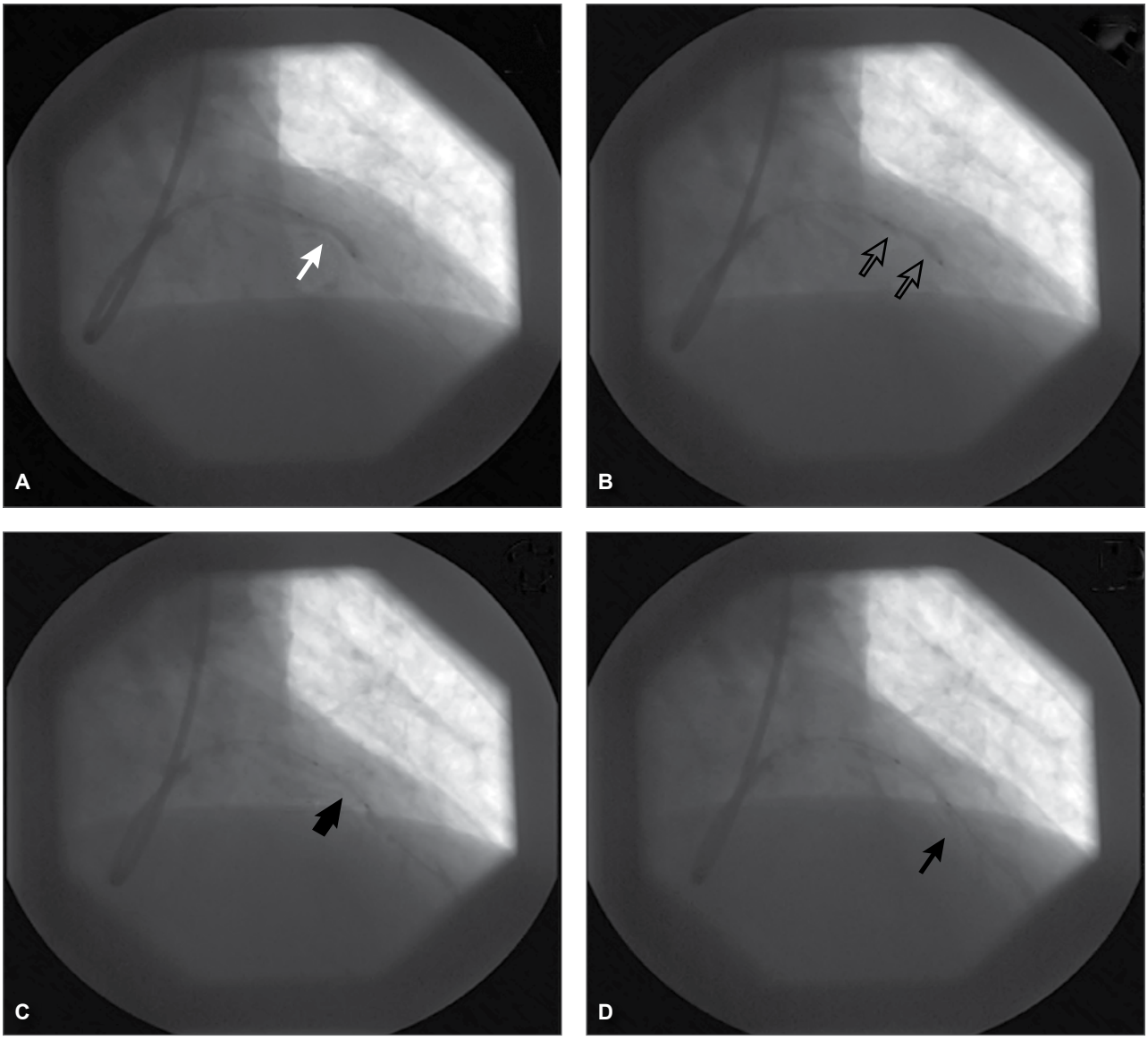

Figure 5. The lesion in Figure 4 had previously been treated unsuccessfully using direct balloon dilatation without rotational atherectomy of the calcified plaque. A. Attempt to deploy the balloon (white arrow). B. Incomplete deployment of the start and (better) the end of the balloon (open arrows). C. Rupture of the angioplasty balloon (thick black arrow). D. The result of the rupture is the characteristic escape of contrast medium distal to the balloon (thin black arrow).

culty of stent implantation and deployment. Calcification of the lesion is already known to have a negative impact on stent deployment.[22] Wear of the stent's polymer coating during forceful deployment and unsatisfactory drug elution because of extreme calcification of the lesion are the main reasons for the unsuccessful deployment and implantation of stents in CCL. Indeed, Kawaguchi et al[23] showed that the rates of MACE and the need for TLR were significantly higher in patients with calcified as opposed to noncalcified lesions who were treated with DES implantation. The same authors proposed the supplementary use of RotA before DES implantation in lesions with heavy calcification. Khattab et al[24] showed that the RotA + DES approach had better clinical and angiographic results over a 9-month follow up compared to RotA + BMS in the treatment of patients with CCL. Rao et al[25] compared the results from patients treated with RotA + BMS with those from a group treated with RotA + DES and another group treated with DES without RotA and showed that the use of DES reduced the incidence of MACE in pa-

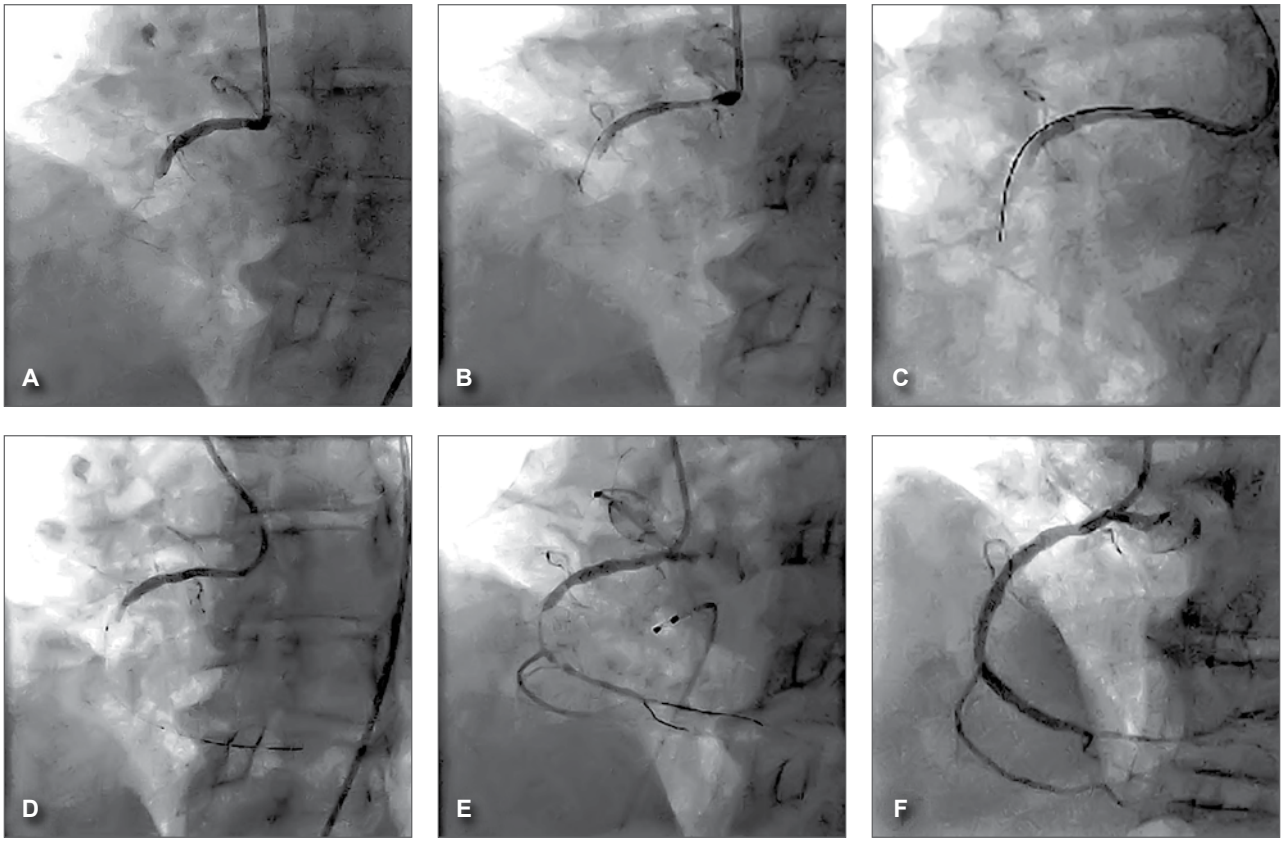

Figure 6. Chronic total occlusion of a right coronary artery. A. Guide wire insertion. B. Three different catheters: JR4, AL1, H-STICK. C. Inability to cross chronic total occlusion with eight different balloons (diameters from 1.5-0.85 mm). D. Rotawire crosses the lesion. E. Rotational atherectomy with 1.25 mm burr. F. Deployment of drug-eluting stent.

tients who underwent RotA, mainly because of a significant reduction in the need for TLR. Clavijo et al[26] compared two groups of patients with CCL who were treated with DES, where RotA was necessary in the first group but not in the second. There was no significant difference between the groups as regards in-hospital complications or clinical outcomes. Also, a previous study[8] confirmed that the combination of RotA + DES had excellent results in the treatment of CCL, with very few in-hospital complications and a very low rate of MACE. A limitation and disadvantage of this latter study was the small number of patients (just 50). A previous study of ours, the results of which are extended by the present study, showed that the therapeutic strategy of RotA + DES was effective in treating CCL as regards both the clinical outcome and the angiographic result.[27] The rate of death and MACE in the present study are slightly higher than in our previous sudy[27] (3.8 vs. 2.6 and 14.84 vs. 11.3). This is explained by the longer mean follow up of this study (49 vs. 36 months).

The present study shows that the RotA + DES strategy is a feasible and effective way of treating CCL. The mortality and MACE rates were very low (3.80% and 14.85%, respectively) over a mean follow up of 49 months. No complications related to the angioplasty were recorded, while in previous studies the incidence of such complications was from 4% to 7%.[8,26] A 2-burr technique was used with a view to limiting the occurrence of the no-reflow phenomenon. Initially, a small burr was used (1.25 mm), followed by a larger burr depending on the size of the vessel. Whether this gradual approach contributed to limiting the immediate complications and to the low rate of stent thrombosis will need further investigation. Recently, Furuichi et al[6] reported a slightly higher rate of MACE (15.8%) and mortality (4.2%). However, a direct comparison of our results with theirs is not feasible, since they did not describe the technique they used (i.e. burrs at one or more stages).

Schwartz et al[28] compared the angiographic and procedural success rates of three therapeutic strate-

gies in patients with CCL: RotA + only balloon angioplasty, RotA + BMS, and RotA + DES. From an unadjusted analysis, the procedural success appeared to be high with subsequent stent placement (DES or BMS) versus RotA alone (96.4% for DES versus 95% for BMS versus 63% for no stent). However, 1 patient in 4 was not a candidate for stent placement—because the reference vessel diameter was <2.25 or >3.75 mm, the DES could not be delivered, or there was a reason to avoid clopidogrel therapy—and the lower procedural success rate in this population should be considered prior to embarking on RotA.[28] However, the rate of unsuccessful stent placement reported by the above investigators was much higher than in our study, as well as in previous studies.[8] Another recent study[29] confirmed the safety and effectiveness of the Rota + DES strategy in the treatment of CCL, with good long-term clinical outcomes. Although the radial approach was used in 37.3% of cases, the procedure was successful in 97% of cases; this rate of success is similar to ours and proves that the rate of procedural success reported by Schwartz et al[28] was unacceptably low.

Of the 184 patients who were treated with RotA + DES in our study, 6 (3.26%) had chronic total occlusions (CTO) with calcification. Although this is a relatively small number, the successful and uncomplicated result of the RotA + DES strategy in these cases may be an indication that RotA is an alternative technique to treat CTO. According to Pagnotta et al, in approximately 7% of all CTOs that are successfully crossed with a guidewire, it is not possible to cross the lesion with a balloon catheter. RotA is a safe and effective technique for overcoming this frustrating situation.[30]

The main limitation of the present study is the absence of a full angiographic follow up. However, the use of the RotA + DES therapeutic strategy appears to be a safe technique on the basis of clinical criteria. Another disadvantage of this study is its retrospective nature and the lack of a control group.

Conclusions

The combination of RotA + DES is an integrated, effective and safe method of treating CCL. The wide use of DES may cause a renaissance of RotA and its return to daily use in the catheterisation laboratory, after its decline a decade ago when it failed to show better long-term results after angioplasty. In the future, randomised, blind studies will be needed to confirm our results.

References

1. Moses JW, Carlier S, Moussa I. Lesion preparation prior to stenting. Rev Cardiovasc Med. 2005; 5 Suppl 2: S16-21.
2. Warth DC, Leon MB, O'Neill W, Zacca N, Polissar NL, Buchbinder M. Rotational atherectomy multicenter registry: acute results, complications and 6-month angiographic follow-up in 709 patients. J Am Coll Cardiol. 1994; 24: 641-648.
3. Fischman DL, Leon MB, Baim DS, et al. Stent Restenosis Study Investigators. A randomized comparison of coronary-stent placement and balloon angioplasty in the treatment of coronary artery disease. N Engl J Med. 1994; 25: 331: 496-501.
4. Stathopoulos I, Jimenez M, Panagopoulos G, et al. The decline in PCI complication rate: 2003-2006 versus 1999-2002. Hellenic J Cardiol. 2009: 50: 379-387.
5. Stone GW, Ellis SG, Cox DA, et al. TAXUS-IV Investigators. A polymer-based, paclitaxel-eluting stent in patients with coronary artery disease. N Engl J Med. 2004; 350: 221-231.
6. Furuichi S, Sangiorgi GM, Godino C, et al. Rotational atherectomy followed by drug-eluting stent implantation in calcified coronary lesions. EuroIntervention. 2009; 5: 370-374.
7. Khattab AA, Otto A, Hochadel M, Toelg R, Geist V, Richardt G. Drug-eluting stents versus bare metal stents following rotational atherectomy for heavily calcified coronary lesions: late angiographic and clinical follow-up results. J Interv Cardiol. 2007; 20: 100-106.
8. García de Lara J, Pinar E, Ramón Gimeno J, et al. Percutaneous coronary intervention in heavily calcified lesions using rotational atherectomy and paclitaxel-eluting stents: outcomes at one year. Rev Esp Cardiol. 2010; 63: 107-110.
9. Dardas P, Mezilis N, Ninios V, et al. ECMO-assisted high-risk rotational atherectomy of heavily calcified coronary arteries. Herz 2011 (In press).
10. Romagnoli E, Sangiorgi GM, Cosgrave J, Guillet E, Colombo A. Drug-eluting stenting: the case for post-dilation. JACC Cardiovasc Interv. 2008; 1: 22-31.
11. Reisman M. Technique and strategy of rotational atherectomy. Cathet Cardiovasc Diagn. 1996; Suppl 3: 2-14.
12. Wilensky RL, Selzer F, Johnston J, et al. Relation of percutaneous coronary intervention of complex lesions to clinical outcomes (from the NHLBI Dynamic Registry). Am J Cardiol. 2002; 90: 216-221.
13. Hoffmann R, Mintz GS, Popma JJ, et al. Treatment of calcified coronary lesions with Palmaz-Schatz stents. An intravascular ultrasound study. Eur Heart J. 1998; 19: 1224-1231.
14. Mintz GS, Potkin BN, Keren G, et al. Intravascular ultrasound evaluation of the effect of rotational atherectomy in obstructive atherosclerotic coronary artery disease. Circulation. 1992; 86: 1383-1393.
15. Kovach JA, Mintz GS, Pichard AD, et al. Sequential intravascular ultrasound characterization of the mechanisms of rotational atherectomy and adjunct balloon angioplasty. J Am Coll Cardiol. 1993; 22: 1024-1032.
16. Ellis SG, Popma JJ, Buchbinder M, et al. Relation of clinical presentation, stenosis morphology, and operator technique to the procedural results of rotational atherectomy and rotational atherectomy-facilitated angioplasty. Circulation. 1994; 89: 882-892.
17. Reifart N, Vandormael M, Krajcar M, et al. Randomized comparison of angioplasty of complex coronary lesions at a single center. Excimer Laser, Rotational Atherectomy, and Balloon Angioplasty Comparison (ERBAC) Study. Circulation. 1997; 96: 91-98.

18. Mauri L, Reisman M, Buchbinder M, et al. Comparison of rotational atherectomy with conventional balloon angioplasty in the prevention of restenosis of small coronary arteries: results of the Dilatation vs Ablation Revascularization Trial Targeting Restenosis (DART). Am Heart J. 2003; 145: 847-854.
19. Moussa I, Di Mario C, Moses J, et al. Coronary stenting after rotational atherectomy in calcified and complex lesions. Angiographic and clinical follow-up results. Circulation. 1997; 96: 128-136.
20. Stone GW, Moses JW, Ellis SG, et al. Safety and efficacy of sirolimus- and paclitaxel-eluting coronary stents. N Engl J Med. 2007; 356: 998-1008.
21. Mauri L, Hsieh WH, Massaro JM, Ho KKL, D'Agostino R, Cutlip DE. Stent thrombosis in randomized clinical trials of drug-eluting stents. N Engl J Med. 2007; 356: 1020-1029.
22. MacIsaac AI, Bass TA, Buchbinder M, et al. High speed rotational atherectomy: outcome in calcified and noncalcified coronary artery lesions. J Am Coll Cardiol. 1995; 26: 731-736.
23. Kawaguchi R, Tsurugaya H, Hoshizaki H, Toyama T, Oshima S, Taniguchi K. Impact of lesion calcification on clinical and angiographic outcome after sirolimus-eluting stent implantation in real-world patients. Cardiovasc Revasc Med. 2008; 9: 2-8.
24. Khattab AA, Otto A, Hochadel M, Toelg R, Geist V, Richardt G. Drug-eluting stents versus bare metal stents following rotational atherectomy for heavily calcified coronary lesions: late angiographic and clinical follow-up results. J Interv Cardiol. 2007; 20: 100-106.
25. Rao SV, Honeycutt E, Kandzari D. Clinical outcomes with drug-eluting stents following atheroablation therapies. J Invasive Cardiol. 2006; 18: 393-396.
26. Clavijo LC, Steinberg DH, Torguson R, et al. Sirolimus-eluting stents and calcified coronary lesions: clinical outcomes of patients treated with and without rotational atherectomy. Catheter Cardiovasc Interv. 2006; 68: 873-878.
27. Mezilis N, Dardas P, Ninios V, Tsikaderis D. Rotablation in the drug eluting era: immediate and long-term results from a single center experience. J Interv Cardiol. 2010; 23: 249-253.
28. Schwartz BG, Mayeda GS, Economides C, Kloner RA, Shavelle DM, Burstein S. Rotational atherectomy in the drug-eluting stent era: a single-center experience. J Invasive Cardiol. 2011; 23: 133-139.
29. Benezet J, Díaz de la Llera LS, Cubero JM, Villa M, Fernández-Quero M, Sánchez-González A. Drug-eluting stents following rotational atherectomy for heavily calcified coronary lesions: long-term clinical outcomes. J Invasive Cardiol. 2011; 23: 28-32.
30. Pagnotta P, Briguori C, Mango R, et al. Rotational atherectomy in resistant chronic total occlusions. Catheter Cardiovasc Interv. 2010; 76: 366-371.